

{Libyan International Medical University}  
{ Faculty of Dentistry }

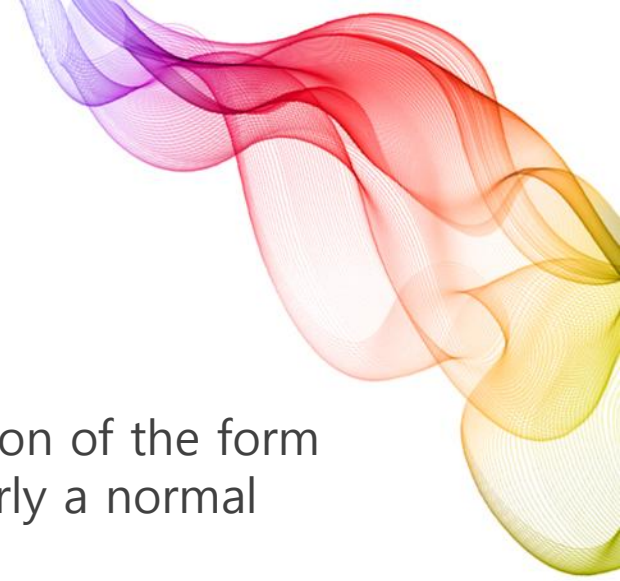

**Comprehensive  
Case  
Presentation**

By: Anas Juma Hadithi – 731  
5<sup>th</sup> Year Dental Student

# Introduction:

**Full mouth rehabilitation** is defined as the restoration of the form and function of the masticatory apparatus to as nearly a normal condition as possible.



# Personal Information:

- **Name:** A.M.A.
- **Sex:** Male.
- **Nationally:** Libyan.
- **Date of birth:** 1990/7/16.
- **Occupation:** Student.
- **Address:** Alsabala.



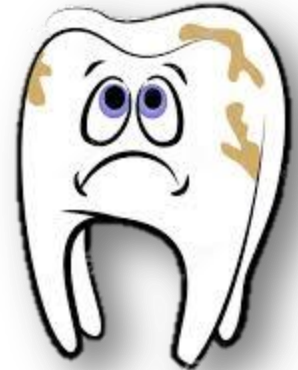- **Chief Complain:**

Patient complaining about missing teeth in the upper left side since 4 years & seeking for replacement.

- **History of Chief Complain:**

He lost his teeth because of Dental Caries & Trauma then they are extracted by the dentist.

He replaced them by RPD since 2013 then it become broken & the patient didn't repair it or made a new replacement.





## **Past & Recurrent Medical History:**

**Medical History:** Rt. Ear moderate mixed hearing loss + congenital atresia of the canal.

**History of hospitalization:** He had been admitted because of suppurative infection of middle ear in the last 2014.

**Medication:** Ciprocin<sup>®</sup> twice daily.


## **Allergic History:**

No history of allergy.

## **Past Dental History:**

Patient not regular to the dental office.

History of Fillings, extractions, scaling. Last visit: 6 months ago without any complications.



### **Oral Hygiene Practice:**

Brushing: irregular with soft tooth brush.

Brushing method: Horizontal and vertical.

Kind of Dentifrice used: Not spastic.

Any other type: Miswak.

### **Social and Family History:**

Single / non smoker/ non alcohol drinker .

There's no hereditary diseases running in the family.



# Clinical Examination:



# Clinical Examination:

- **Extra-Oral Examination:**

No swelling or sinus.

**Lips:** Incompetence.

**Face form:** Ovoid.

**Profile:** Convex.


**Facial symmetry:** Symmetrical.

**TMJ:** No clicking, Not tender, No deviation.

**Skin:** NAD.

**Nick examination:** NAD.

**Lymph nodes:** Right Submandibular LN:  
Palpable, Movable, Not tender.



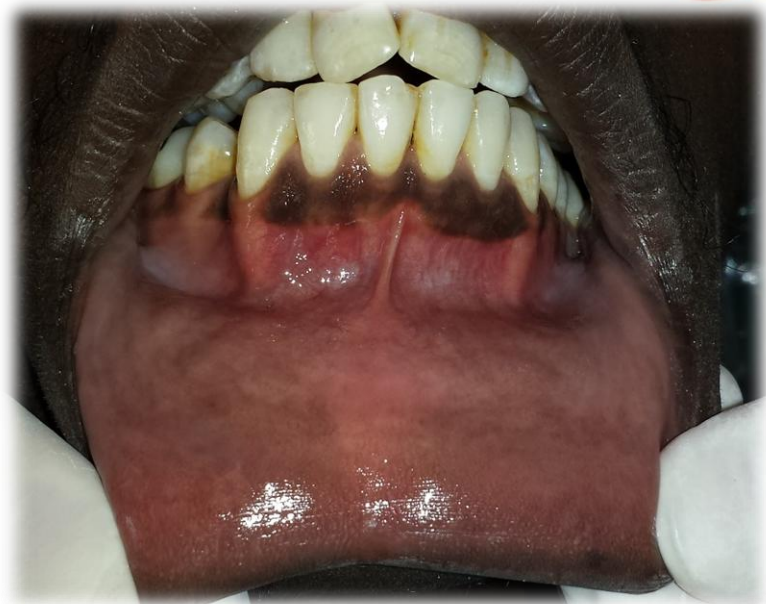
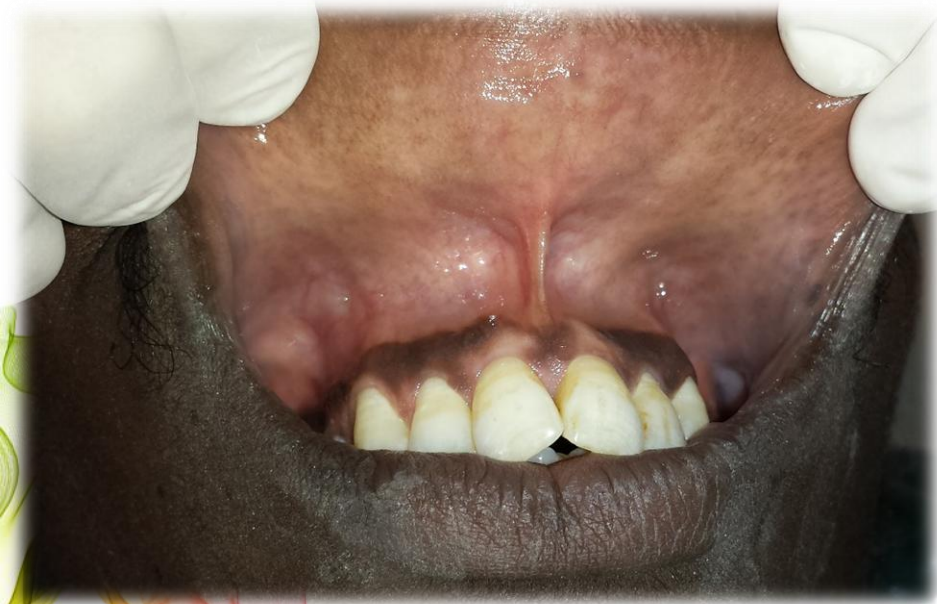
# Clinical Examination:

- Intra-Oral Examination:

- **Soft Tissue Examination:**

- **Labial Mucosa:** Physiological Pigmentation.

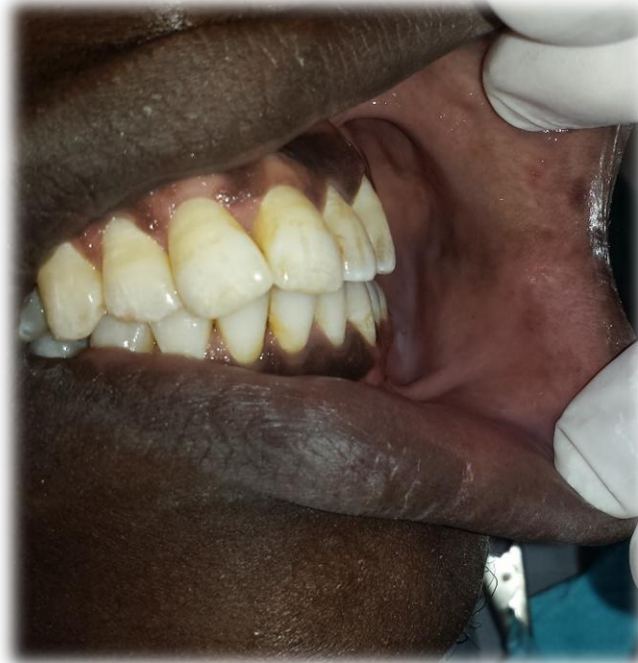
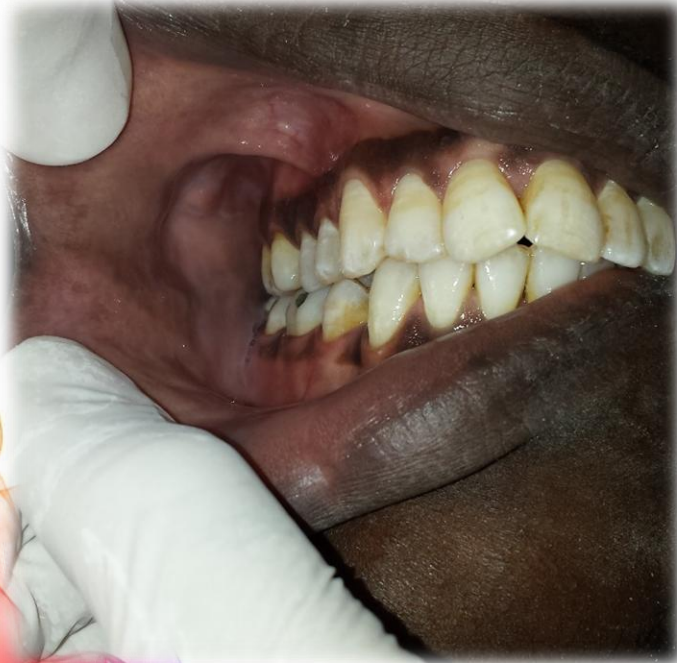
# Clinical Examination:

- **Intra-Oral Examination:**

- **Soft Tissue Examination:**

- **Buccal Mucosa:** Physiological Pigmentation.

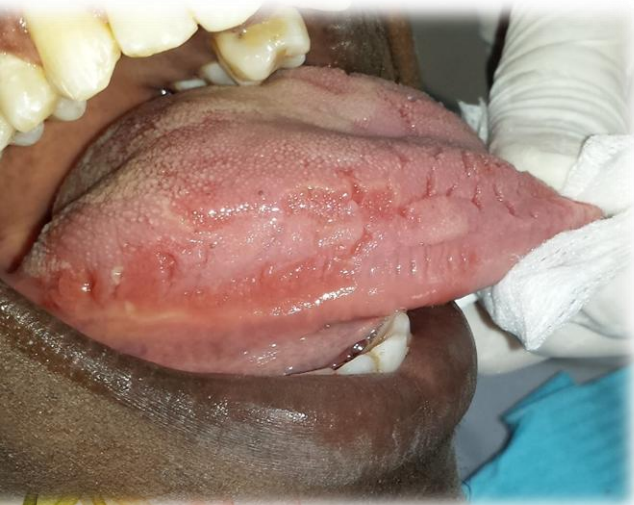

# Clinical Examination:

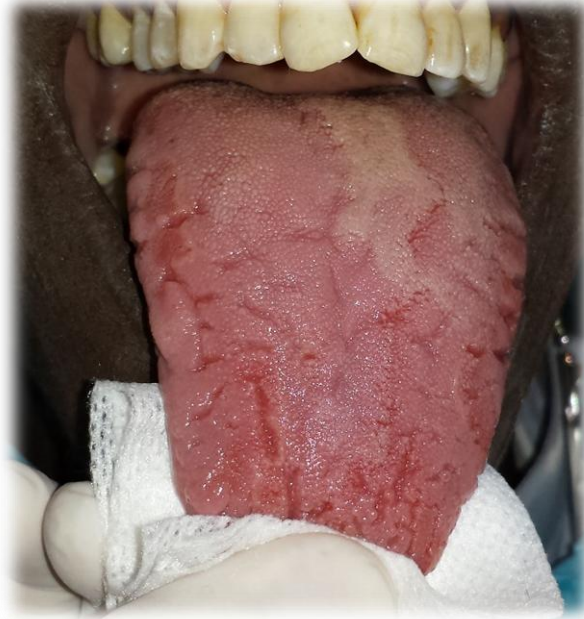- **Intra-Oral Examination:**

**Soft Tissue Examination:** Tongue: Fissured & Geographic Tongue.

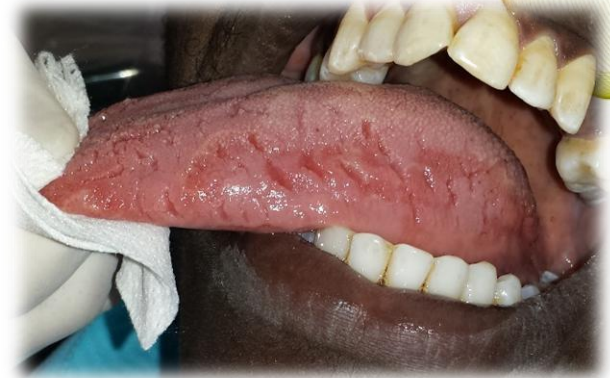Lateral Rt Side.



Dorsum Side.



Lateral Lt Side.

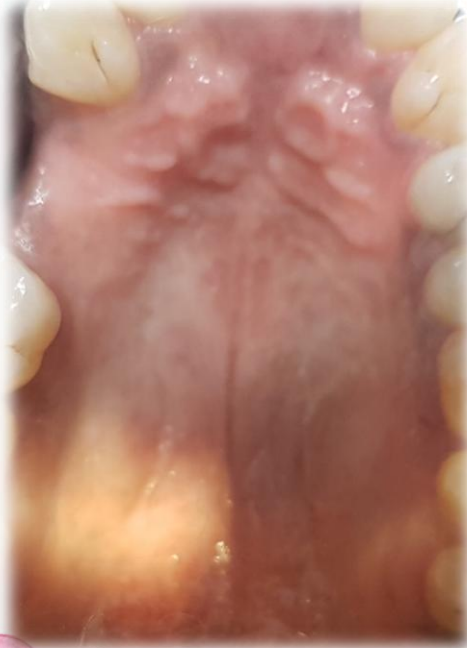

# Clinical Examination:

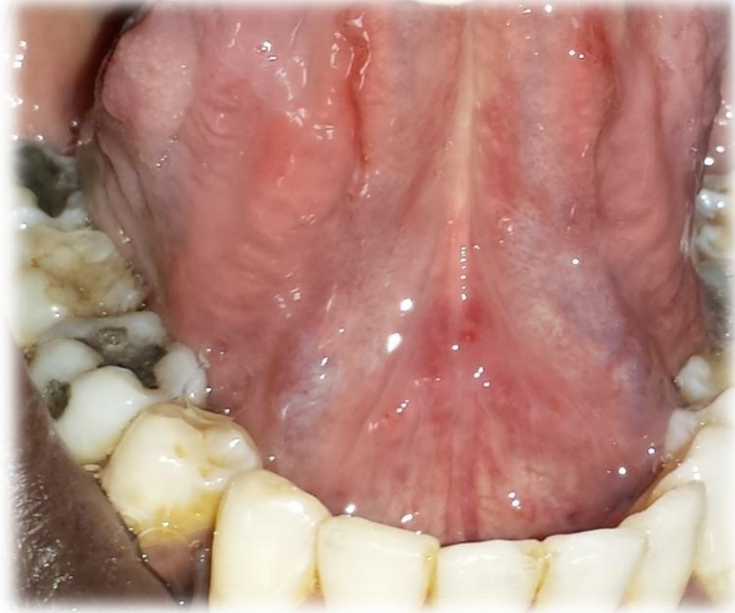- Intra-Oral Examination:

- **Soft Tissue Examination:**

Palate: Normal.



Sub-Lingual Area: Normal.

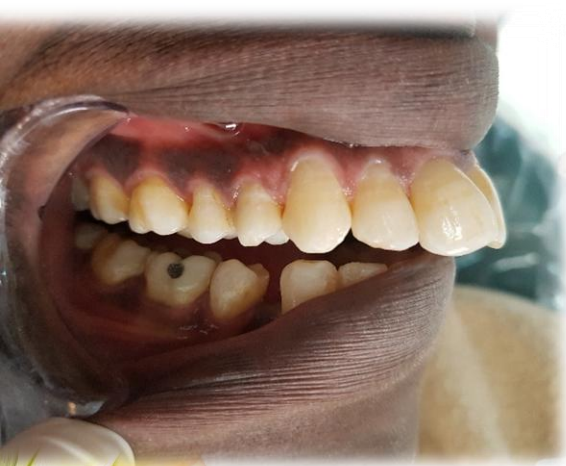

# Clinical Examination:

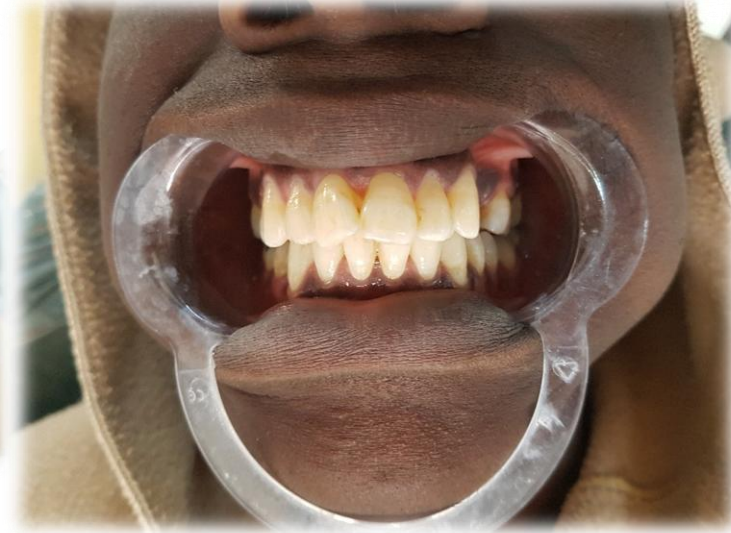- Intra-Oral Examination:

- **Hard Tissue Examination:**

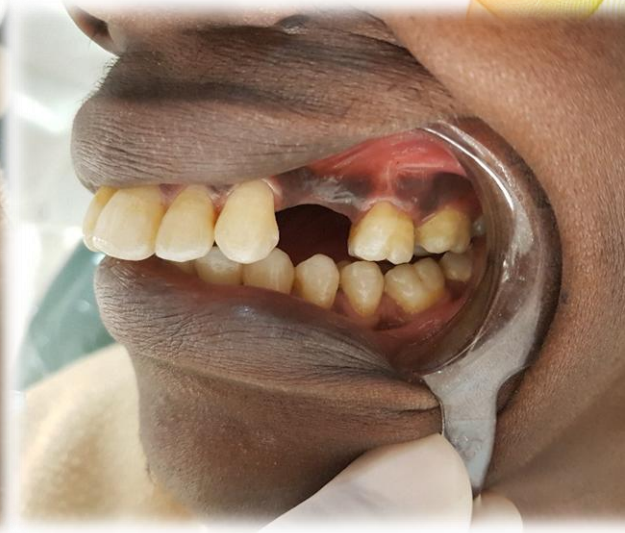Rt Lateral View



Front View



Lf Lateral View

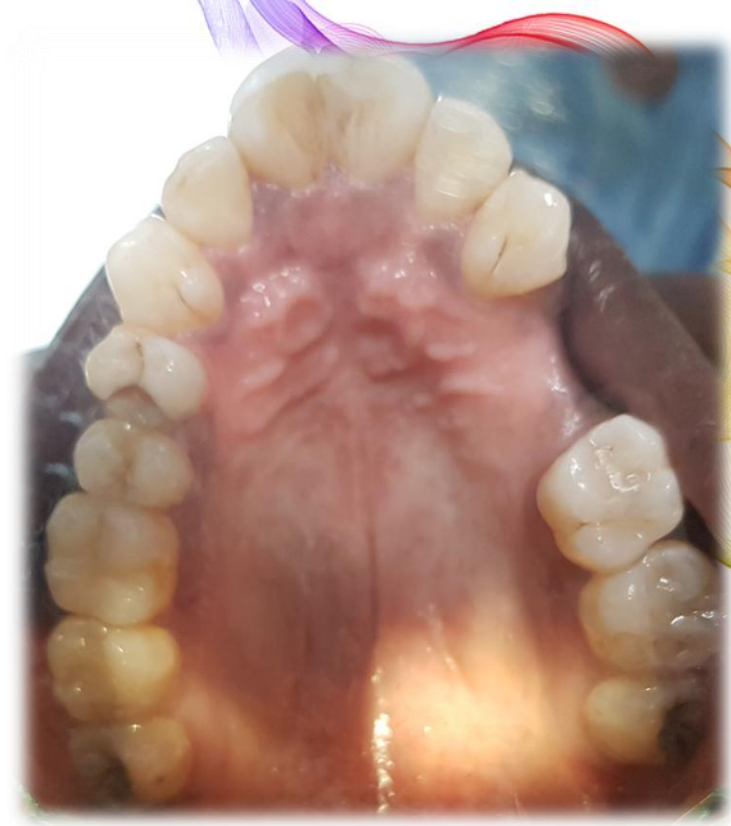

# Clinical Examination:

- Intra-Oral Examination:

- **Hard Tissue Examination:**

Maxillary Arch.



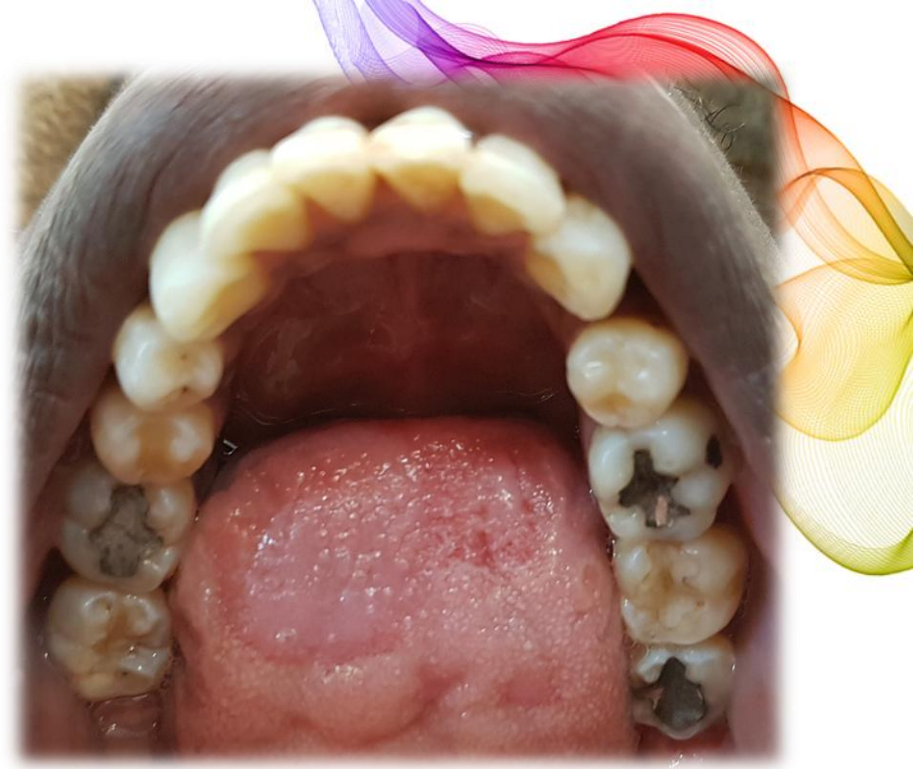8	7	6	5	4	3	2	1	1	2	3	4	5	6	7	8
D	F	F	F	F							M	M	F	F	D

# Clinical Examination:

- Intra-Oral Examination:

- **Hard Tissue Examination:**

- Mandibular Arch.

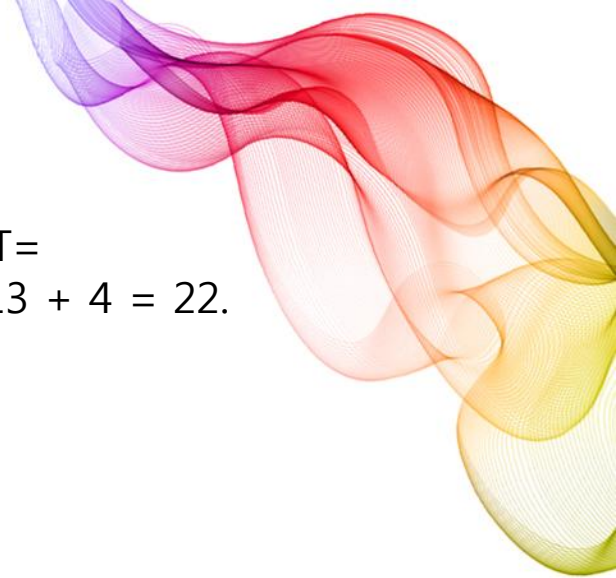


8	7	6	5	4	3	2	1	1	2	3	4	5	6	7	8
F	F	F		M							F/D	F/D	M	F	F

# Dental Status

Teeth Present:	87654321	123 678
	8765 321	12345 78
Carious Teeth:	8	8
		45 8
Restored Teeth:	7654	67
	876	45 78
Missing Teeth:		45
	4	6

- DMFT = 5 + 13 + 4 = 22.





# Gingival status

	Max . Right posterior	Max . Anterior	Max . Left Posterior
Color	Black to pink	Black to pink	Black to pink
Contour	Scalloped with knife edge margin + Blunt IDP.	Scalloped with knife edge margin + Pointed IDP.	Scalloped with knife edge margin + Blunt IDP.
Size	No Enlargement.	No Enlargement.	No Enlargement.
Consistency	Firm to resilient.	Firm to resilient.	Firm to resilient.
Stippling	-	+	-
Position	Apical to CEJ.	At CEJ.	Apical to CEJ.
Bleeding	+	-	+
Exudation	-	-	-

# Gingival status

	Man . Right posterior	Man . Anterior	Man . Left Posterior
Color	Black to pink	Black to pink	Black to pink
Contour	Scalloped with knife edge margin + Pointed IDP.	Scalloped with knife edge margin + Pointed IDP.	Scalloped with Rolled margin + Blunt IDP.
Size	No Enlargement.	No Enlargement.	No Enlargement.
Consistency	Firm to resilient.	Firm to resilient.	Firm to resilient.
Stippling	-	+	+
Position	At CEJ.	At CEJ.	At CEJ.
Bleeding	-	-	-
Exudation	-	-	-



**Adequacy of Attached Gingiva:** Adequate.

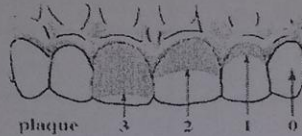
**Fremitus test:** -V.

**Frenal Attachment:** Normal.

# Oral Hygiene

- Oral Hygiene Index Simplified (OHI-S):

16	11	26
1	1	1
2	2	1
46	31	36



16	11	26
0	0	0
0	1	0
46	31	36

•Plaque Index =  $\frac{8}{6} = 1.33$

•Calculus Index =  $\frac{1}{6} = 0.16$

OHI-S =  $1.33 + 0.16 = 1.49$

Good (0-1.2),

Fair (1.3-3),

Poor (3.1-6)

# Dietary Analysis

Patient Name: محمد النور (15) Gender: M/F Date of Birth: 1990/7/16  
 Occupation: طالب Address: الساحة

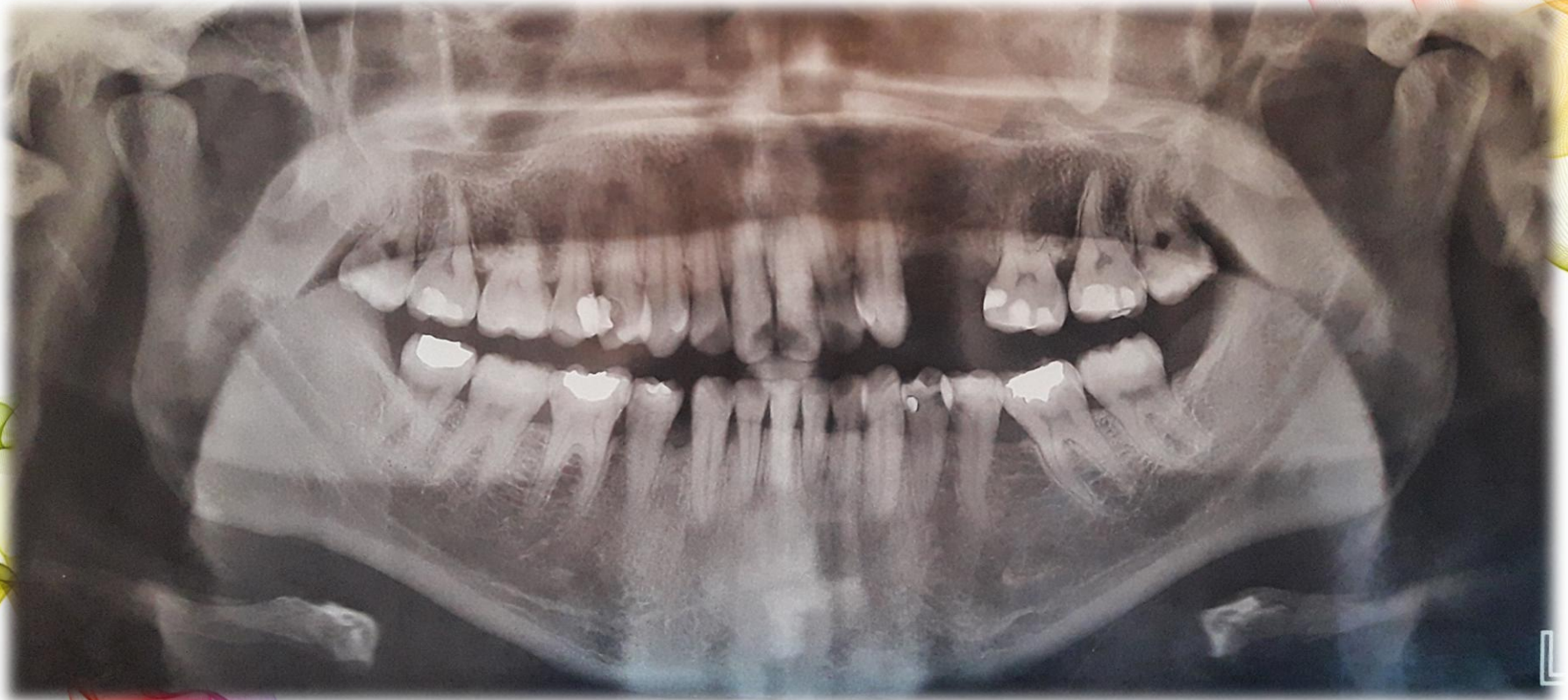نوع الوجبة	المأكولات والمشروبات	الساعة	الأيام
فطور	كوب ماء كوب ماء كوب حليب + شيرة + شيريس ماء	6:45 9:30 11:00 12:30	الجمعة 2024/2/24
غداء	صحنى ، طبخية ، كم ، كوب شاي فستق شيرة	2:40 5:40	
عصية	شاي ضهر زينة سندكاييه + نواشف + بلصين ماء	6:00	
عشاء	شواشف 2 سماندوش ساورما + 2 كوب عصير خارولا	7:14 10:40	
فطور	ماء 1/2 شاي سماندوش ساورما + جبن + كوب حليب بالذ	6:00 7:00 10:35:00	السبت 2024/2/25
عصية	صحن سيري + فستق قهوة كوب ماء فريش الاسنان + عصون كشيرات	12:00 1:30 4:20 7:00	
عشاء	قهوة حج حليب + بسكويت وز كوب ماء فول وشير + عصير لبرتقال	7:40 9:00 10:40 12:00	
فطور	فريش الاسنان شيرة فريش + حليب 2 بريوش	10:30 10:50:00	الأحد 2024/2/26
غداء	2 كوب ماء غذاء ، طبخة حنبل + حنبل + نقر مزرا مالقيد + عصير لسان امان	11:20 3:30 5:22	
عصية	شيرة + حليب + لوز ديوش + كاكوليه صند كورب	7:30 8:10	
عشاء	كوب ماء + عصير صوافة + بسكويت سندكاييه + مزرا بيسترا	9:50 11:30 1:35	

# Investigation



# Investigation

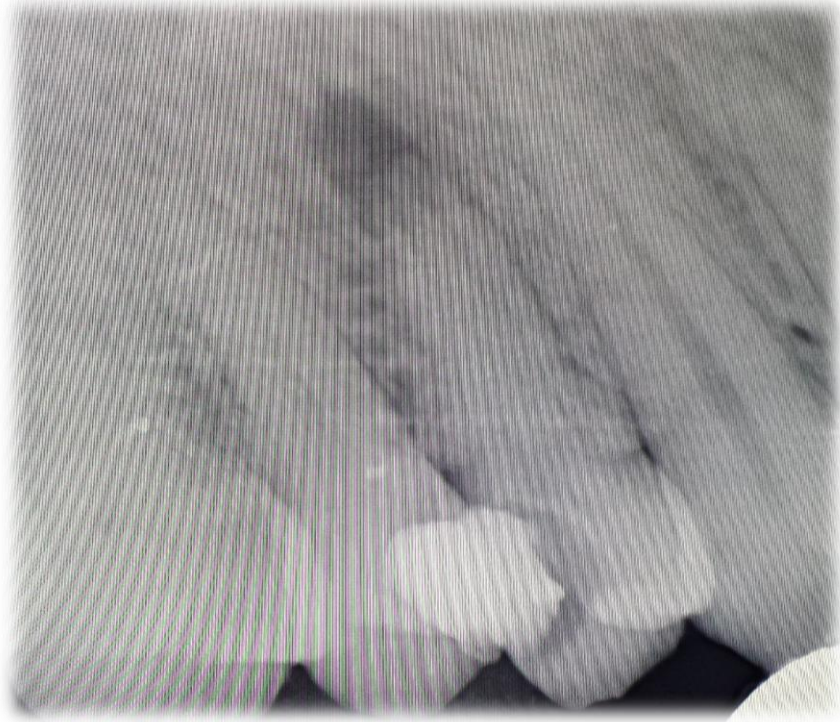
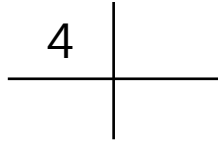
- OPG





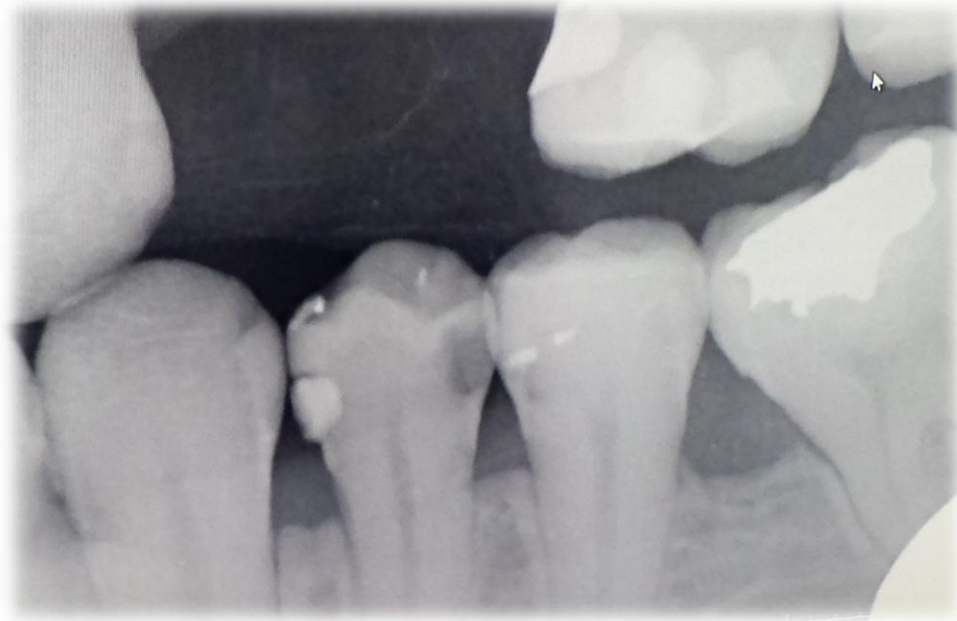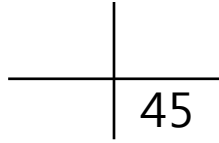
# Investigation

- IOPA



# Investigation

- Bitewing



# Differential Diagnosis

- **Regarding to the Chief Complain:**  
Class III Kennedy Classification in the Upper Arch.

# Final Diagnosis

Class III Kennedy Classification in the Upper Arch.

Localized Mild to Moderate Chronic Periodontitis.

Dental Caries:

- Occlusio-Distal Caries

8	
---	--

- Occlusal Caries

	8
--	---

- Distal Proximal Caries

	4
--	---

- Mesial Proximal Caries

	5
--	---

# Final Diagnosis

Recurrent Dental Caries

5 |  
— |  
4

Necrotic Pulp + Preapical Granuloma.

4 |  
— |

Chronic TFO.



# Treatment Plan

- **Emergency phase:** No need.

- **Phase I**

OHI + Scaling & localized root planning + Occlusal adjustment.

- **Re-evaluation of Phase I**

- **Phase II:** No Need.

- **Phase III**

Restoration & Remake of failed restoration:

RCT:  $\frac{4}{|}$

$\frac{8\ 5}{|} \quad \frac{8}{45}$

Replacement of missing teeth

$\frac{|}{45}$

- **Phase IV**

Follow up & maintenance.

# Inform Consent

الجامعة الليبية الدولية للعلوم الطبية

كلية طب وجراحة الفم والأسنان

موافقة للأذن بالعلاج

أقر أنا / ..... / بطاقة شخصية رقم: ..... 17/15/2013

وبكامل ارادتي أنني أعطي موافقتي اللفظية والكتابية للبدء والاستمرار في العلاج بعيادات كلية طب الأسنان بالجامعة الليبية الدولية للعلوم الطبية والذي يتضمن

.....

وقد تم شرح التشخيص المرضي لحالتي والخيارات المختلفة المتوفرة لمعالجتها والأعراض الجانبية والمخاطر التي قد تصاحب العلاج والمشاكل التي قد تنتج عن عدم العلاج والمدة التقريبية اللازمة لانتهاء منه والتكلفة الإجمالية للعلاج وفقا للرسوم الرمزية المقررة كما تفهم ان هذا العلاج قد تم تنفيذه من قبل طالب أو طبيب امتياز تحت الاشراف المباشر لأعضاء هيئة التدريس بالكلية.

اسم المريض: ..... /

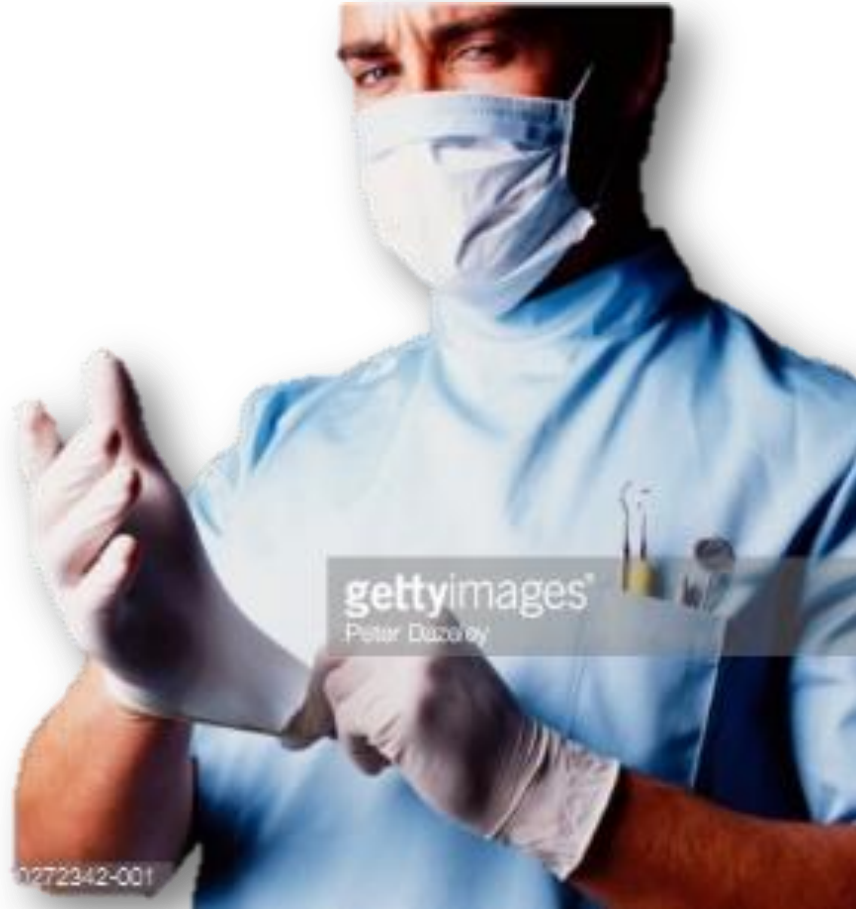توقيع المريض: .....

اسم الطالب أو طبيب الامتياز: ..... - 731

الاستاذ المشرف: .....

التاريخ: ..... 2012

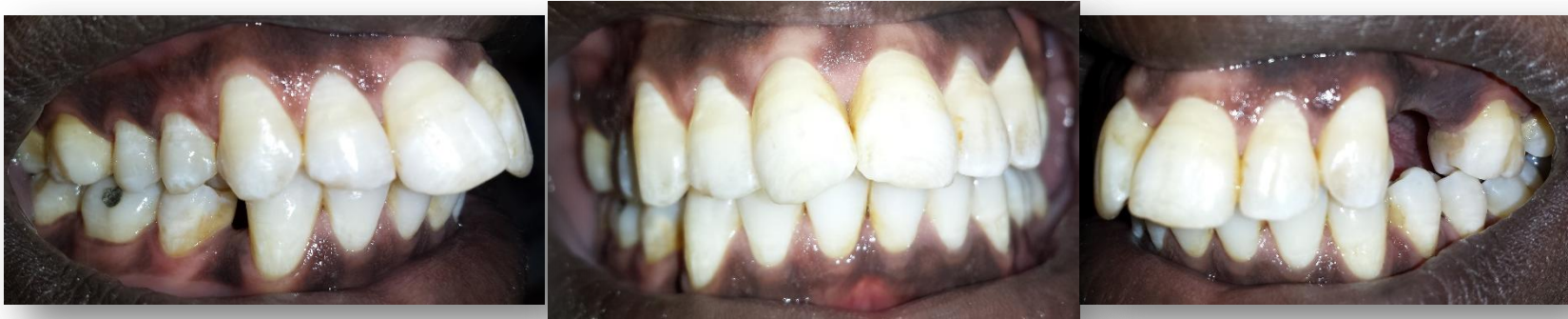# Treatment Plan



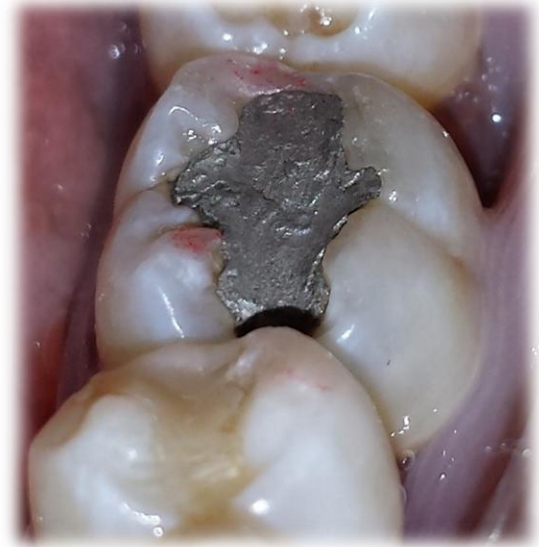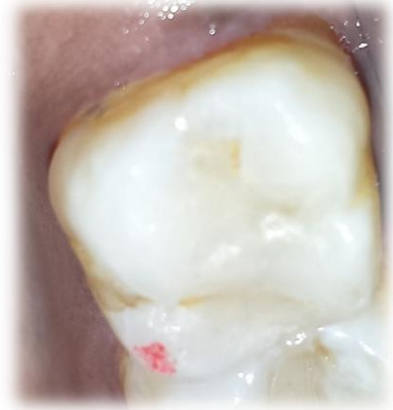

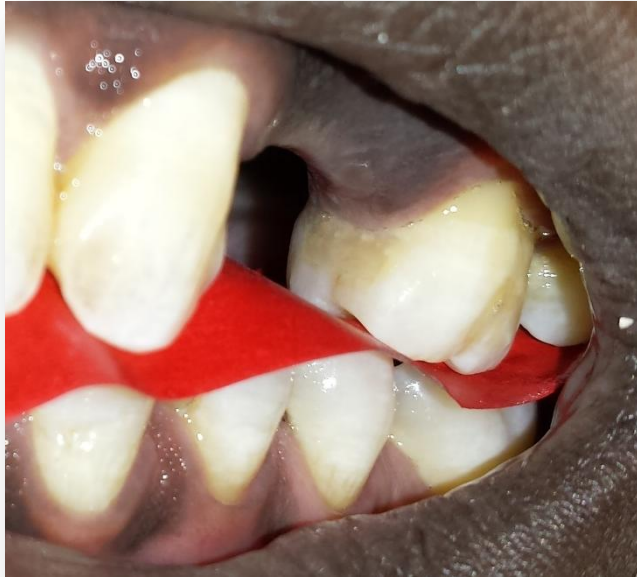
# Phase I: OHI + Scaling & localized root planning

- Education and motivation.
- Oral hygiene instructions.
- Scaling and localized root planning.



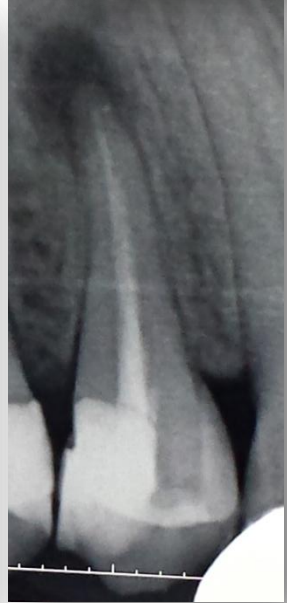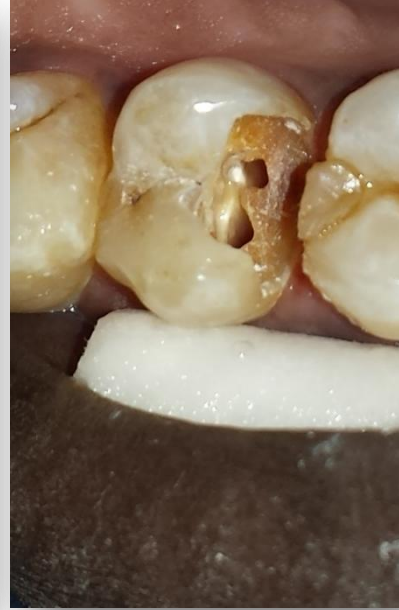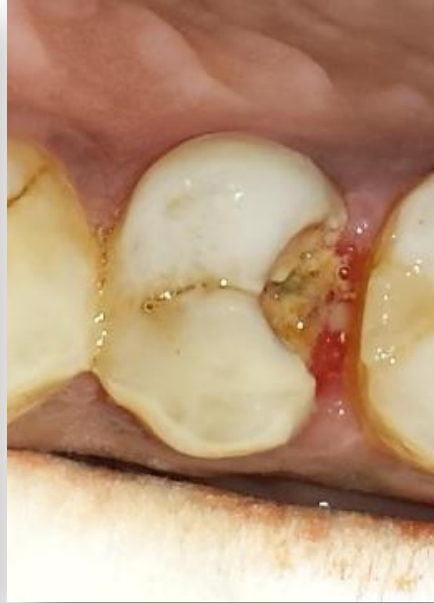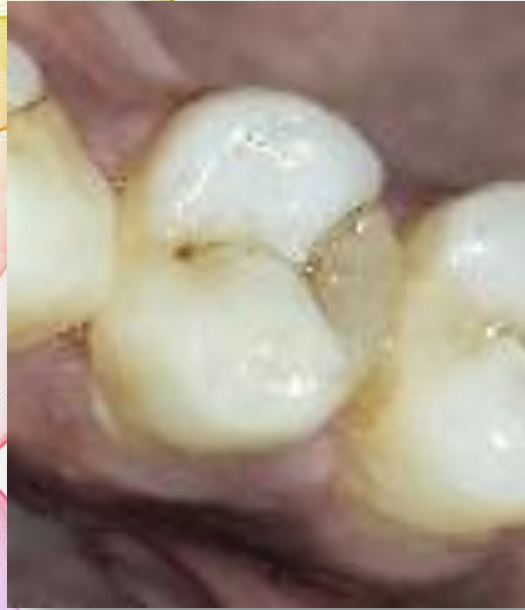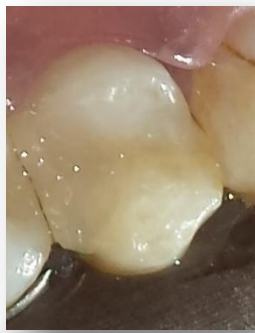# Phase I: Occlusal adjustment





# Phase III:

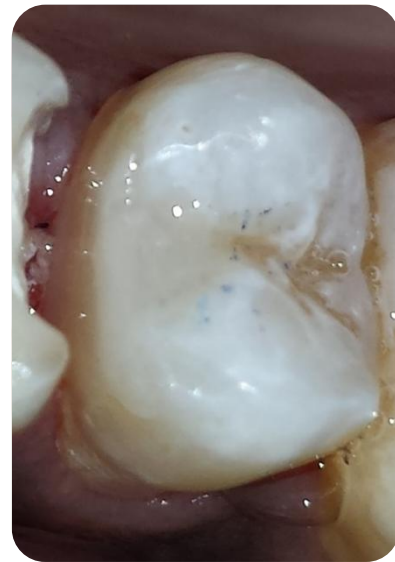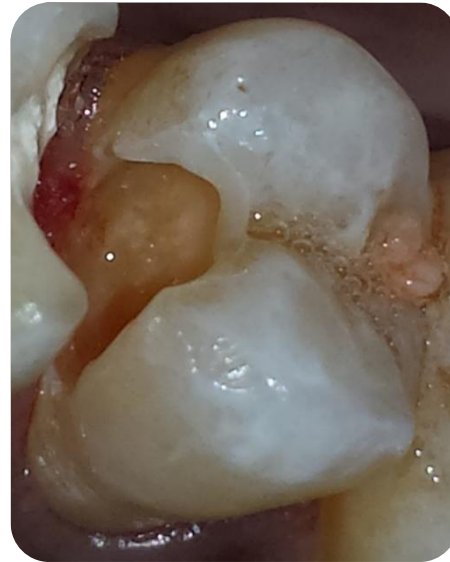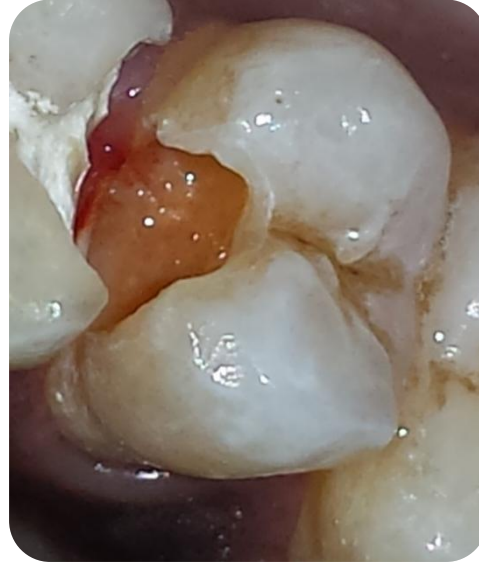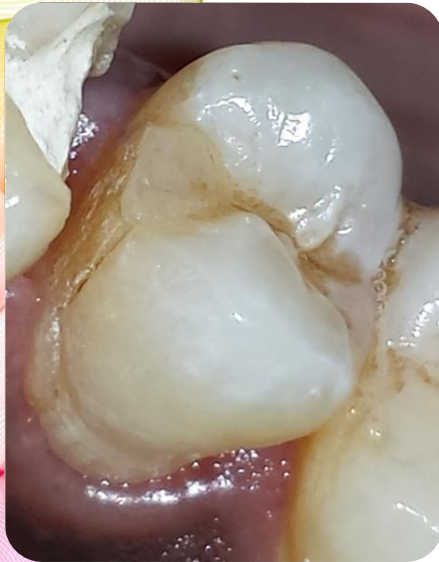- RCT for  $\frac{4}{\quad}$



## Phase III:

- Mesial Class II Composite Restoration for

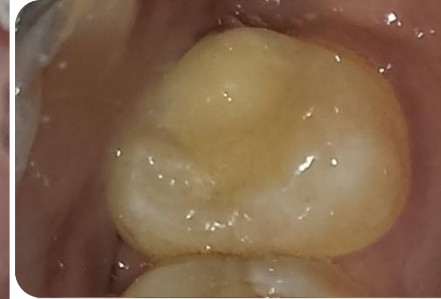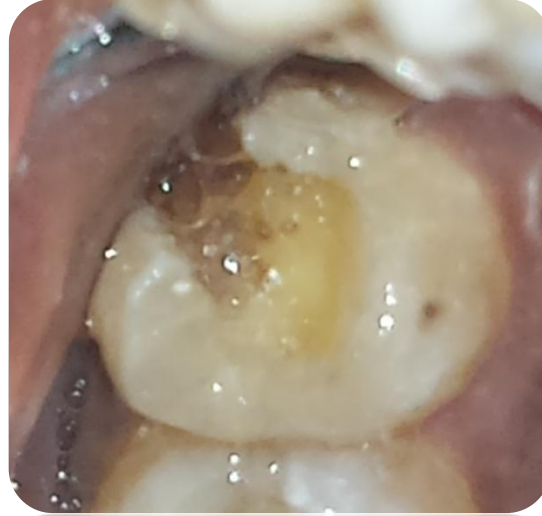
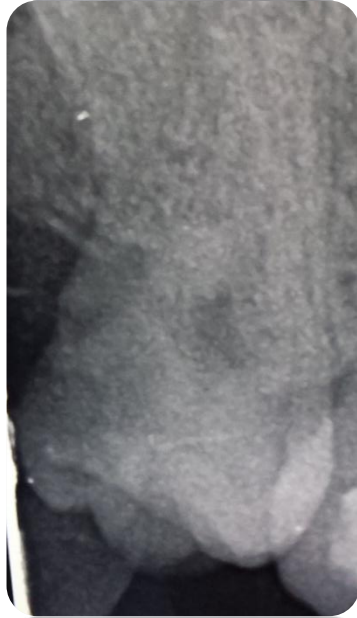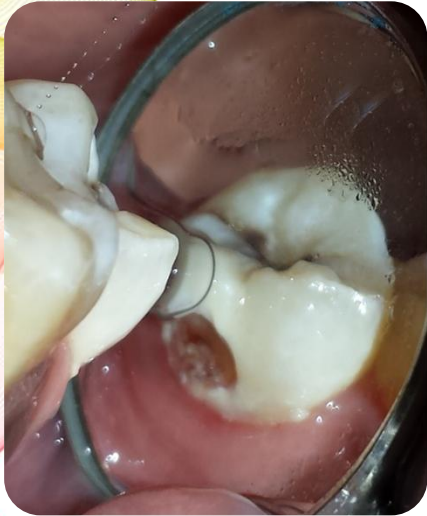5



## Phase III:

- Occluso-distal Class II Composite Restoration for

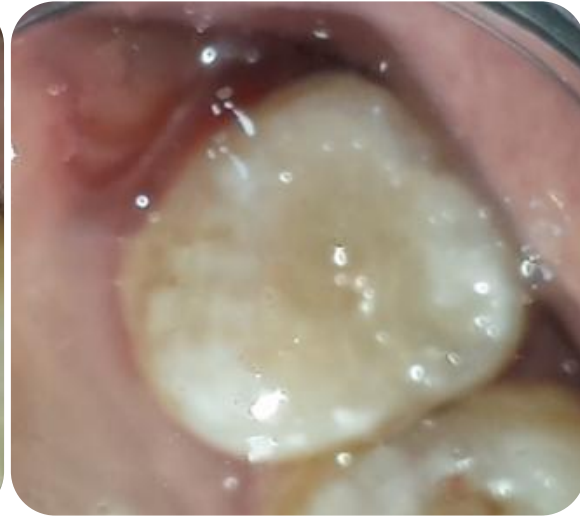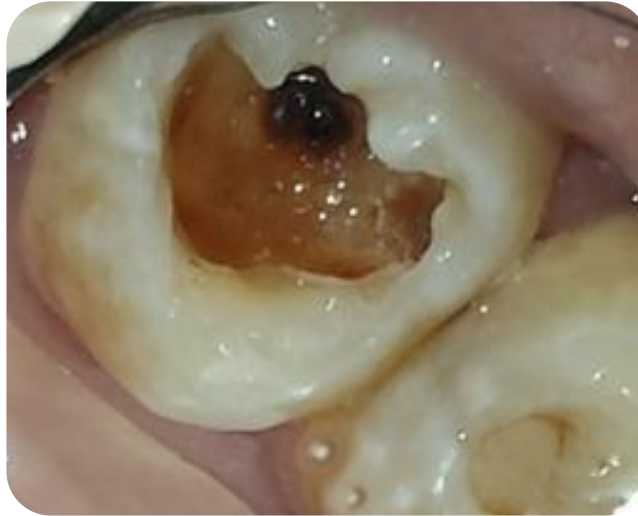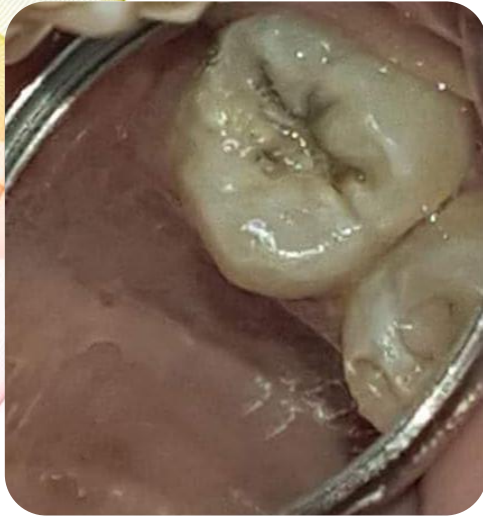8



## Phase III:

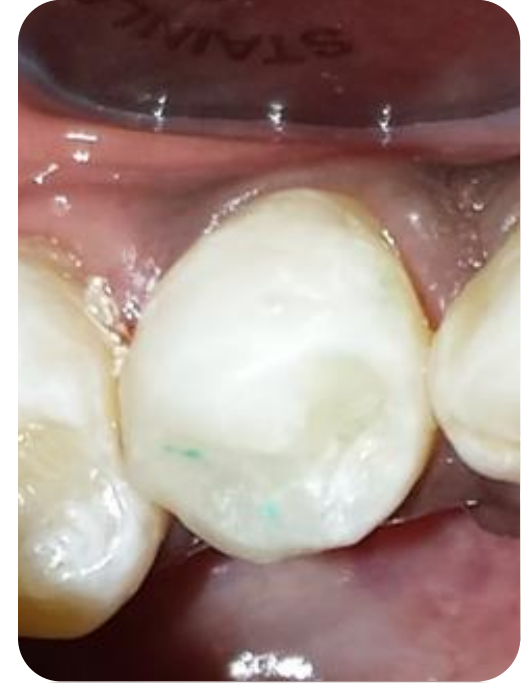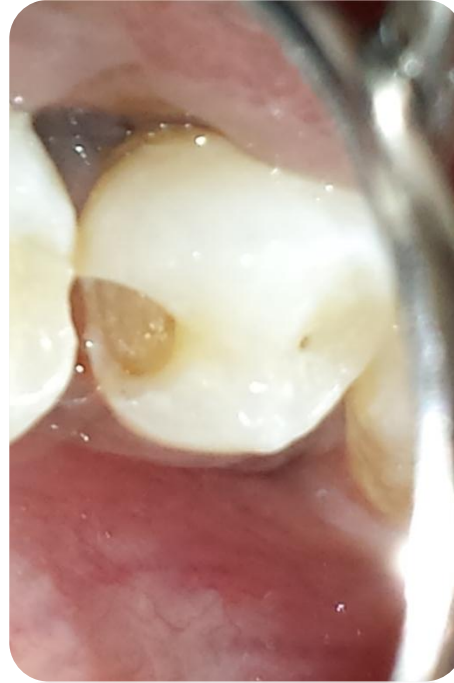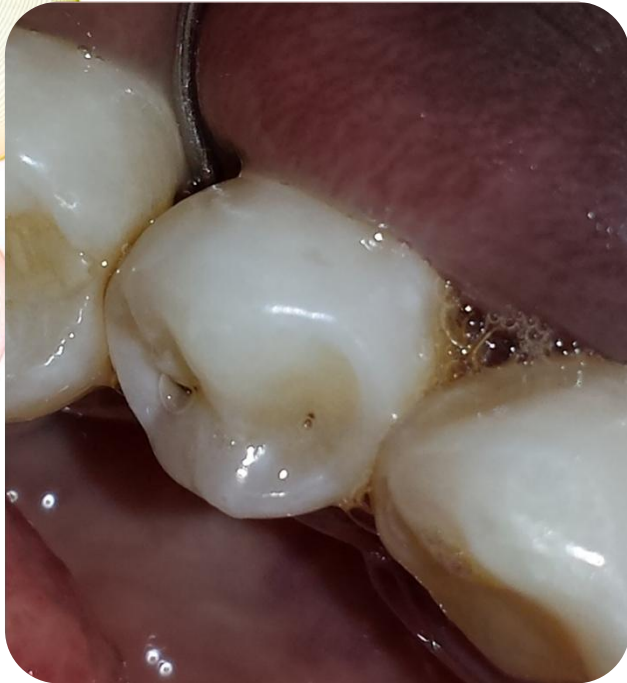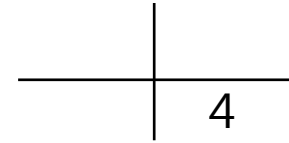
- Occlusal Class I Composite Restoration for

8



## Phase III:

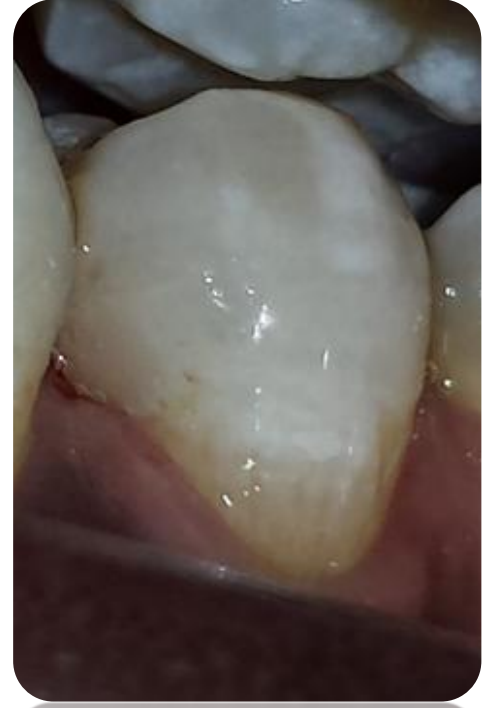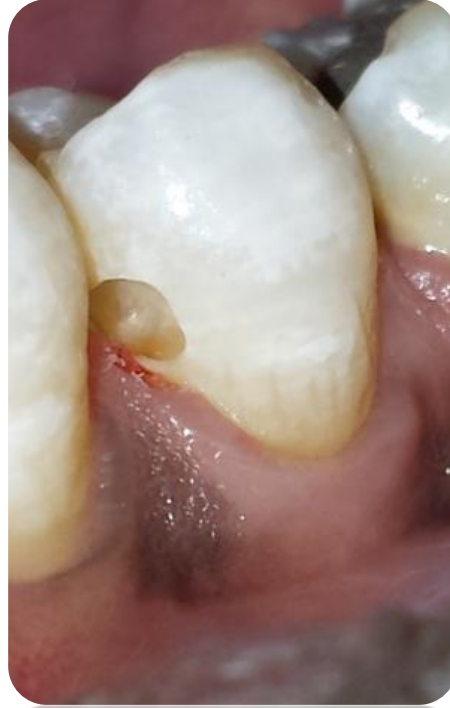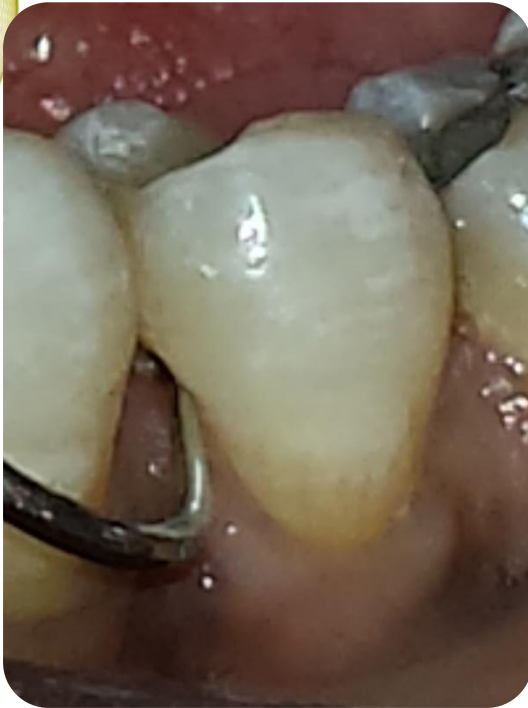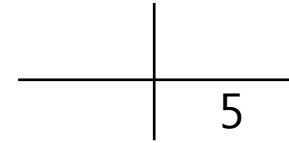
- Distal Class II Composite Restoration for





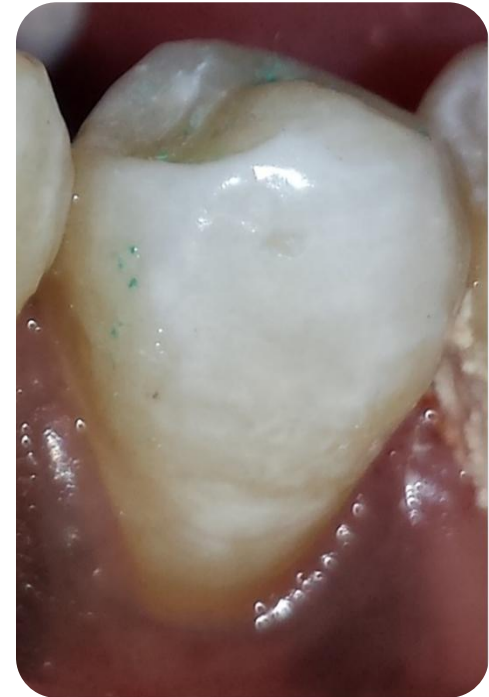
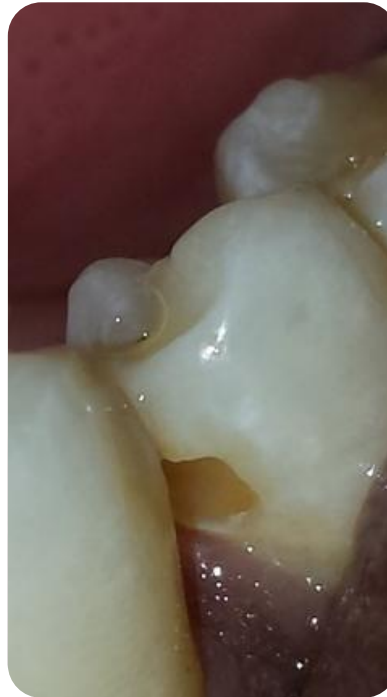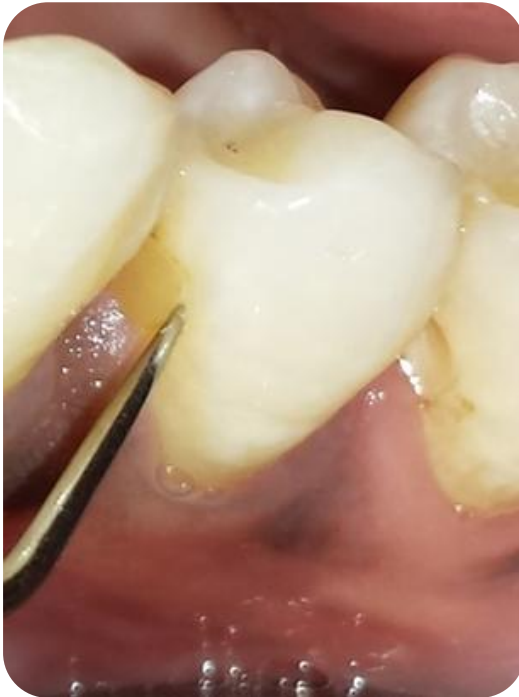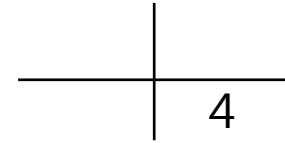## Phase III:

- Mesial Class II Composite Restoration for (Buccal approach)



## Phase III:

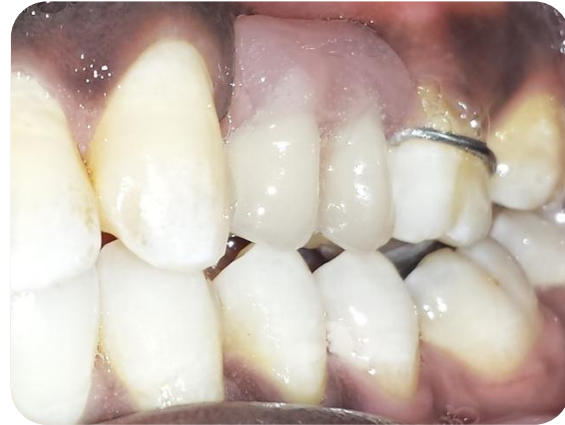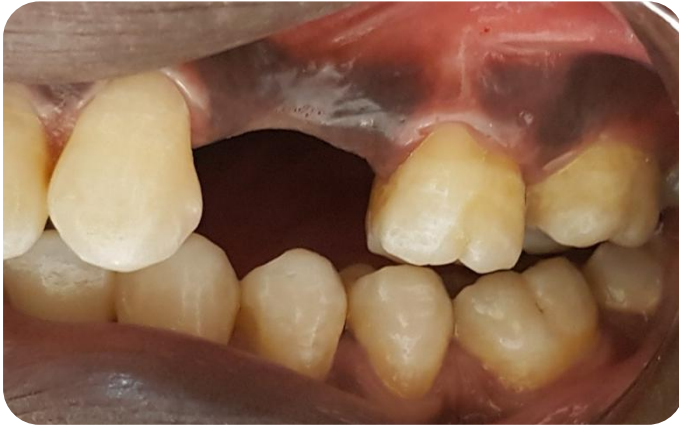- Mesial Class II Composite Restoration for (Buccal approach)



## Phase III:

- Replacement of missing teeth:

45

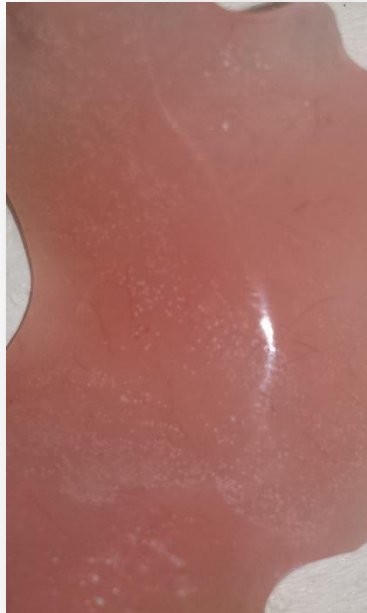

## Phase III:

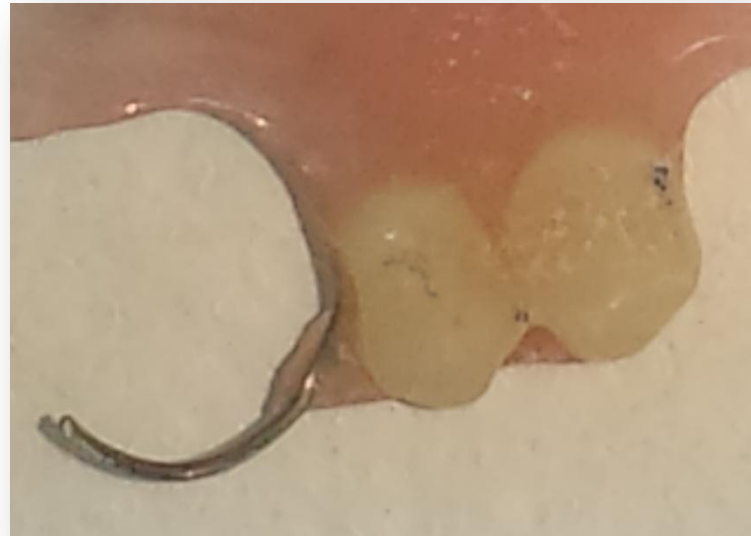
- Replacement of missing teeth with RPD:
- Problems:

45

Porosity:



High points:

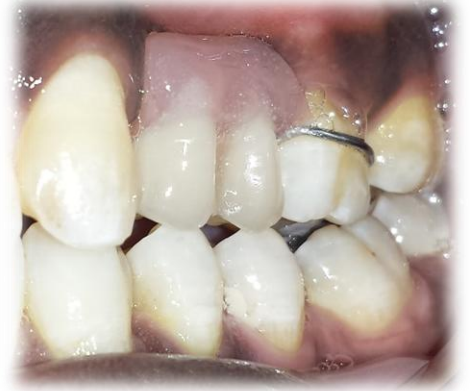
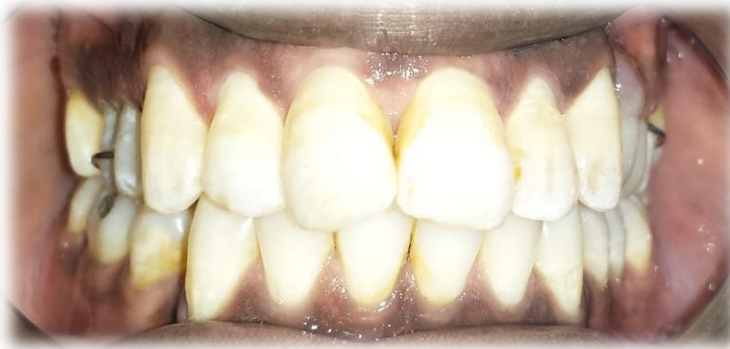
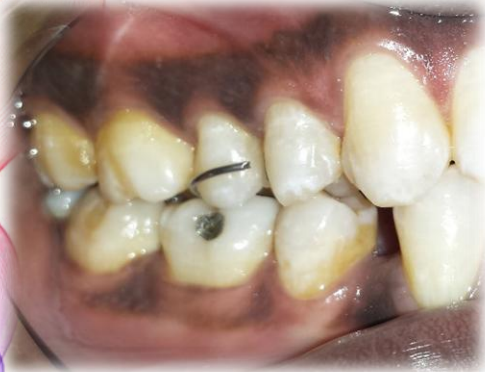
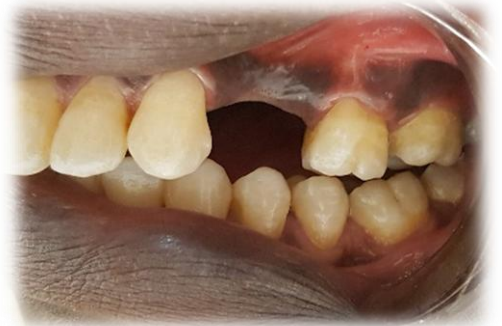
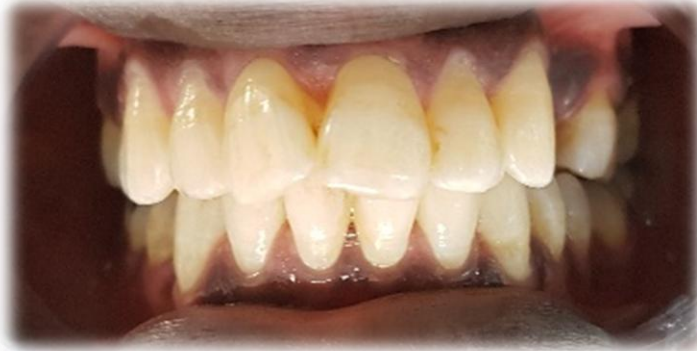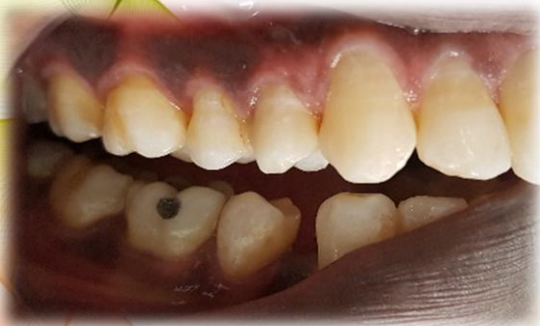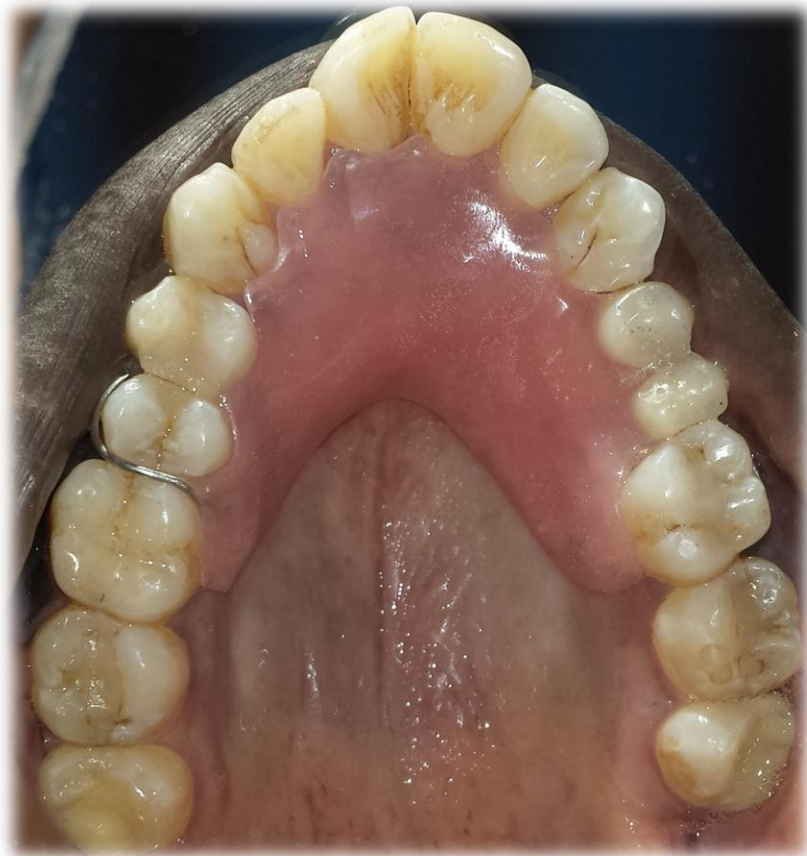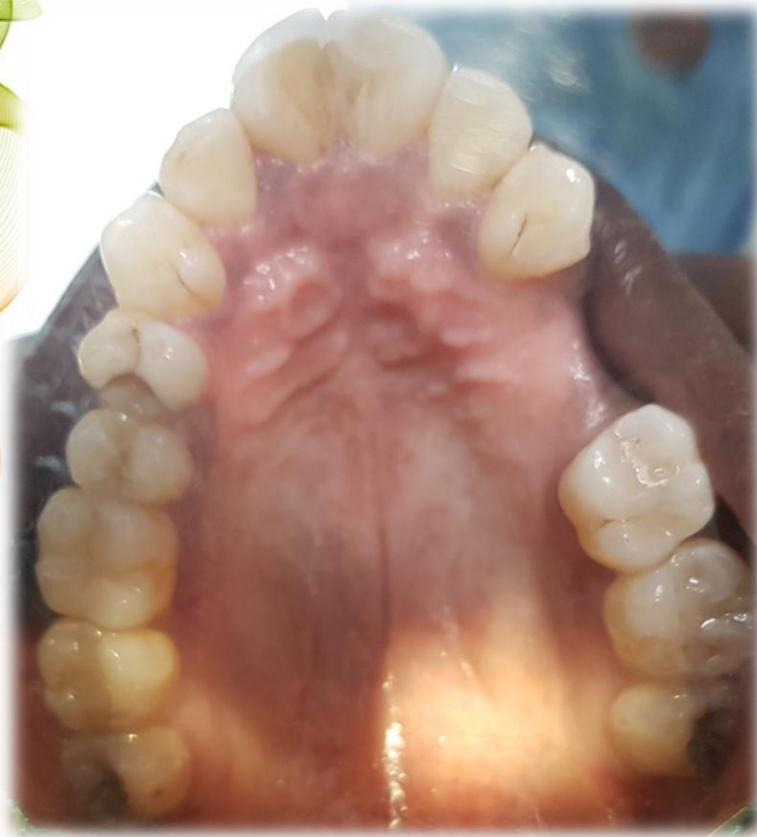## **Phase IV: Follow up & maintenance**

- **Recall after 3 months:**
- To evaluate oral hygiene & periodontal health.
- To evaluate all the restorations & the prosthesis.
- To evaluate the healing of the preapical lesion of
- **Recall for 6 months for regular dental check ups.**

# Before & After



# Before & After



# Before & After





