



Libyan International Medical University
Faculty of Dentistry
(December-2019)

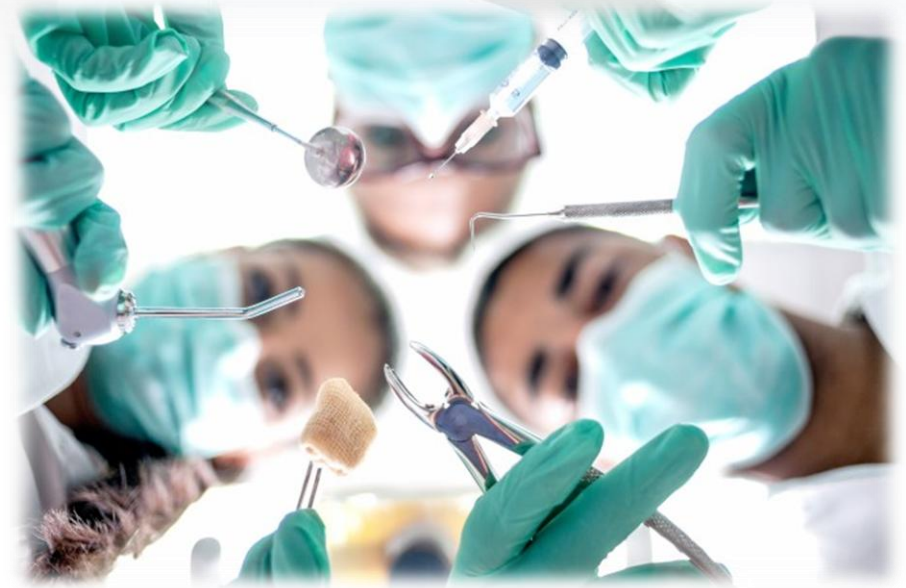Comprehensive dental treatment case.

Presented by:
Asma Taha Saleh Albargathi .
Roll No : 869



*This work was done under supervision of
a group of teaching staff in LIMU dental
clinic.*

- *Dr. Rafik alkwafi.*
- *Dr. Abdelmonem Abdelnabi.*
- *Dr. Hashim Alobidi.*
- *Dr. Ali Abusnina.*
- *Dr. Omar Alhuni.*
- *Dr. Malek Abdulmatlob.*
- *Dr. Masoud Dihoum.*
- *Dr. Amal Alawami.*
- *Dr. Nuha Alkadiki.*
- *Dr. Ghalia Omran.*
- *Dr. Khadija Alflallah.*



Patient details

- Patient's name: **H.N.H**
- DOB: **2nd Oct, 1992**
- Gender: **Female**
- Nationality: **Libyan .**
- Occupation: **Teacher**
- Address: **Buhdyma \ Benghazi**
- Marital status: **Single**

Chief complaint

patient came to the LIMU dental clinic complaining from pain in the upper left side “in front area” of the mouth started from 3 days ago.

History of chief complaint:

Gradual and sever throbbing pain, well localized, spontaneous and increased by cold drinks, air and when she bites, its duration for 15 min at least, and no relieving factors, this pain interferes with night sleeping, also she mentions this pain associated with headache.

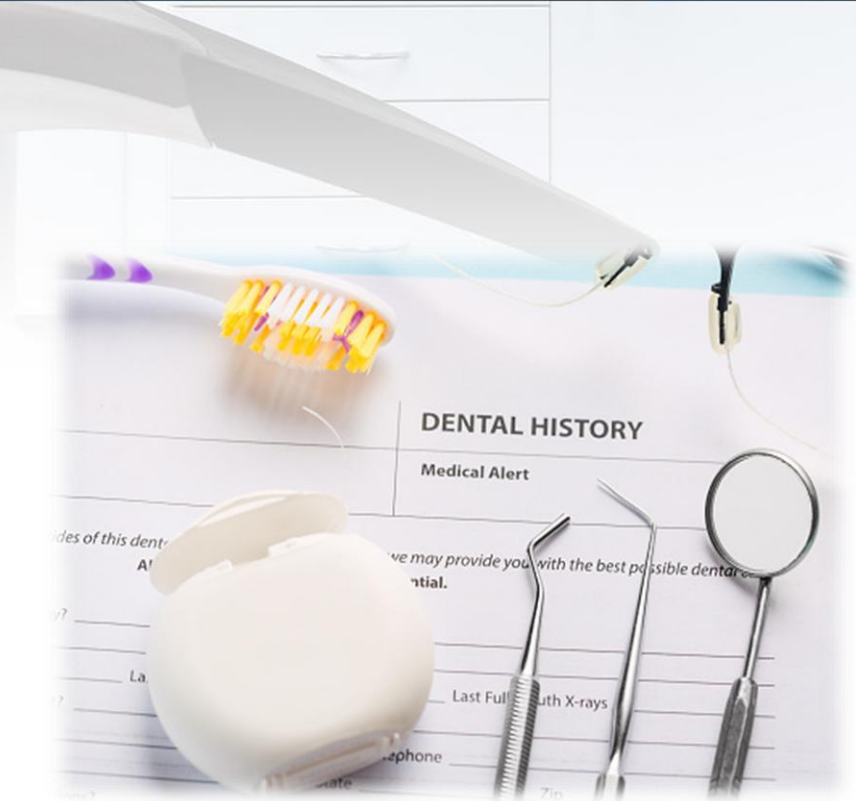Medical history

- Patient is medically free from any diseases or allergies and has no drug history, just she takes a pain killer like Ketofan when she needs.
- No history of any hereditary disease in her family.



Dental history

- **Oral hygiene practice:**
Irregular teeth brushing
1\day at morning ,without
any other special dental
care.
- **Type of dental treatment:**
Restoration and extraction
since 6 months without
any complications.





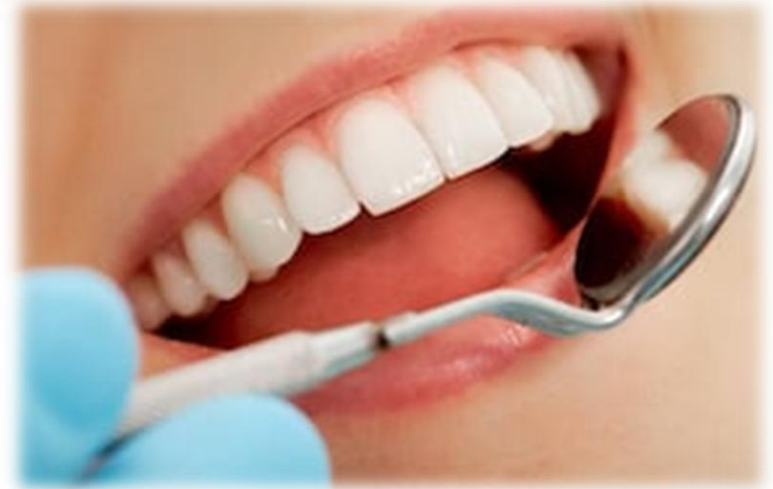Extra-oral examination

- Face: symmetric.
- Profile: convex
- Skin : normal.
- TMJ: normal.
- Lymph node: not palpable.

Intra-oral examination

Soft tissue examination:

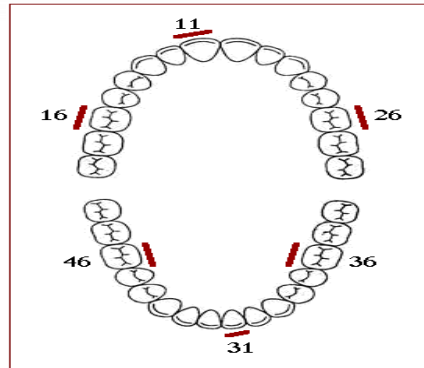
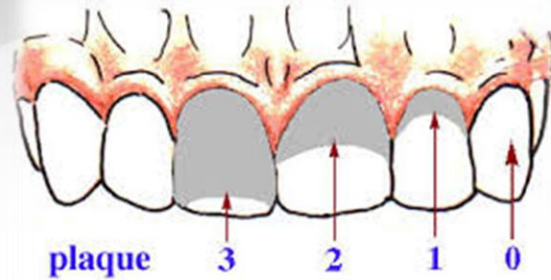
- Lips : normal and partially competent.
- Buccal and alveolar mucosa: normal
- Floor of the mouth: normal
- Tongue: normal
- Hard and soft palate: normal.
- Oropharynx: enlarged tonsils



Oral hygiene index-simplified:

Plaque index

16	11	26
2	0	2
1	0	3
46	31	36

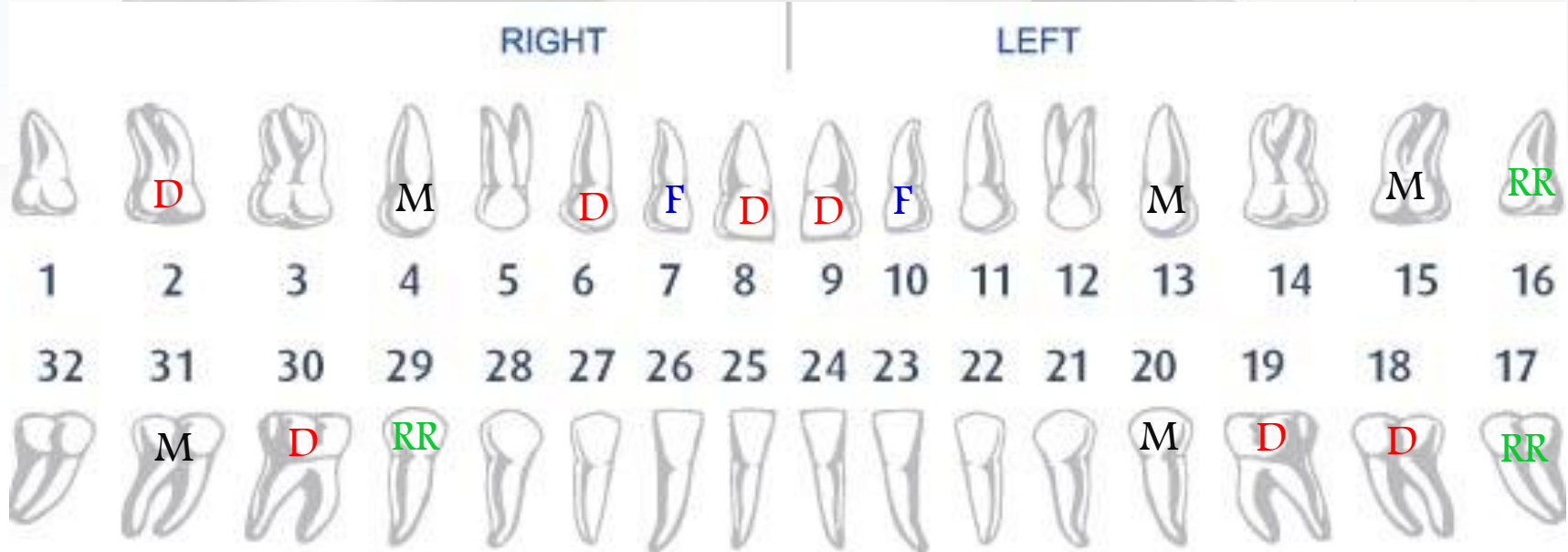


calculus index

16	11	26
1	0	1
1	0	2
46	31	36

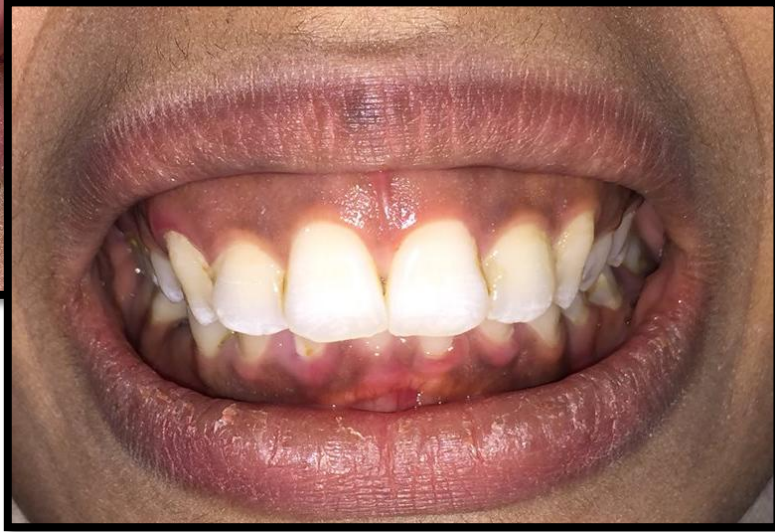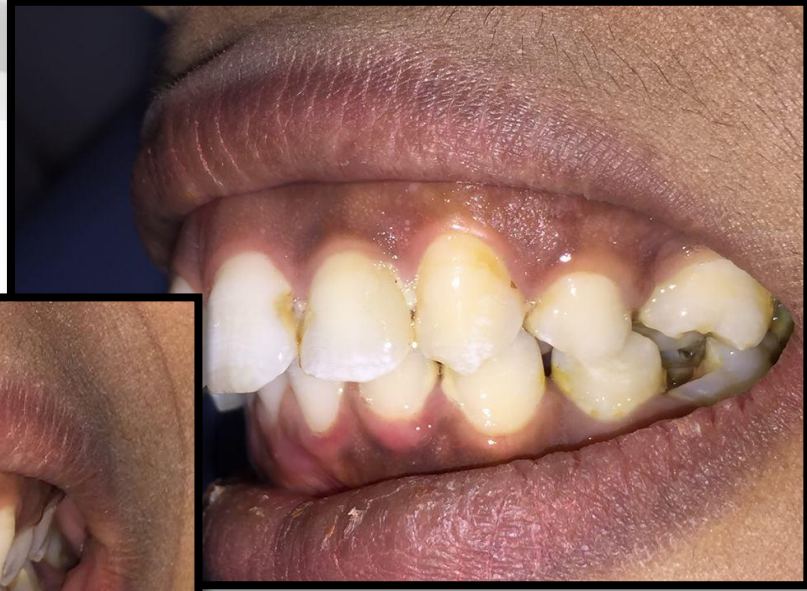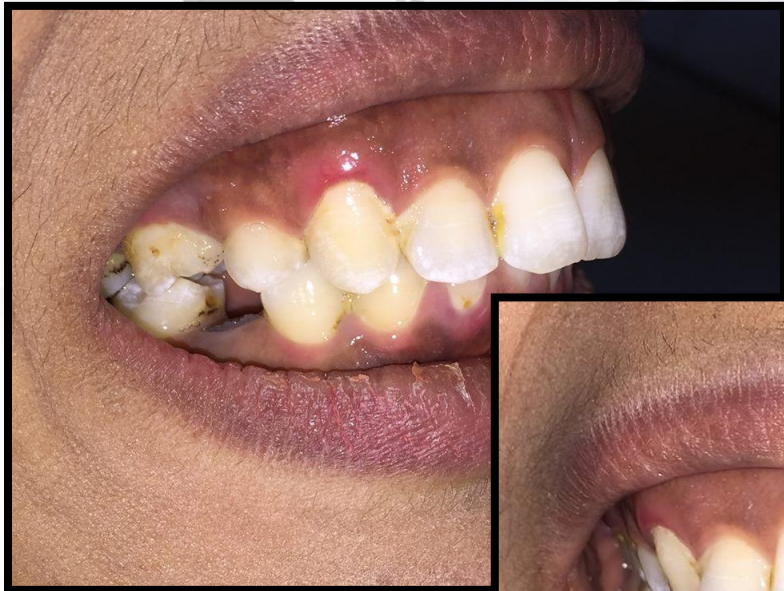OHI-S = 2.16 (fair)

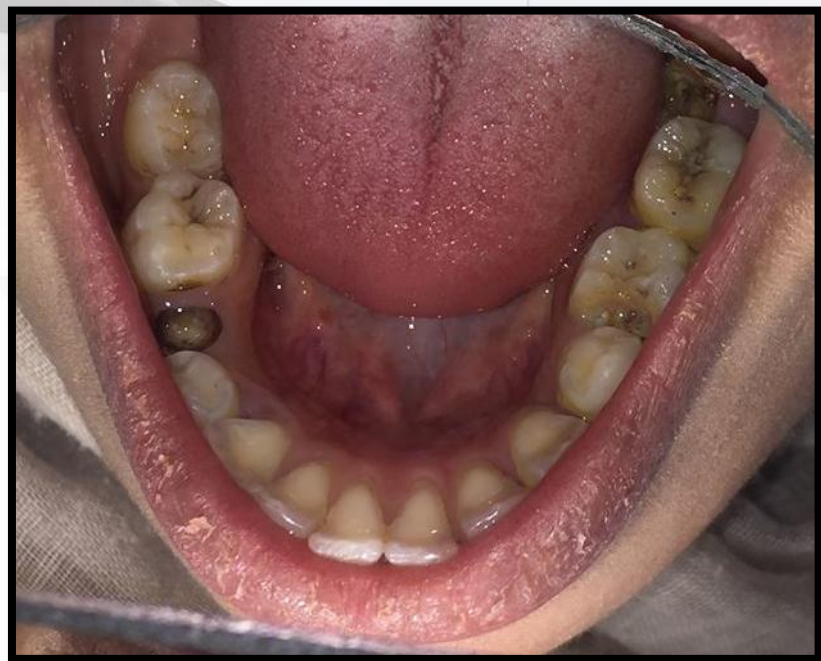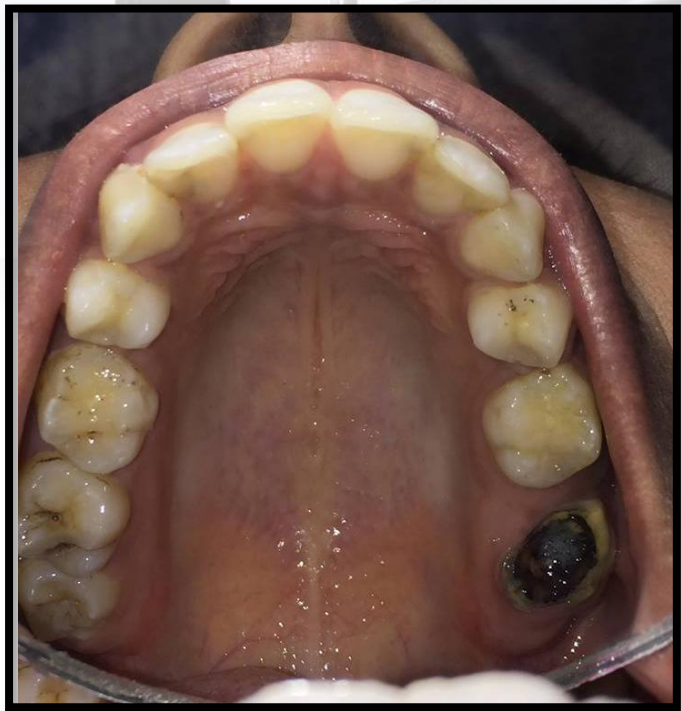
Hard tissue examination:



Caries: **D** Filling: **F** Extracted or missing: **M** Remaining root: **RR**

Intraoral photographs







Intra oral findings:

- ✓ No signs of wasting diseases of teeth.
- ✓ Loss of proximal contact in posterior upper and lower regions and in lower anterior area.
- ✓ No gingival recession.
- ✓ No furcation involvement.
- ✓ No crowding of teeth.
- ✓ No TFO, open bite and cross bite, but she has a deep bite and increased OJ.
- ✓ Midline in lower arch is shifting toward right side.

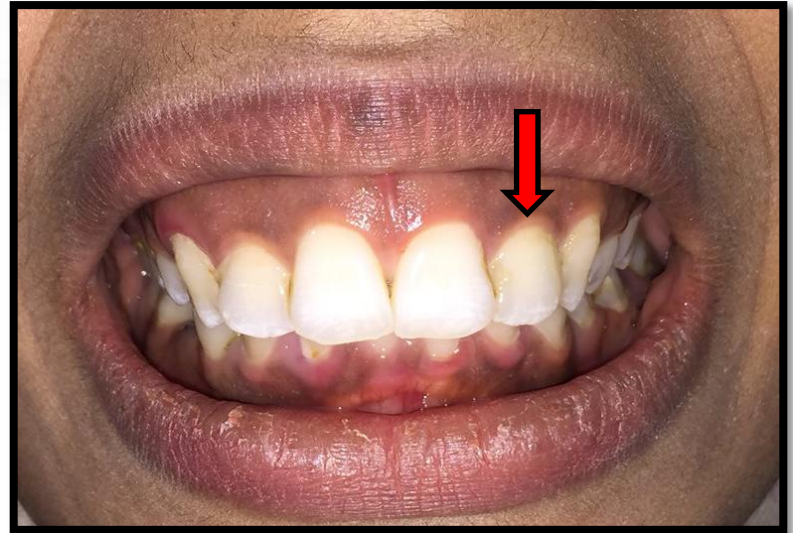

Gingival status:

- ✓ Color of gingiva: pinkish-red in all sextant.
- ✓ Gingival contour: scalloped, round margin and blunt interdental papilla.
- ✓ Size of gingiva: normal **except in Man. Anterior area was enlarged.**
- ✓ consistency: firm and resilient **except in Man. Anterior area was soft and edematous.**
- ✓ Stippling: present in Max. Anterior area.
- ✓ Position of gingiva: at CEJ except in Man. Anterior was coronal to CEJ.
- ✓ **Bleeding on probing: present in each sextant except in Max. Anterior.**
- ✓ Exudation: -ve in all sextant.
- ✓ **Probing depth: ranged between (1 to 3) mm.**
- ✓ **Clinical attachment loss: ranged between (0 to 4) mm.**
- ✓ Mobility: -ve in all sextant

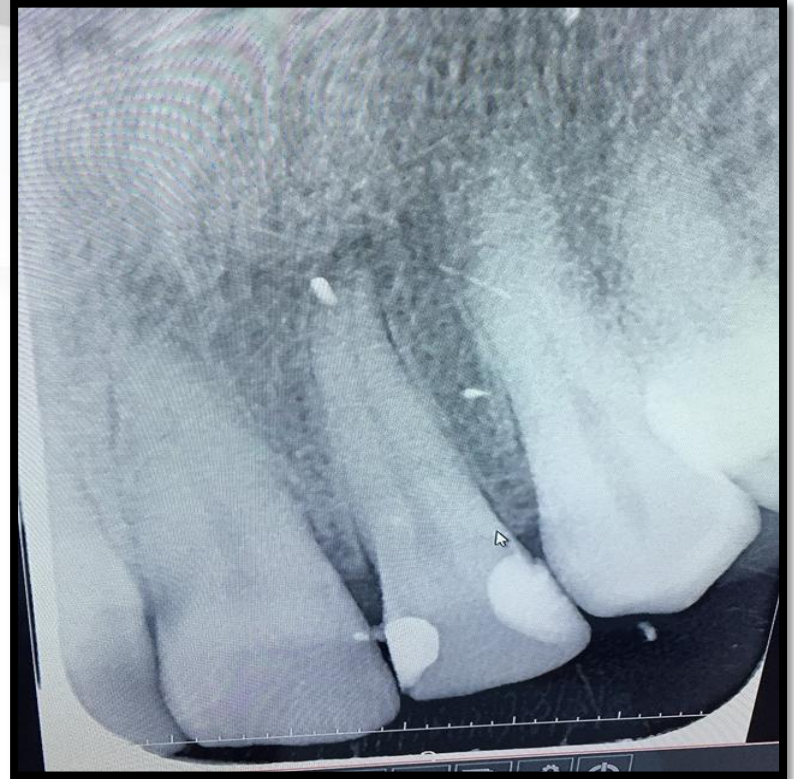Investigations

- ✓ **Inspection** : the UL2 has composite restoration from mesial and distal side.
- ✓ **Percussion**: tooth is tender.
- ✓ **Palpation** : tooth is tender.



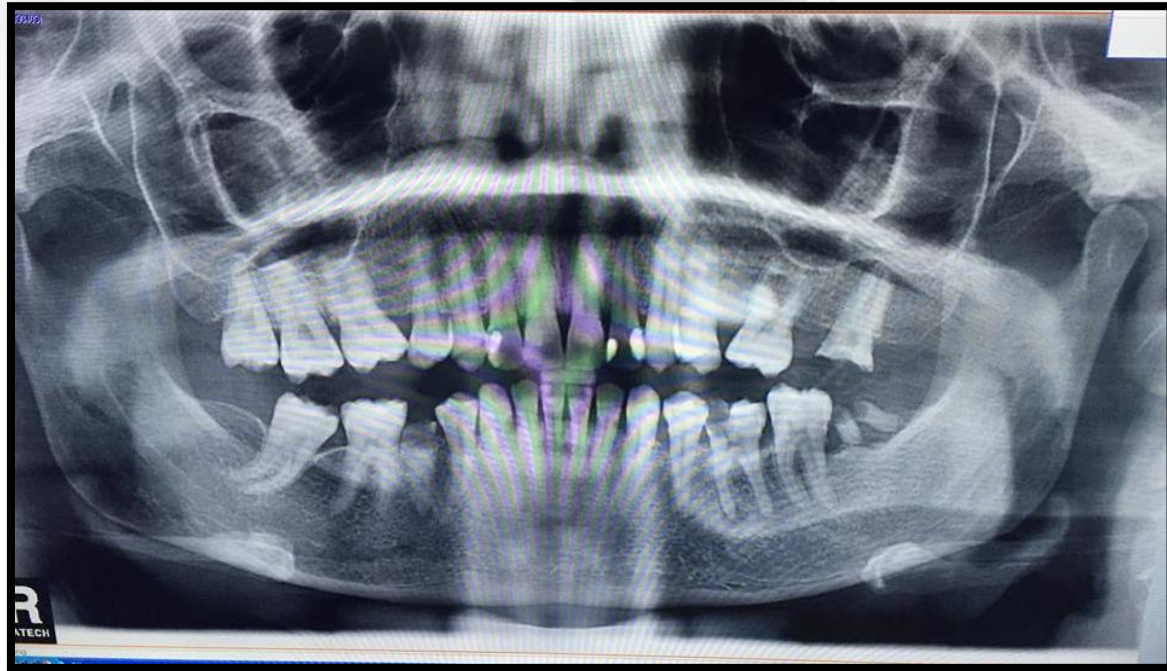investigations

✓ IOPA radiograph: shows a radiopacity in mesial and distal sides of coronal part of UL2 too close to the pulp with periapical changes, discontinuity in lamina dura and widening in PDL space.

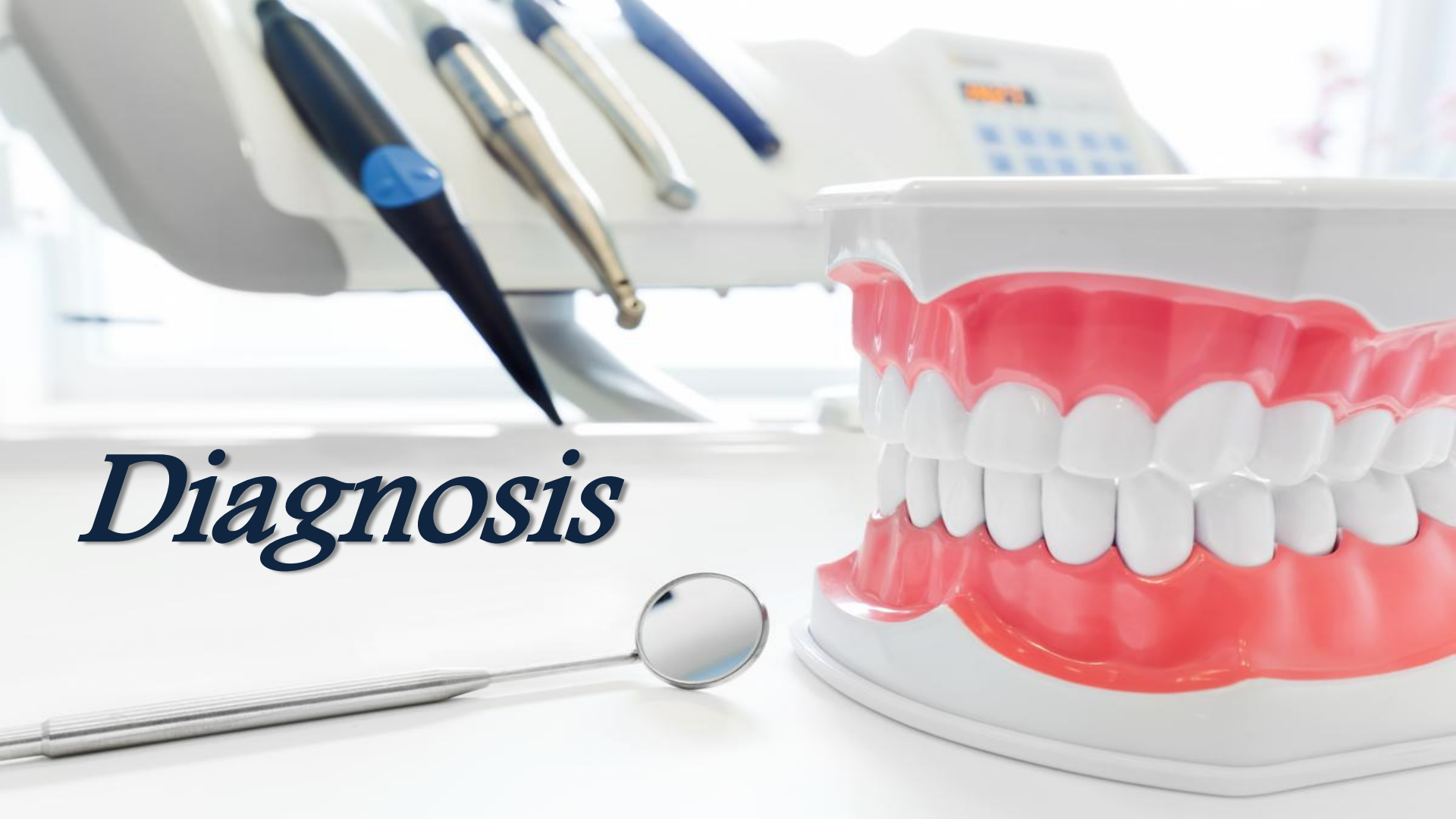

OPG analysis:

- ✓ No bone pathology.
- ✓ reduced alveolar bone level.
- ✓ All teeth are present except the LR7, UR5 and UL5,7 are missing.
- ✓ LR5,LL8 & UL8 are remaining roots
- ✓ Normal root length.
- ✓ Normal root anatomy except the LR8 is curved distally .



Diagnosis



A blurred background image of a dental office, showing a dental chair, a sink, and a cabinet. The image is partially obscured by a dark blue diagonal overlay in the top right corner.

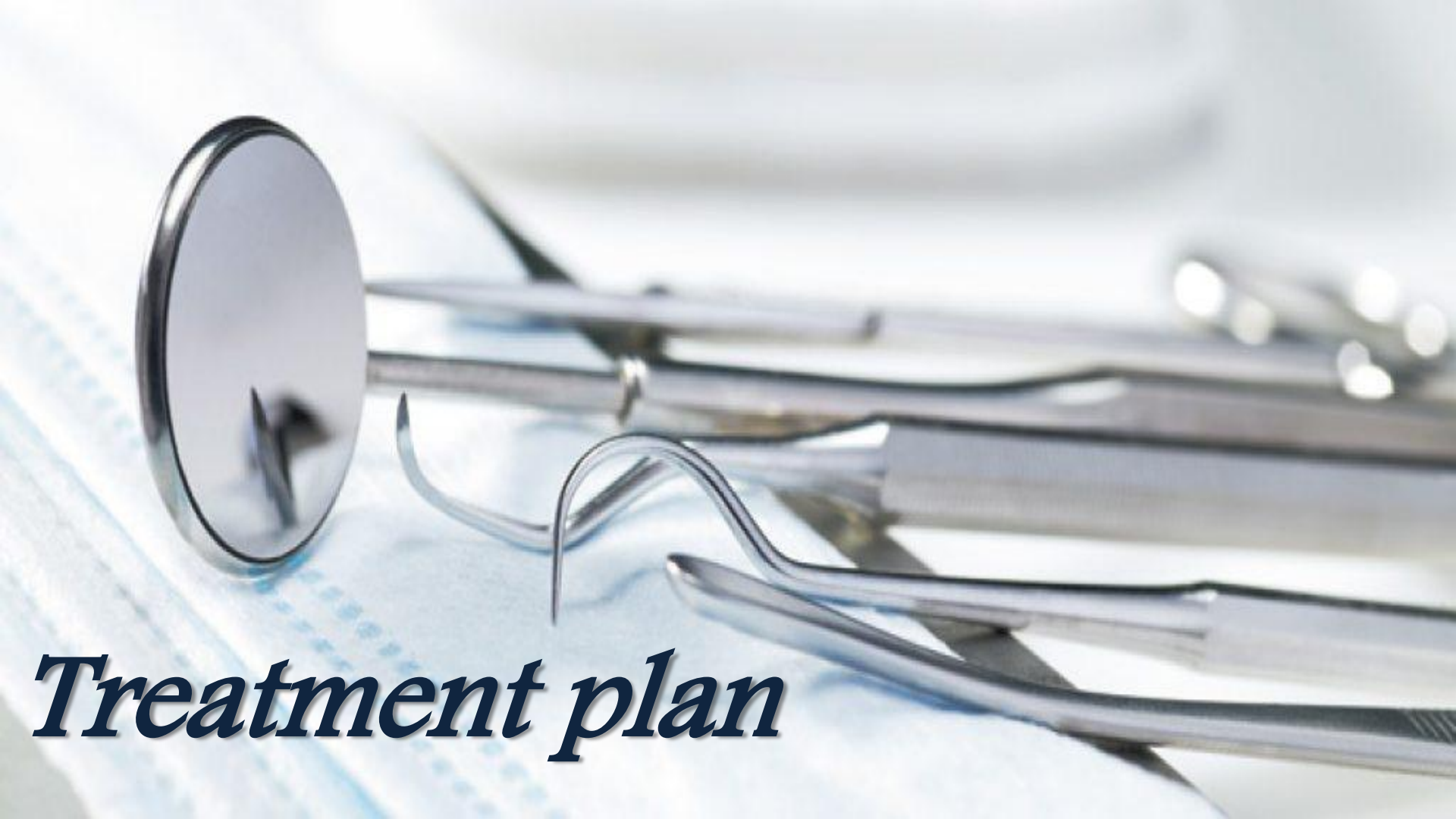Differential diagnosis

- ✓ Acute periapical periodontitis UL2.
- ✓ Chronic periapical periodontitis with acute exacerbation UL2.



Diagnosis

- Chronic periapical periodontitis with acute exacerbation **UL2**.
- Chronic periapical periodontitis **LL6**.
- Generalized chronic mild periodontitis.
- Dental caries **UR7,3&1,LR6, UL1,LL 6 & 7**.
- Remaining root **UL8,LL8** and **LR5**.
- Missing teeth **UR5,UL5 & 7,LL5** and **LR7**.



Treatment plan

Emergency phase

- Pulp extirpation 22

Phase 1

- Scaling and root planning.
- OHI and diet instructions.
- Patient education and motivation.

Phase 2

- Extraction of remaining roots 28,38 and 45.
- Root canal treatment 22 & 36.

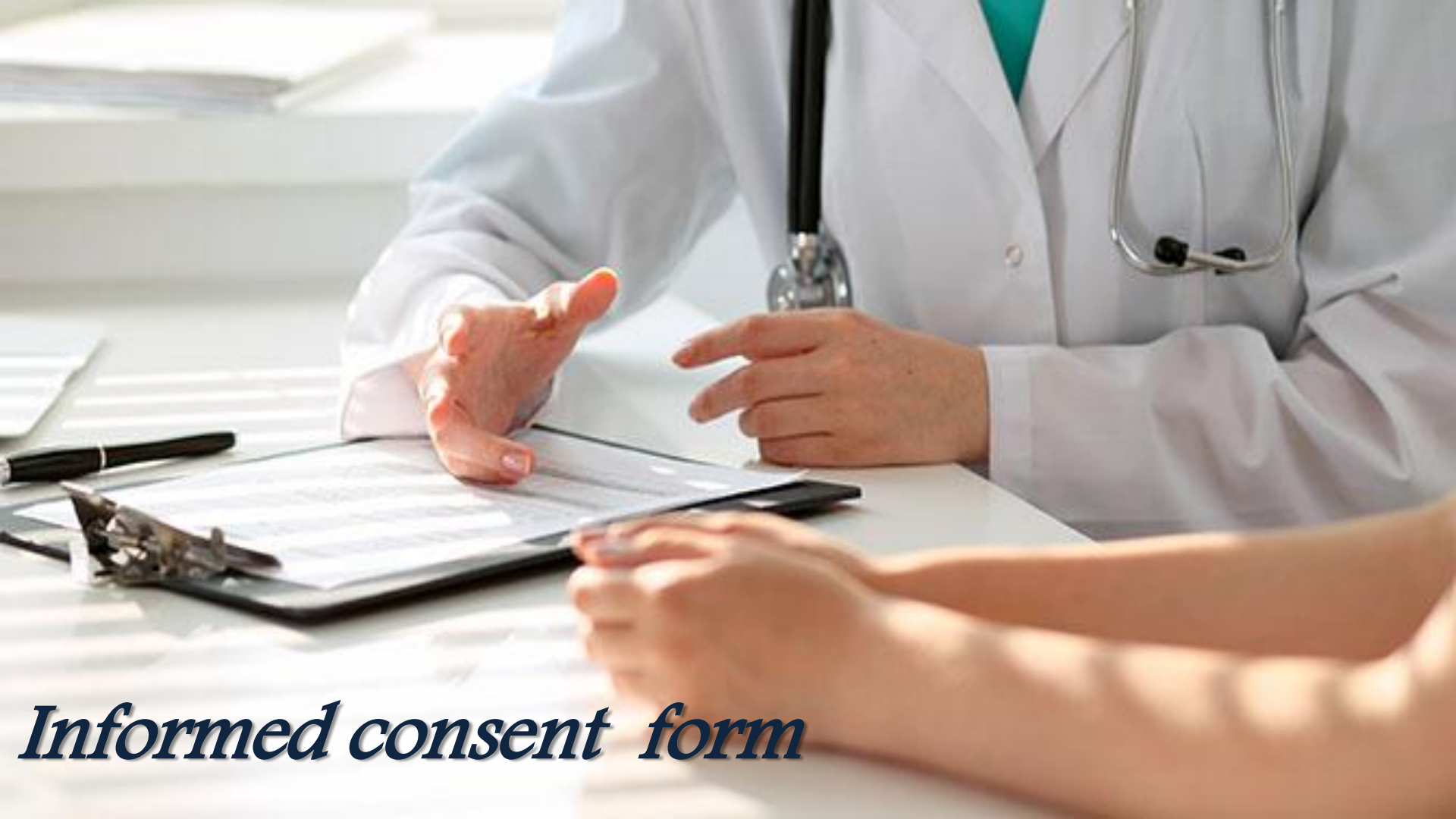Phase 3

- Restoration of 17, 13, 11, 12,21,37 and 46.
- Final restoration of endodontically treated teeth 22 & 36

Phase 4

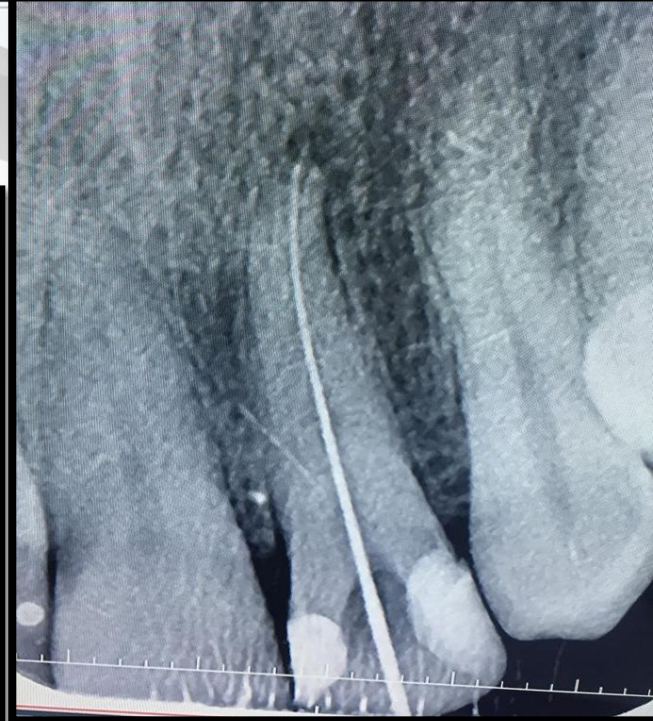
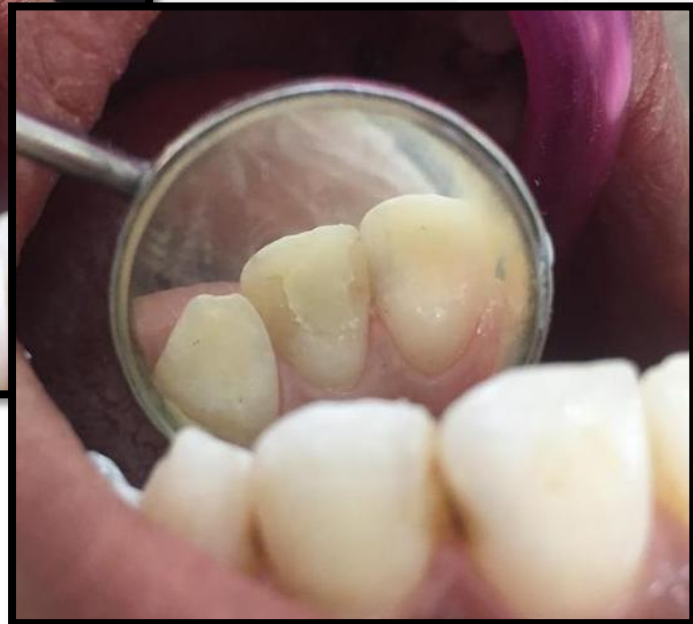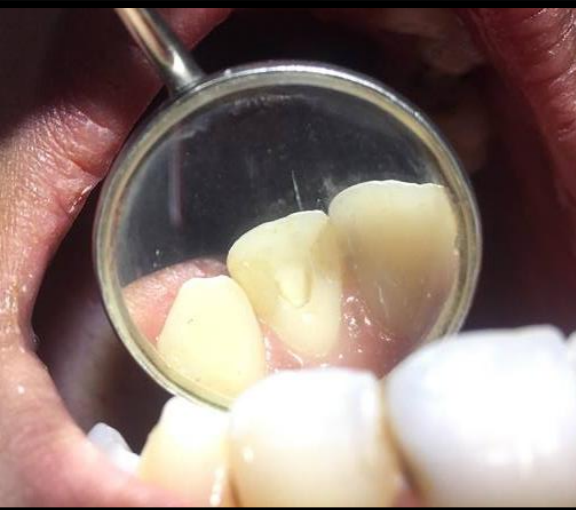Replacement of missing teeth 45

maintenance

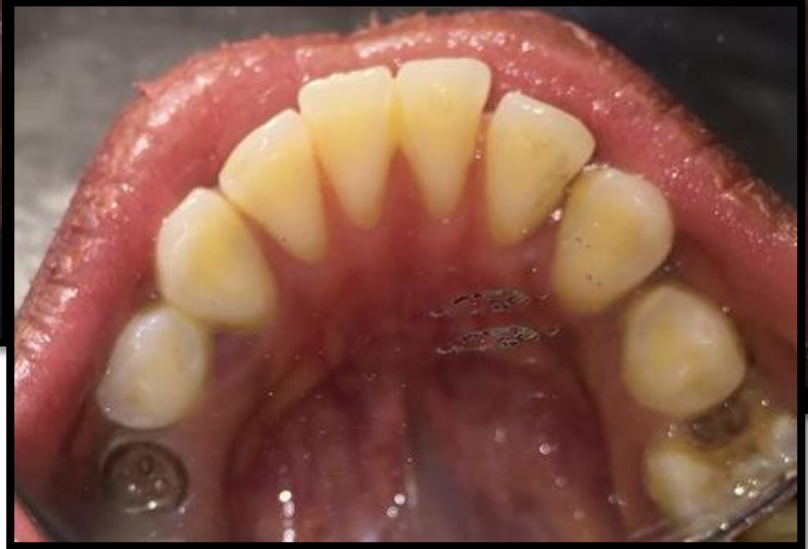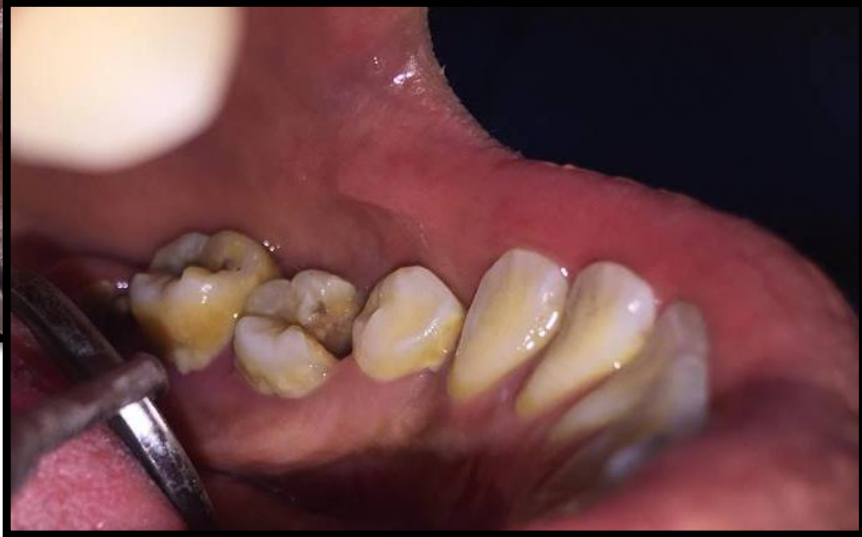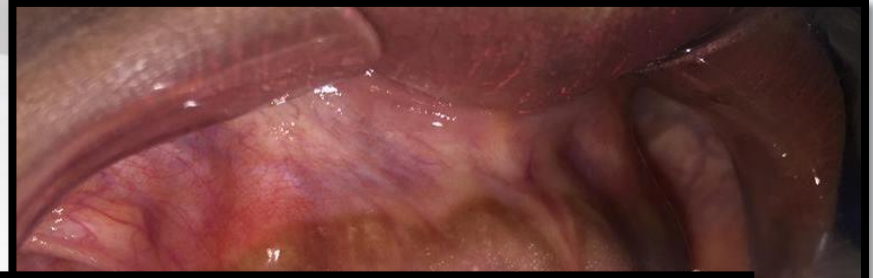


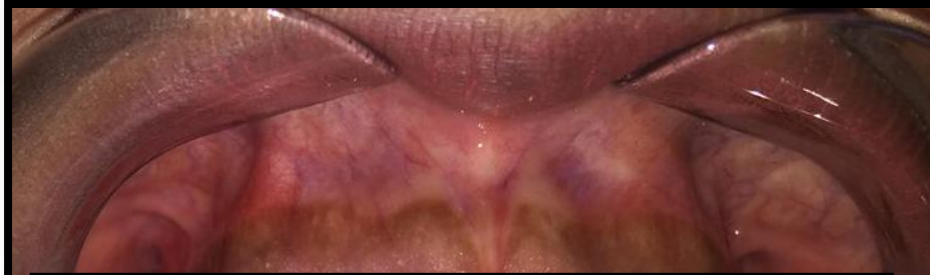Informed consent form

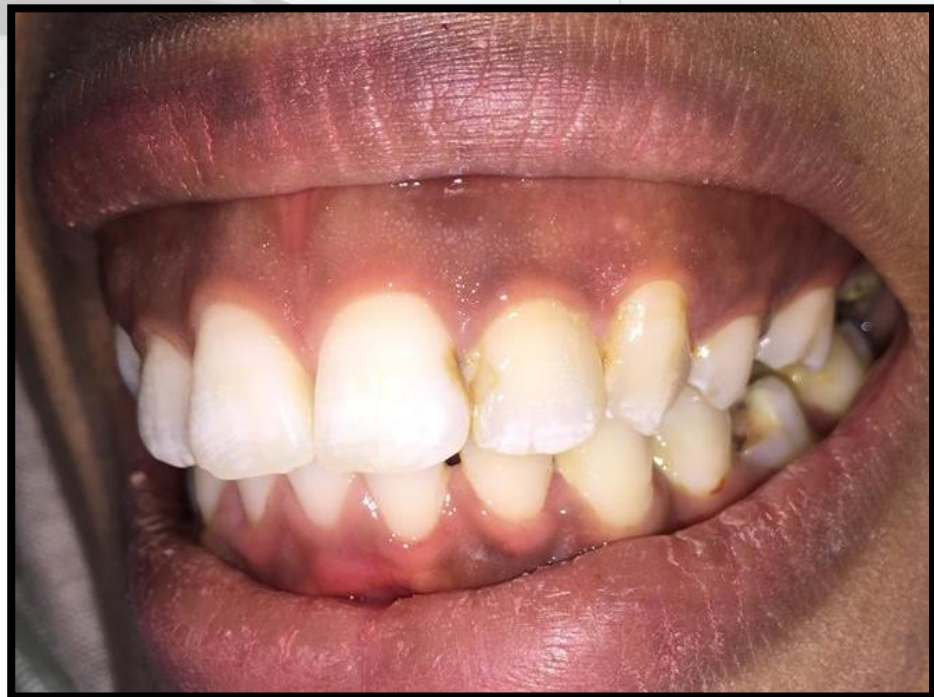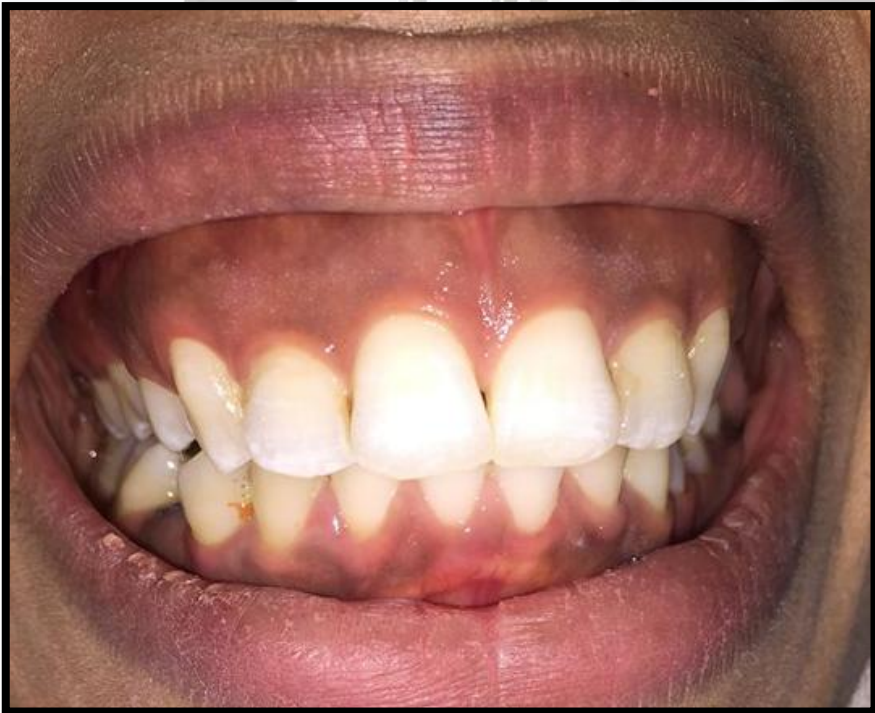Emergency phase



Phase 1 (Before).



(After).

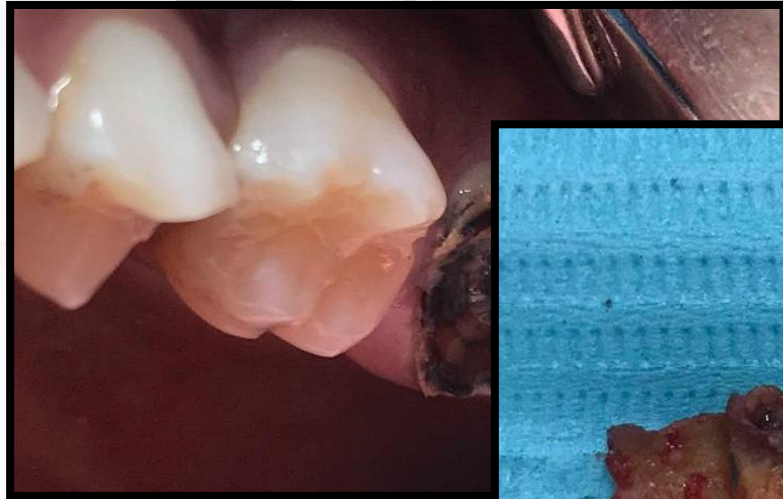

✓ Diet instructions

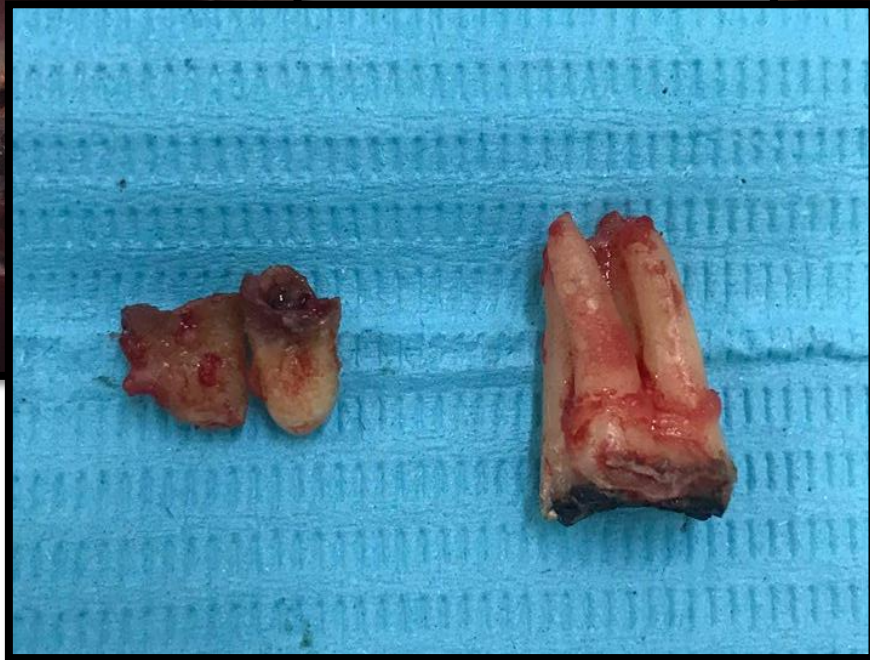Patient Name: هنية ناجي الصوي Gender: M/F Date of Birth: 2/16/1992
Occupation: معلمة Address: بوسعيدة

نوع الوجبة	المأكولات والشروبات	الساعة	الأيام
فطور	سجدة ✓ قهوة + كيلة x	7:00	الخميس
فطور	قهوة x	9:00	
غداء	قهوة x طماطونة	11:30	
غداء	طماطونة	1:30	
عشاء	رز بالخلطة و معالج + تمرزة + مزار ✓ سلو لاطة x	8:00 12:00	
فطور	سجدة ✓	9:30	الجمعة
غداء	قهوة + ملاحه + ماء ✓ سلو لاطة x	1:00	
عصير	قهوة + استويات + ملاحه ✓ سلو لاطة x	5:00 10:00	
فطور	قهوة + كيلة x	9:00	السبت
غداء	مكرونة أمبروة ملاحه ✓ ميه ✓	1:30	
عصير	قهوة + كيلة x + سلو لاطة x	4:30	
عشاء	فاصوليا + ميه x	8:30	

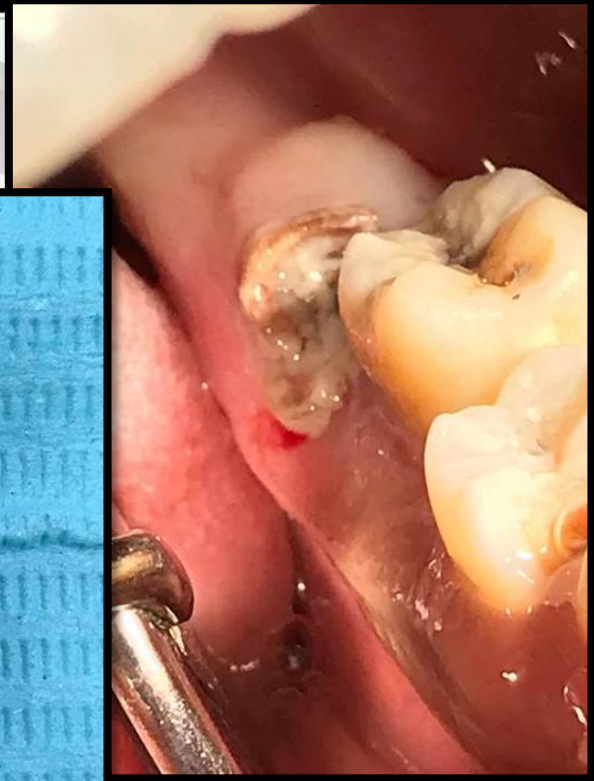Phase 2

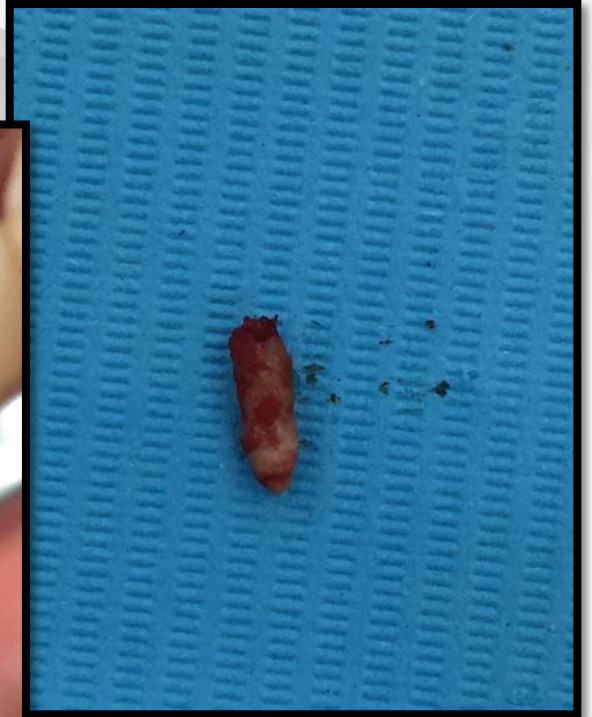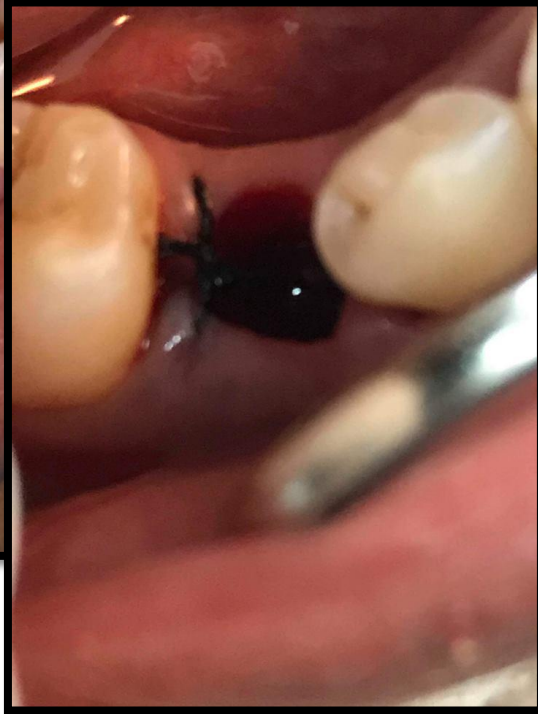

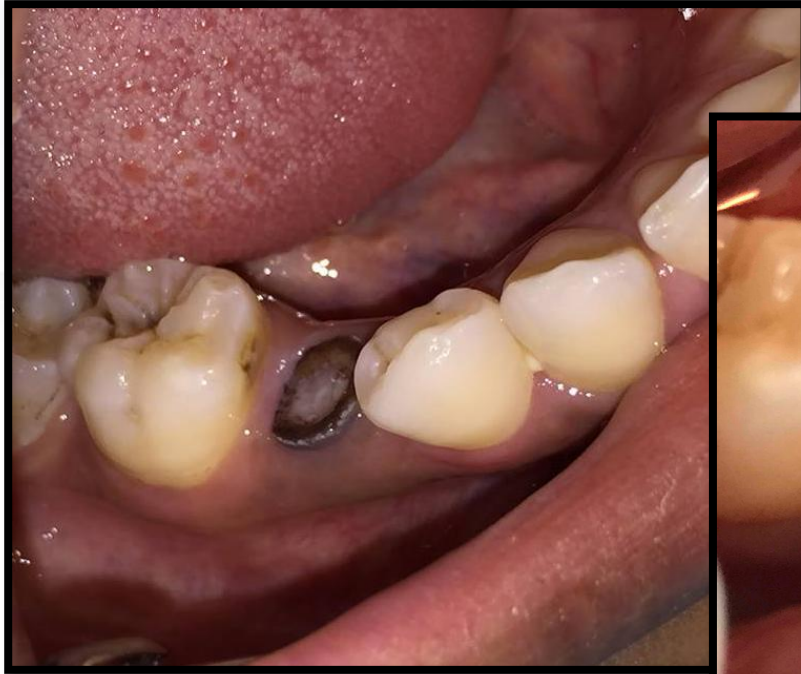
RR 28



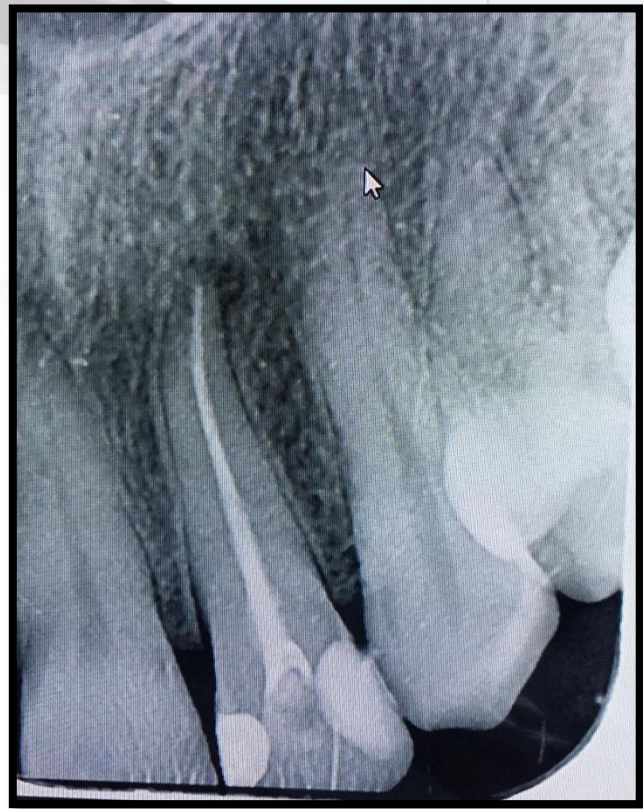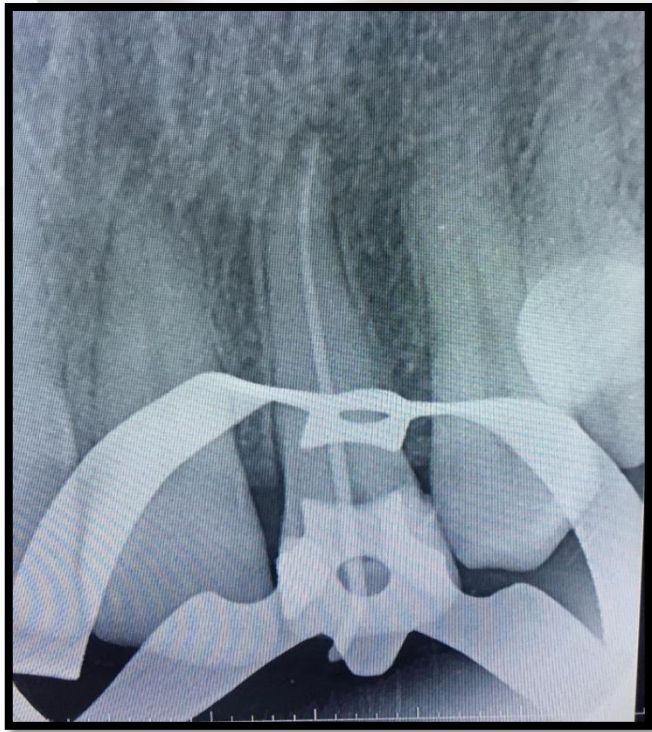
RR 38



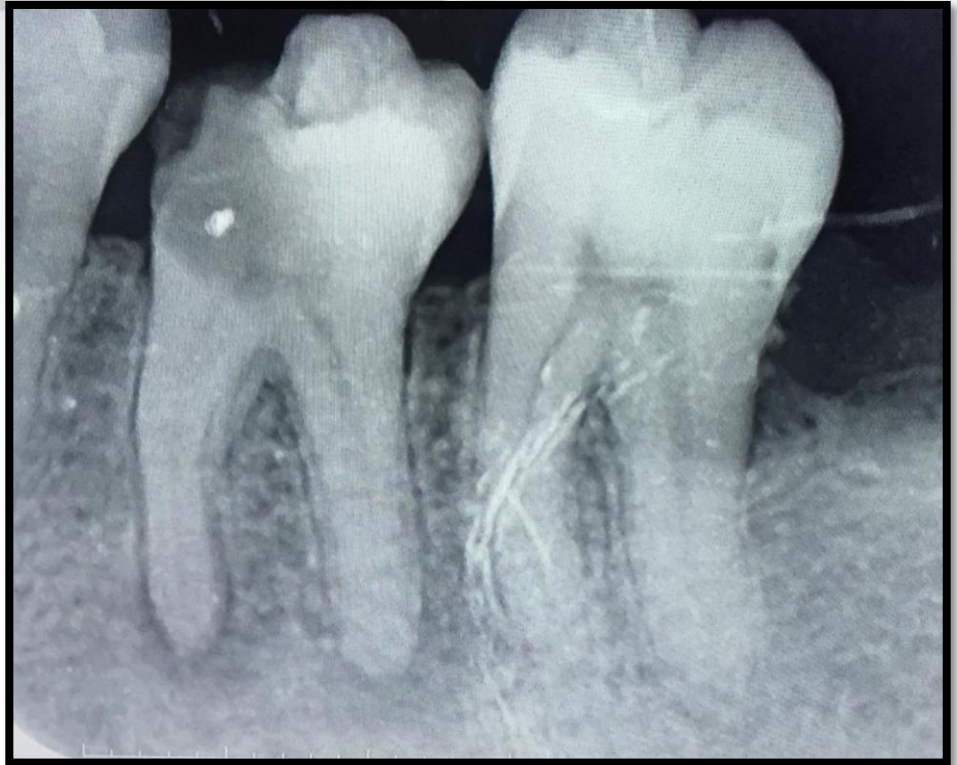
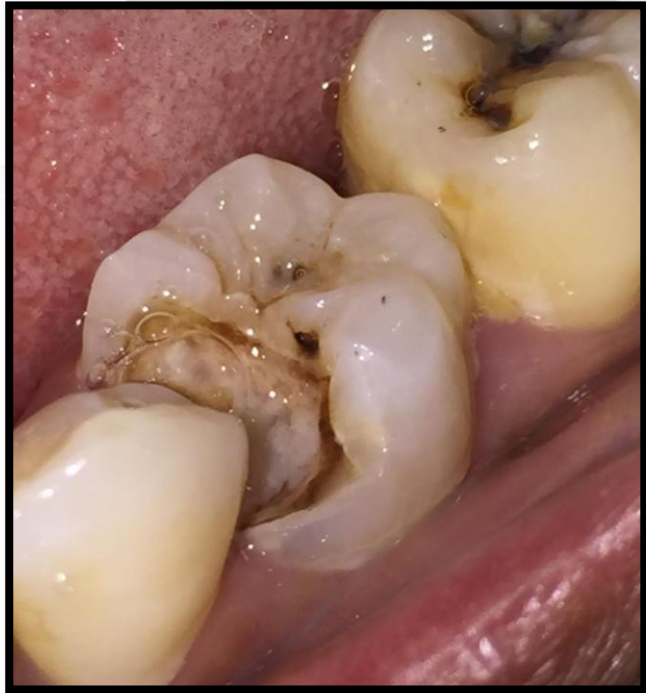
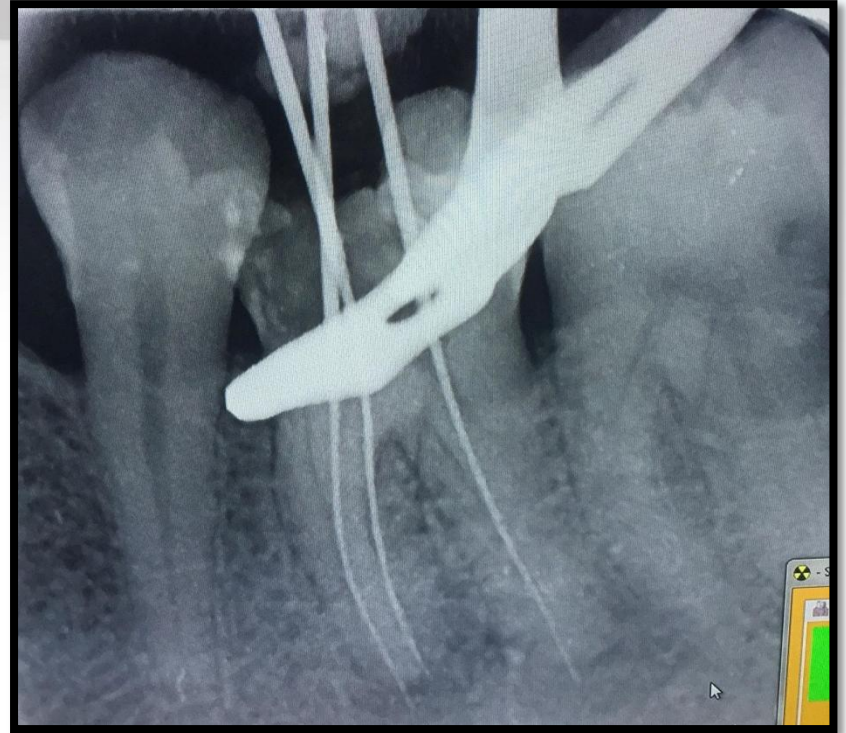
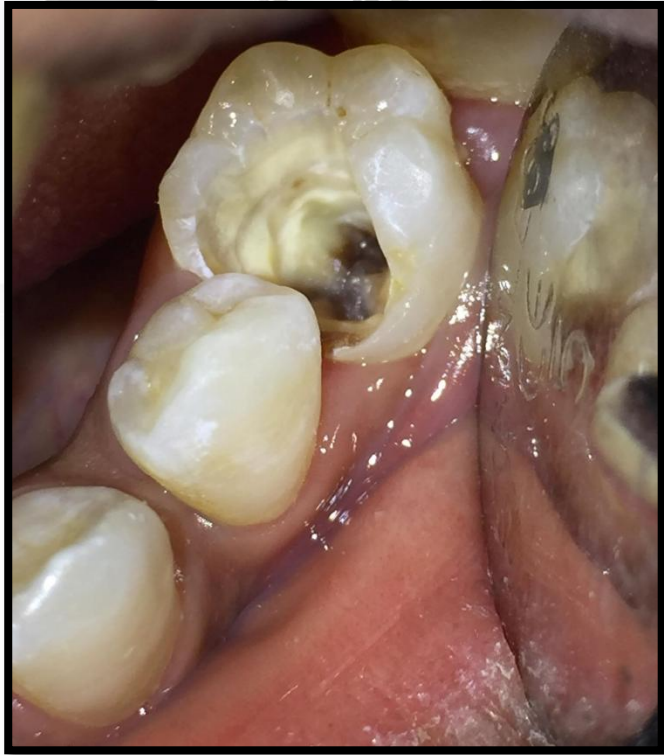RR 45

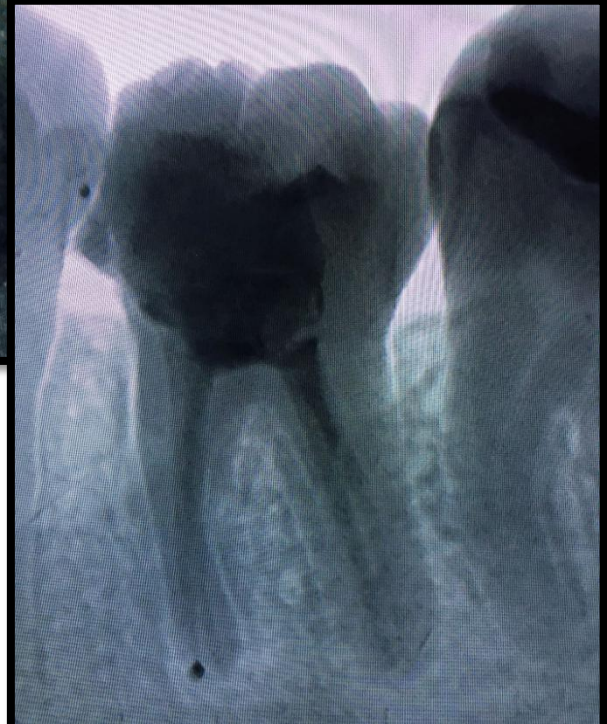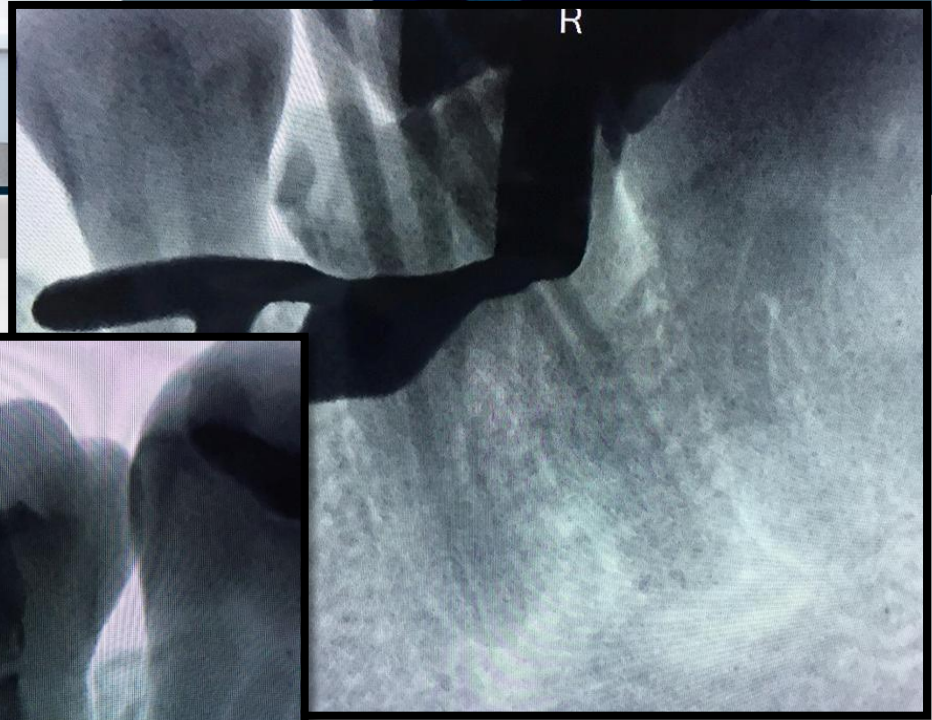
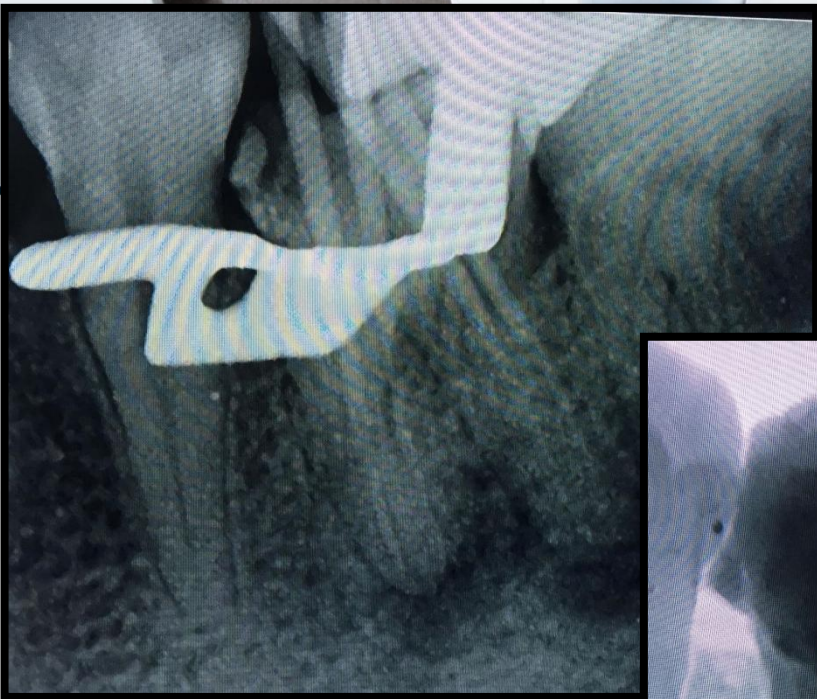
✓ RCT 22.



✓ RCT 36:

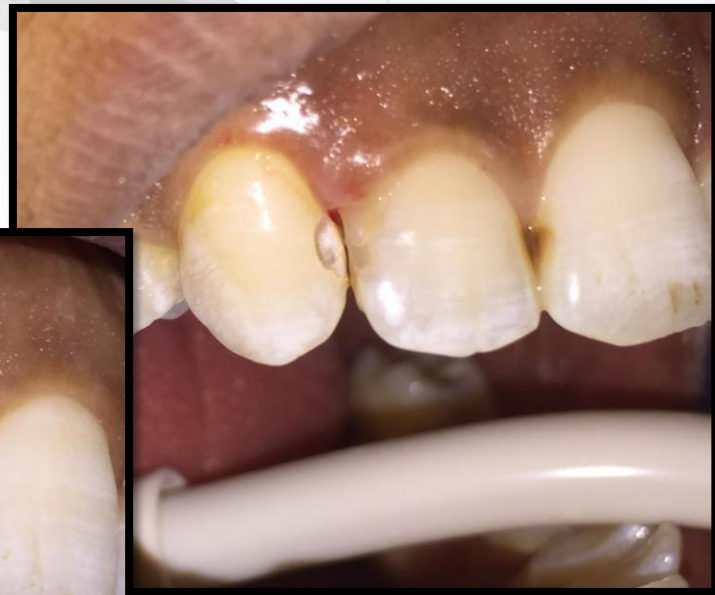
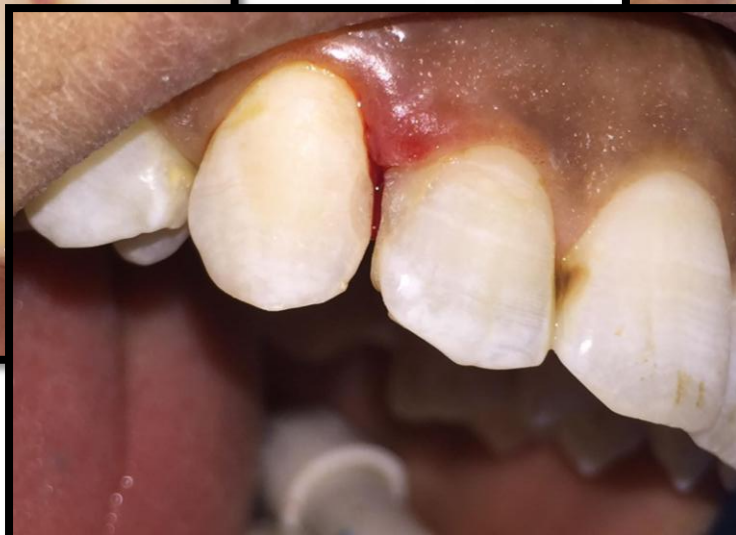
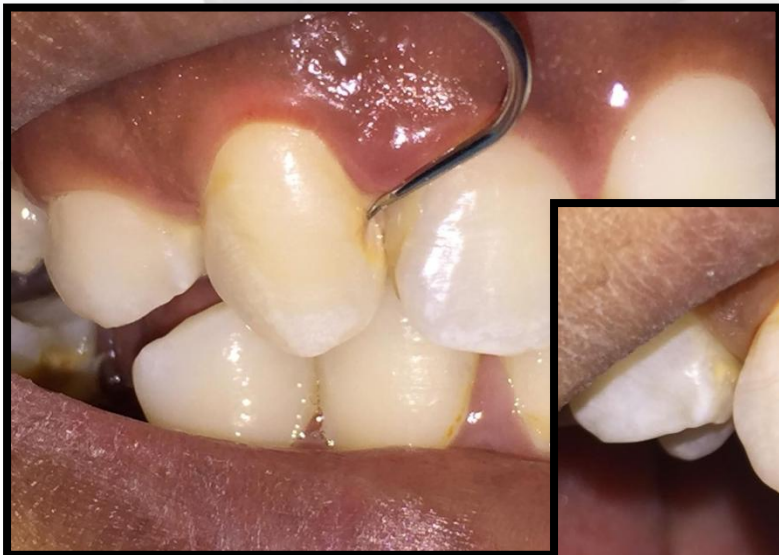



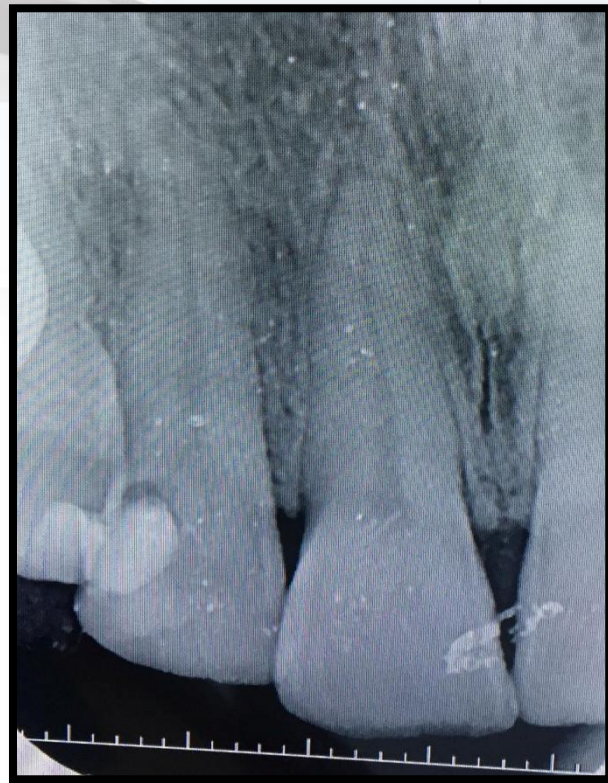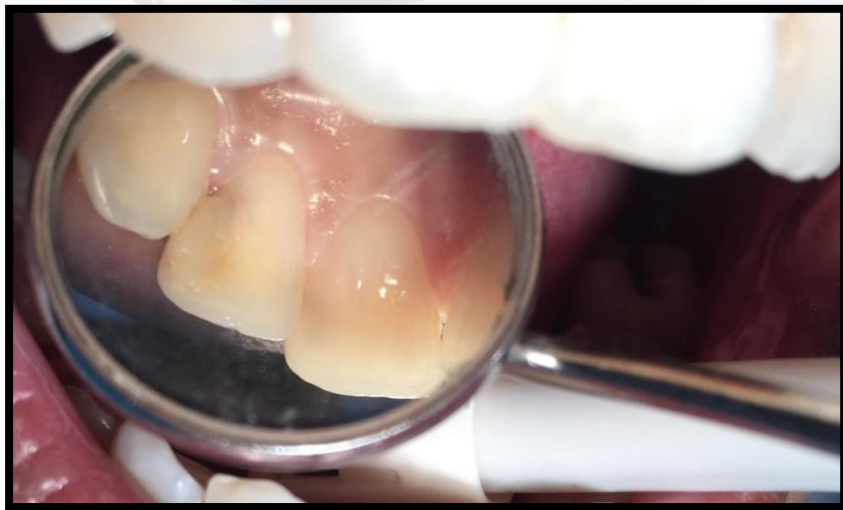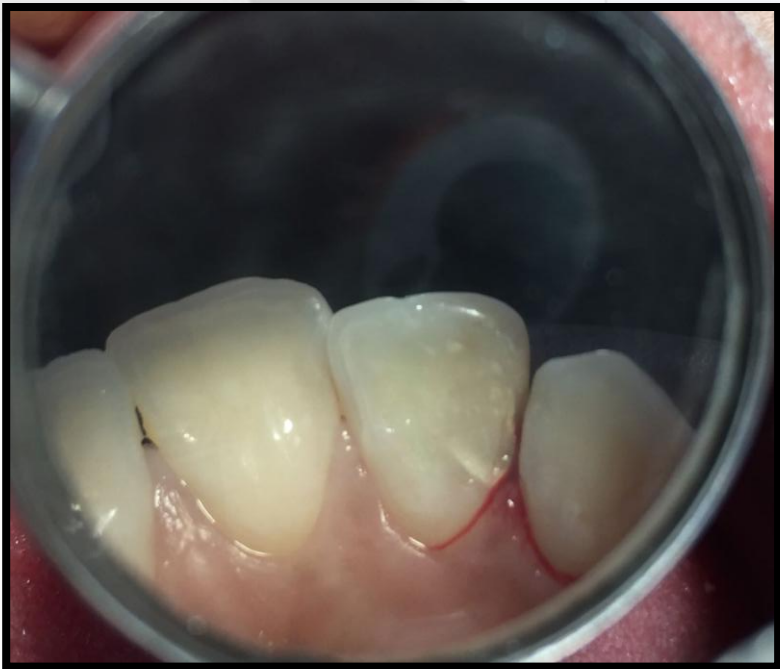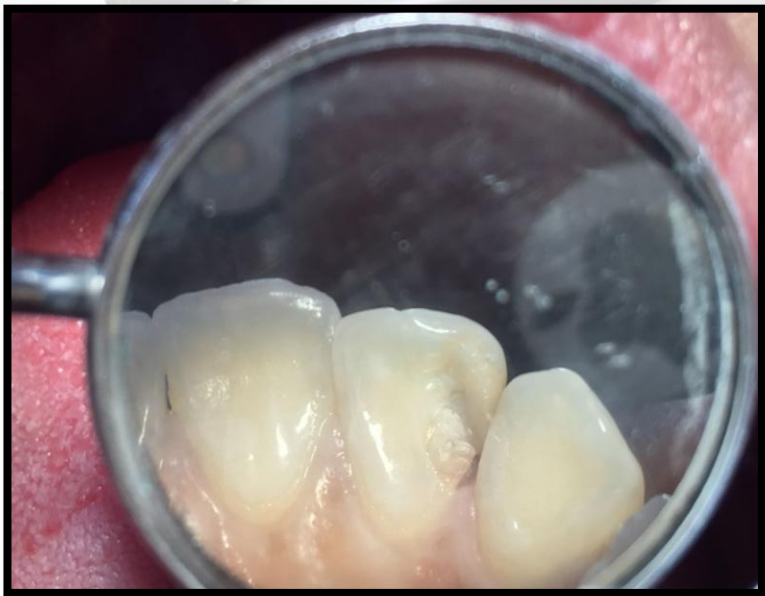Phase 3

✓ Class III composite restoration 13.

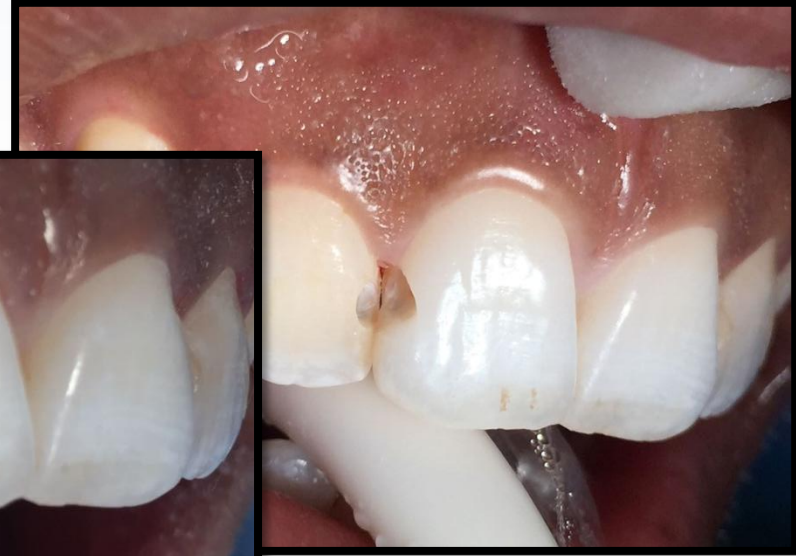
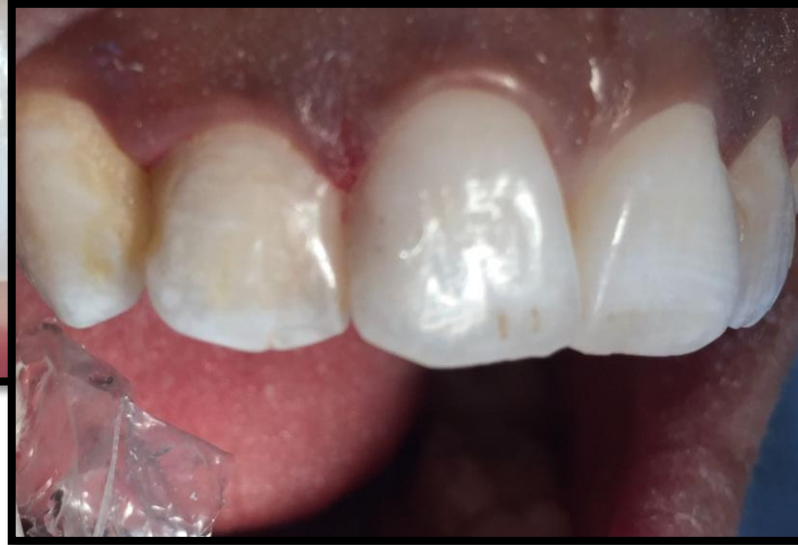
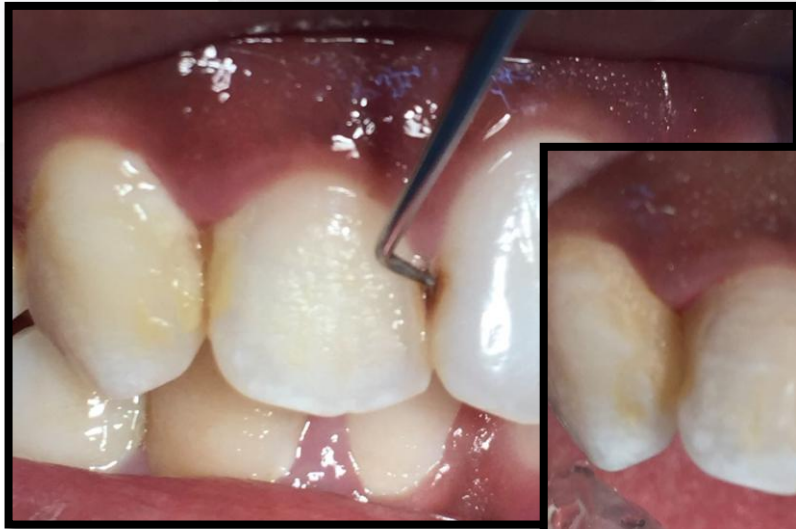✓ 12:

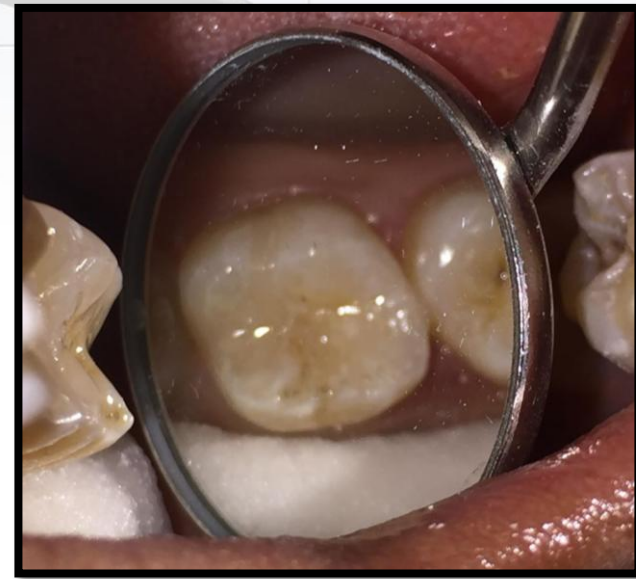
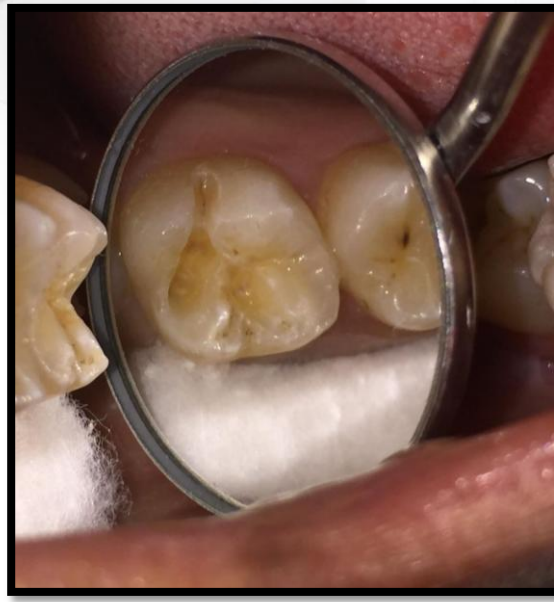
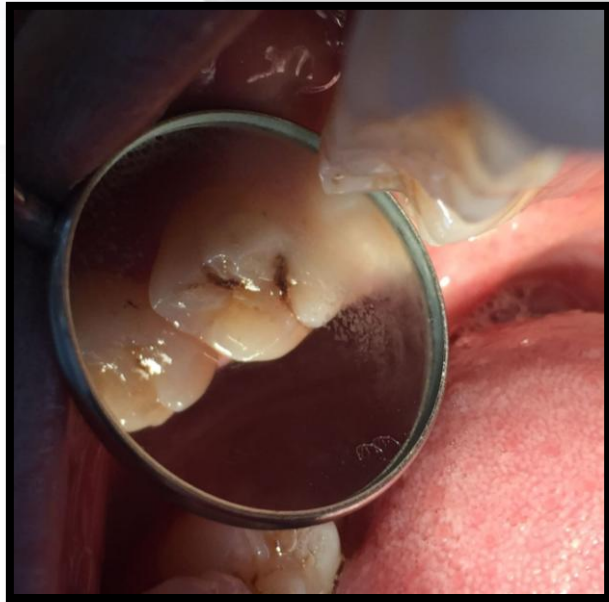

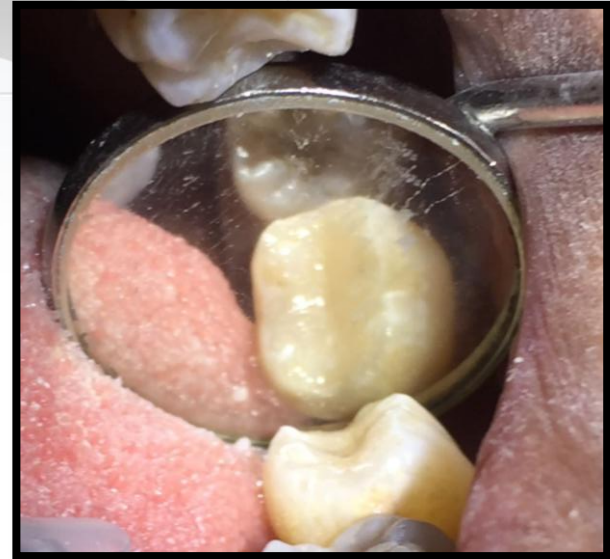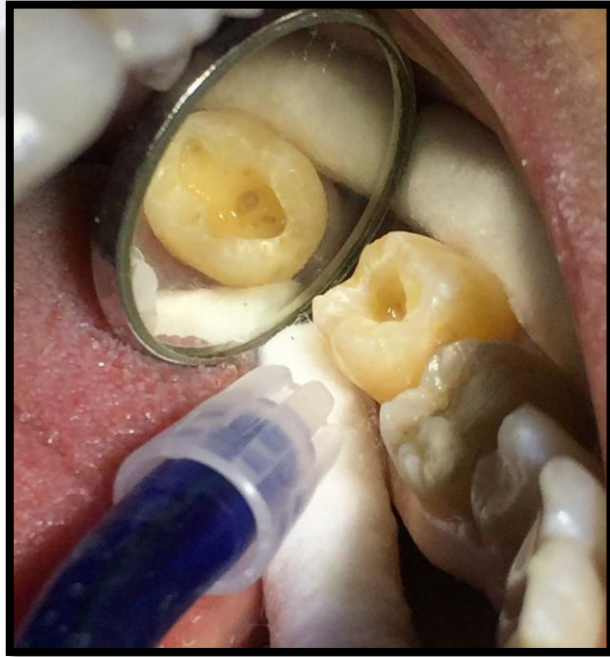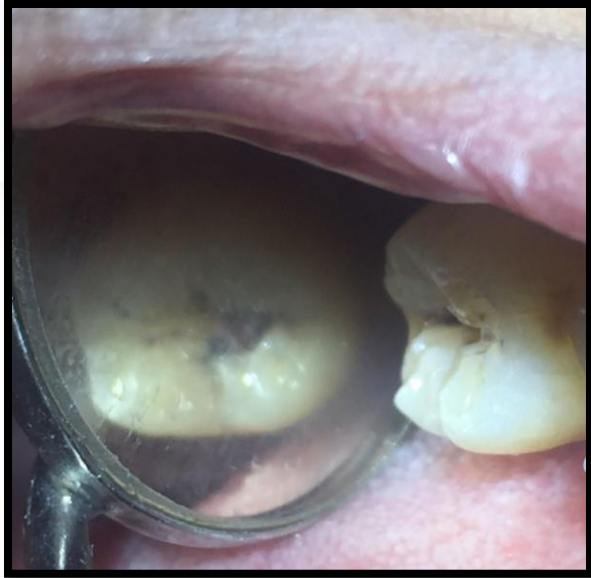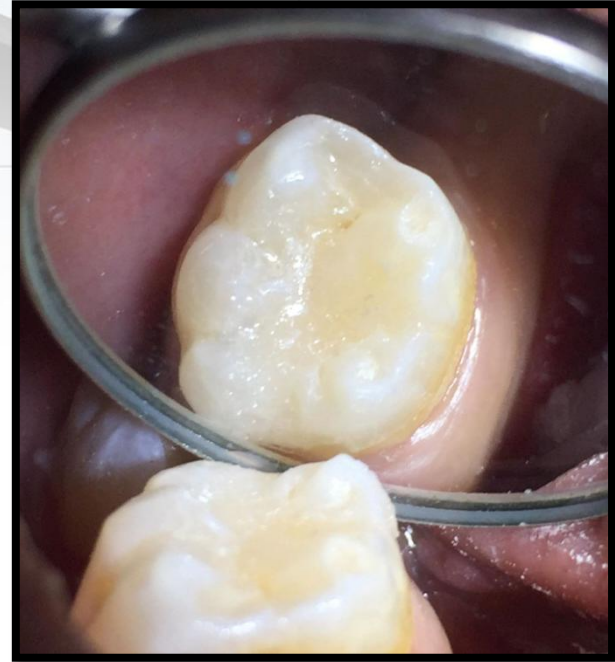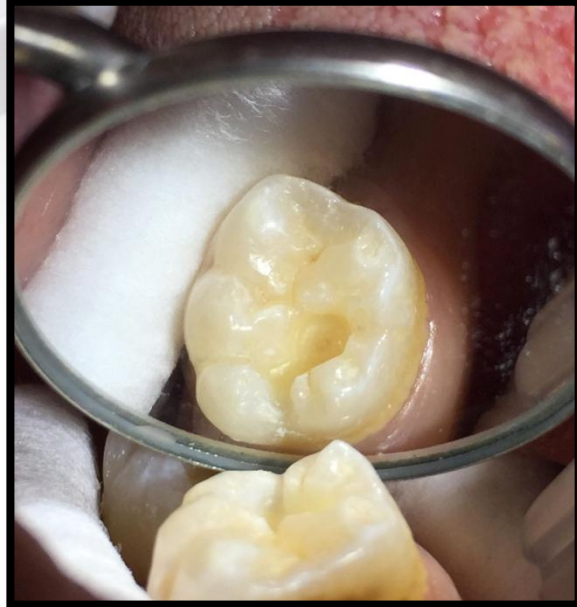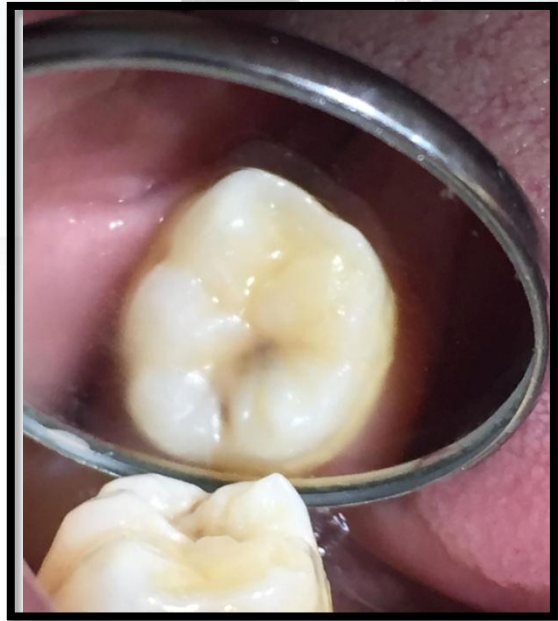✓ Class III composite restoration 11,12&21:



✓ Class I composite restoration 17,37 &46:

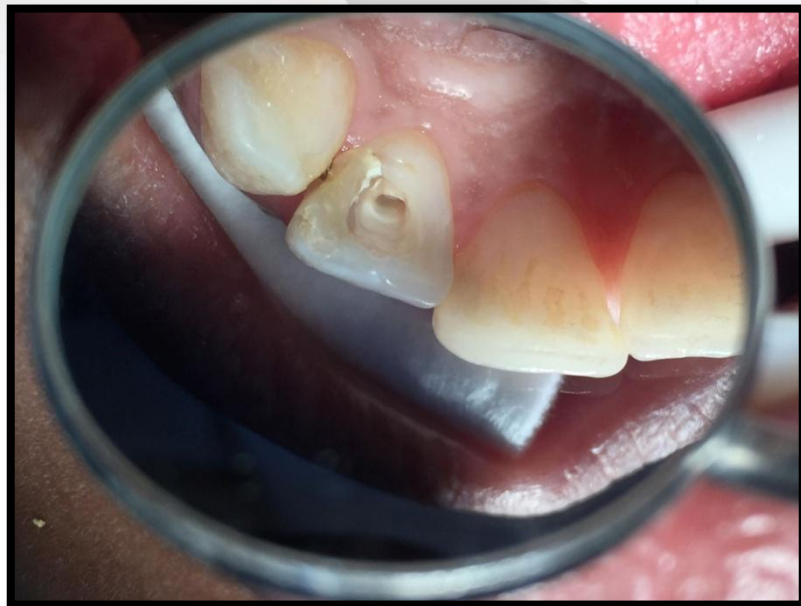
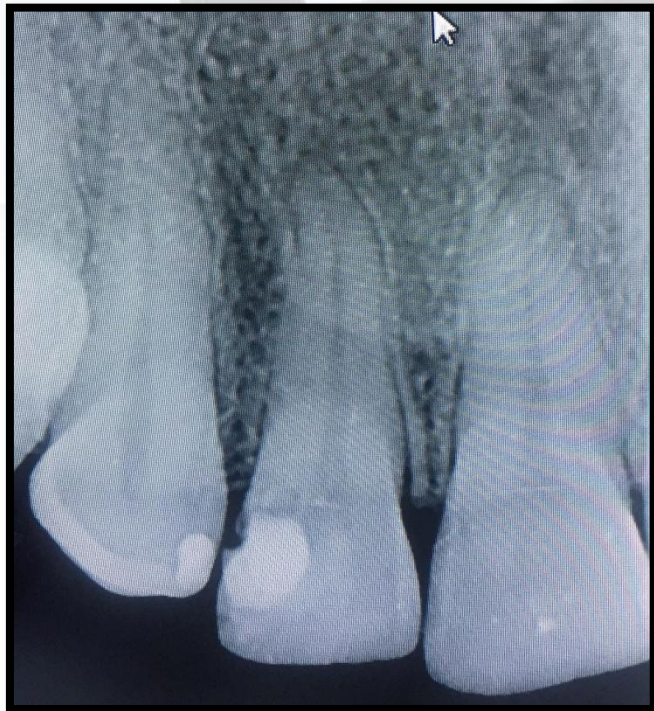
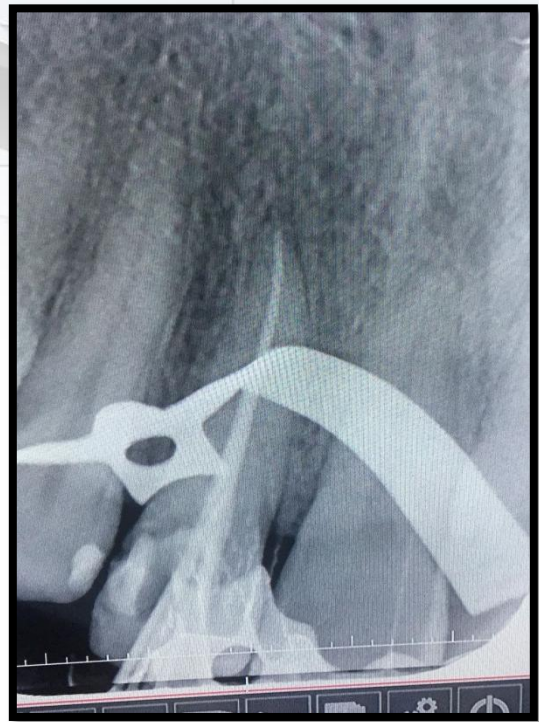
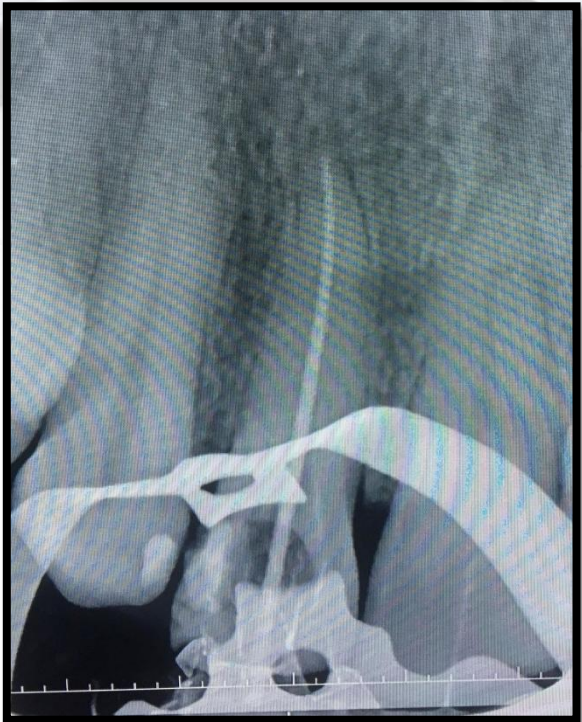
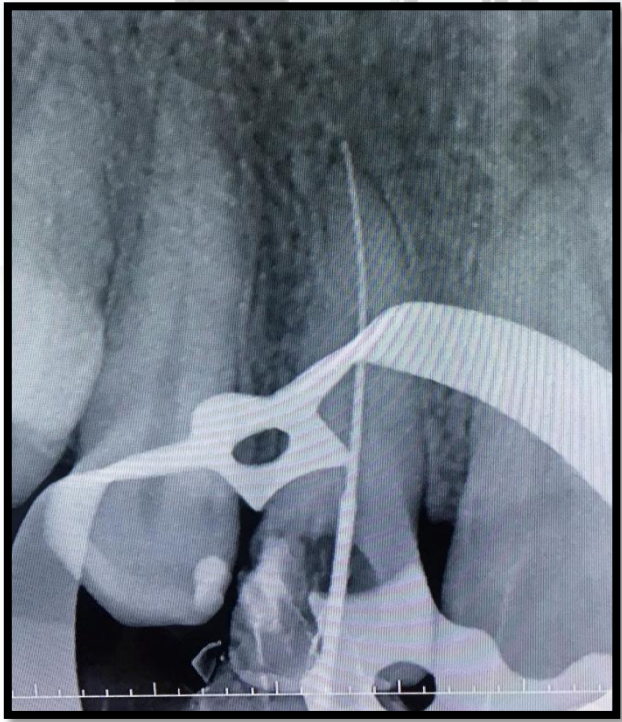




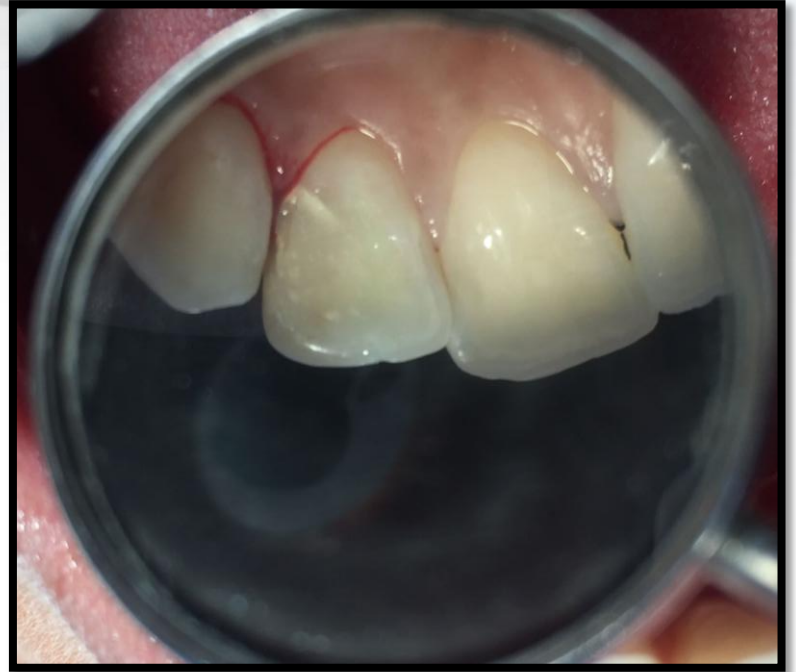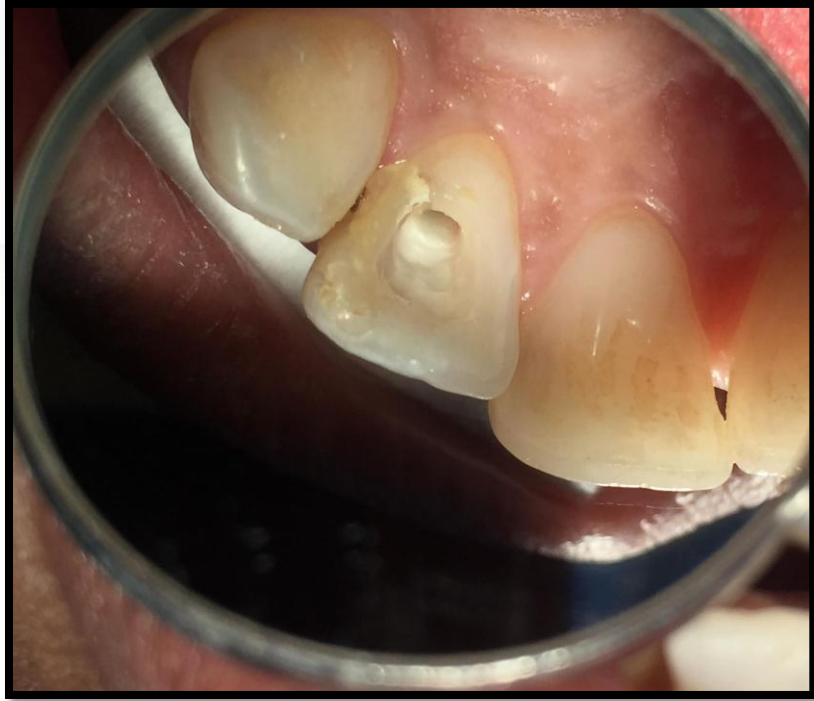Emergency phase

✓ 12:

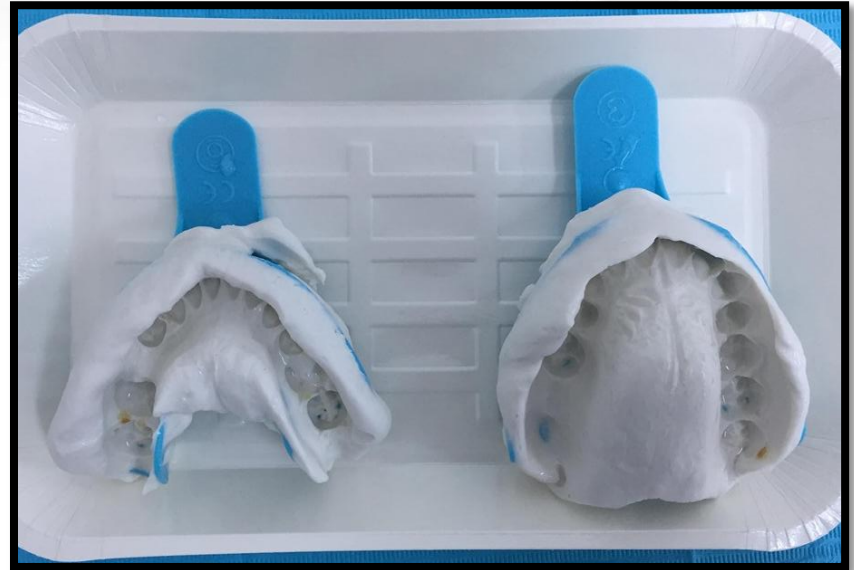




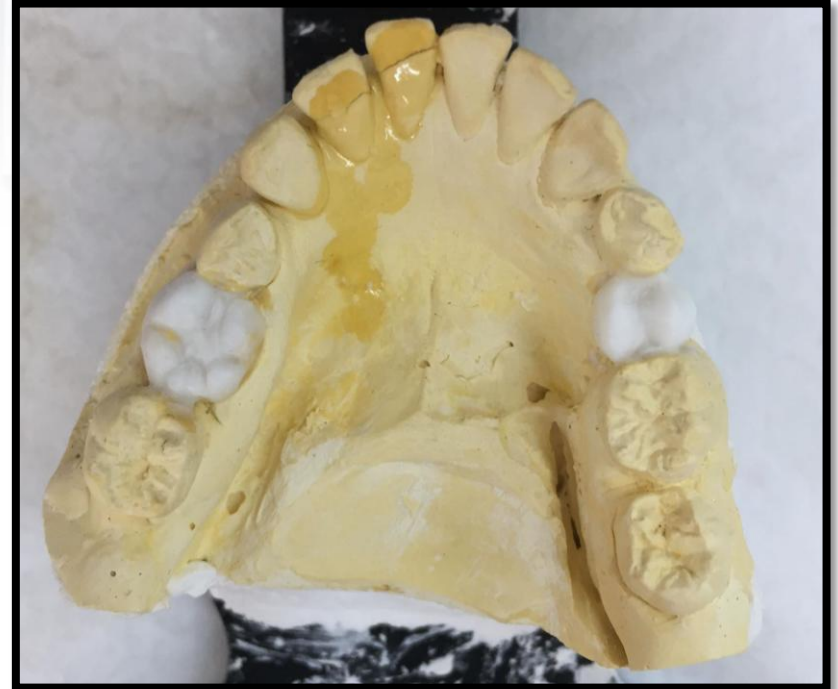
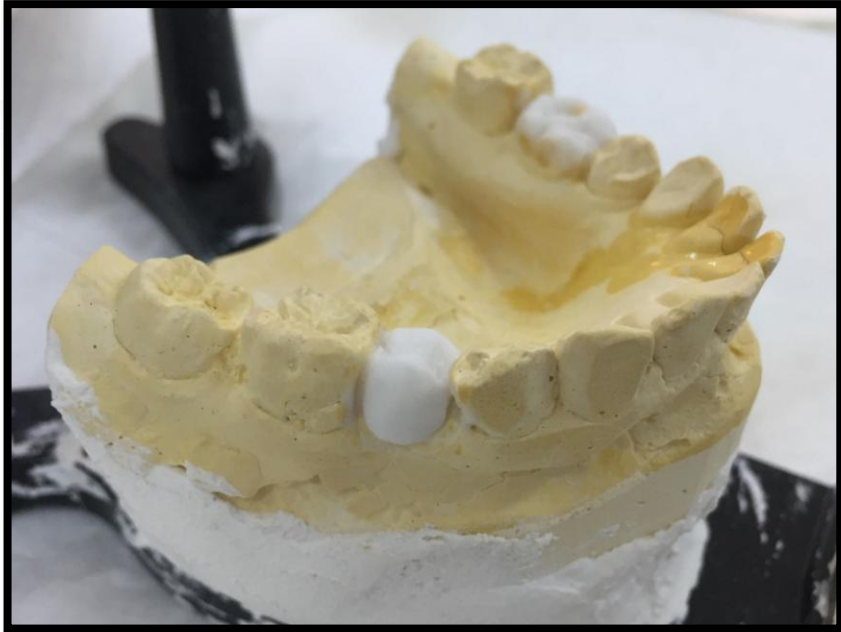
✓ Final restoration of 22 & 36:

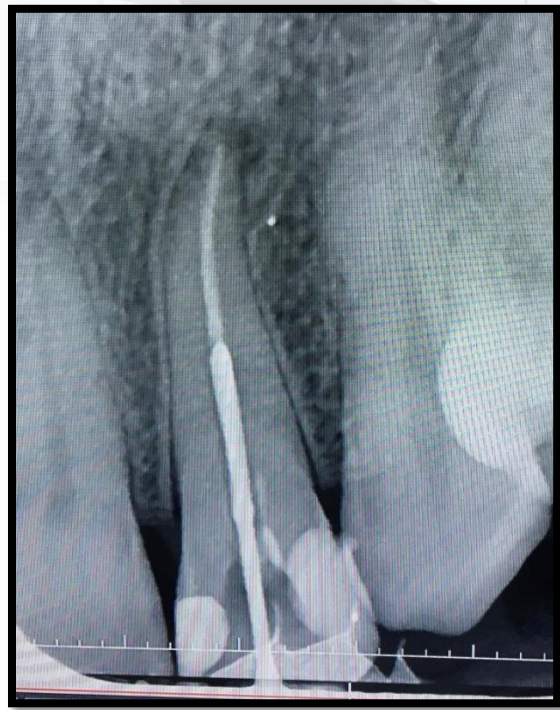
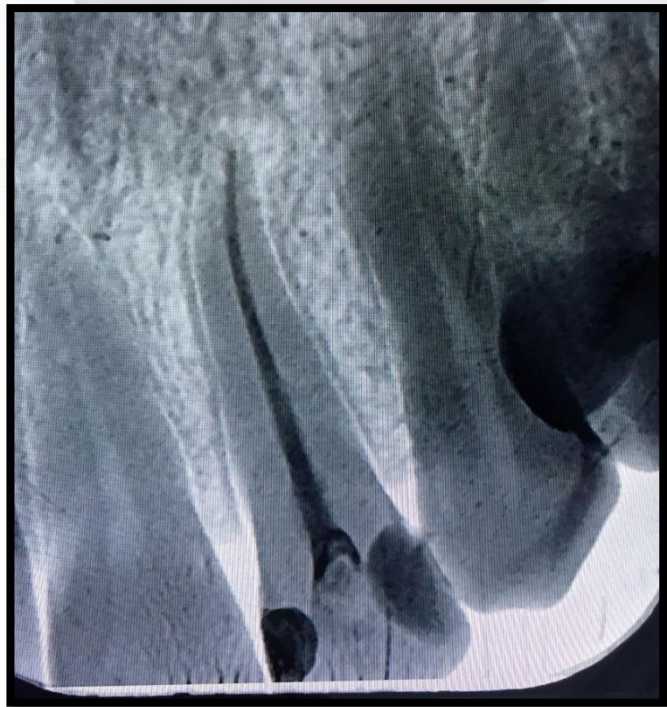1. Primary impression:

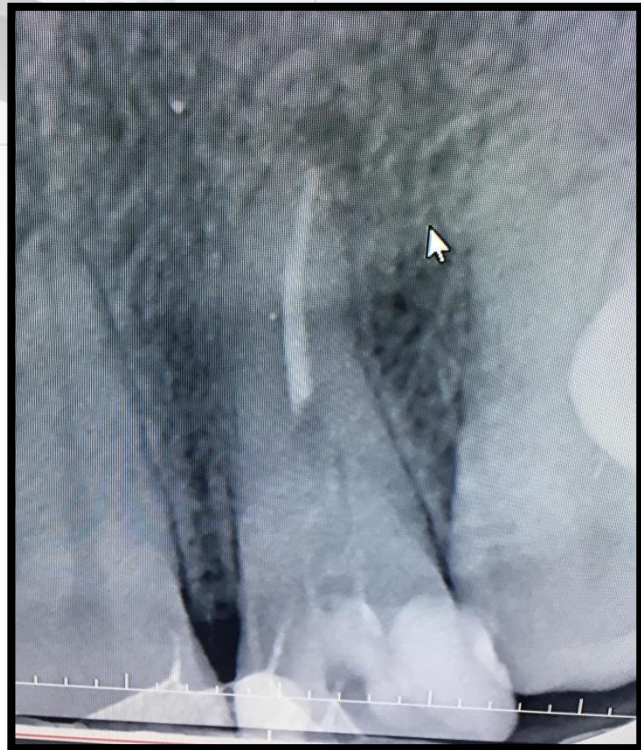
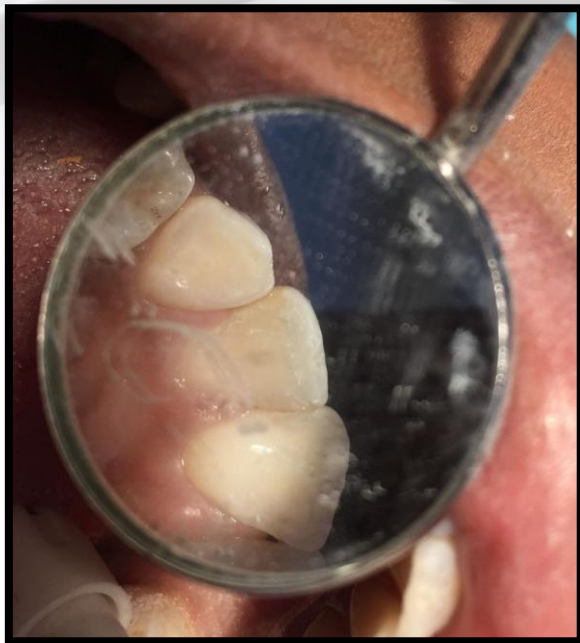


2. Study cast with wax up:

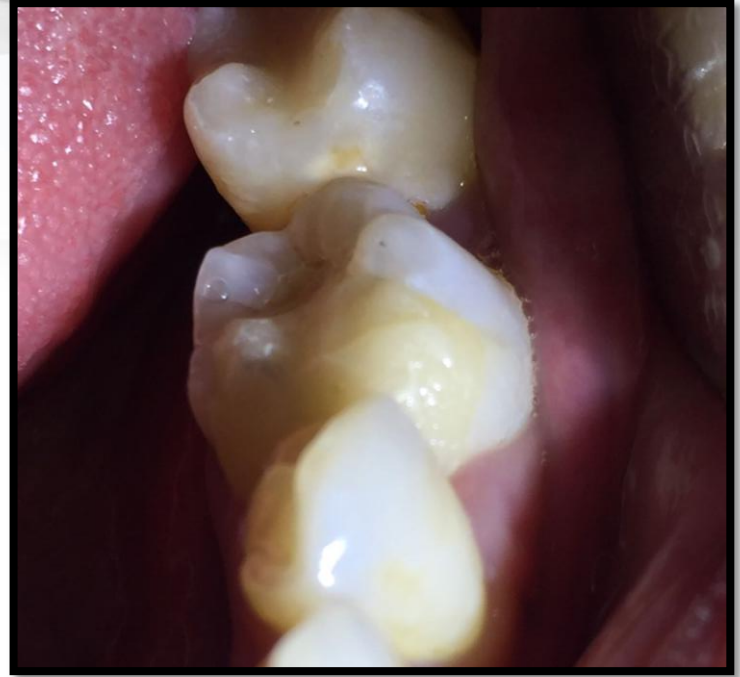
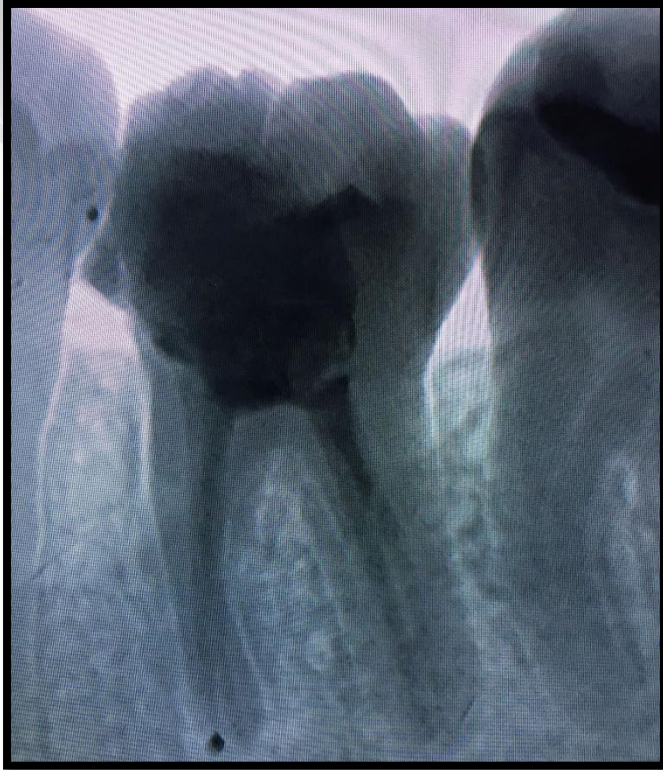
✓ 22:

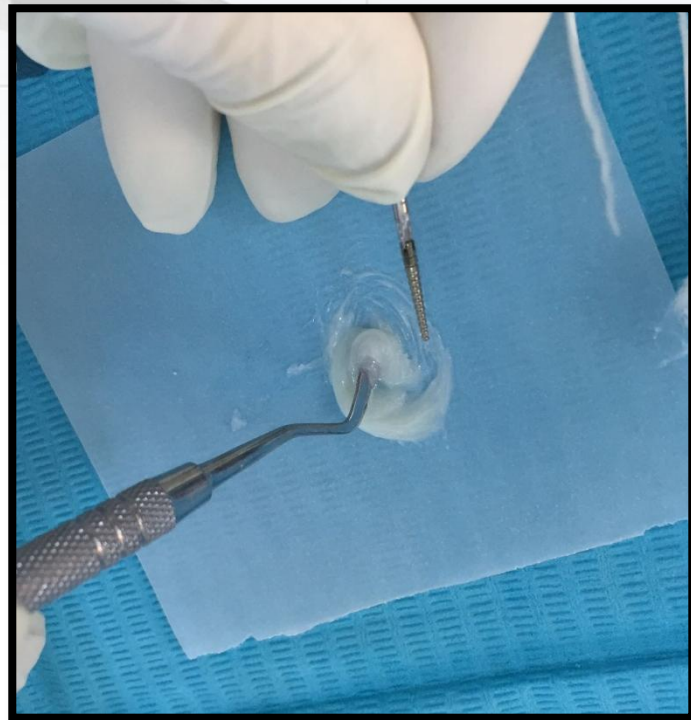
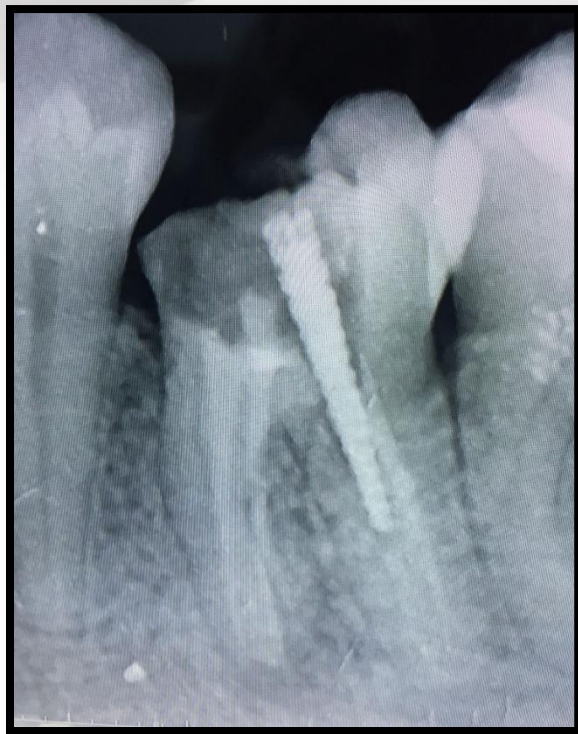


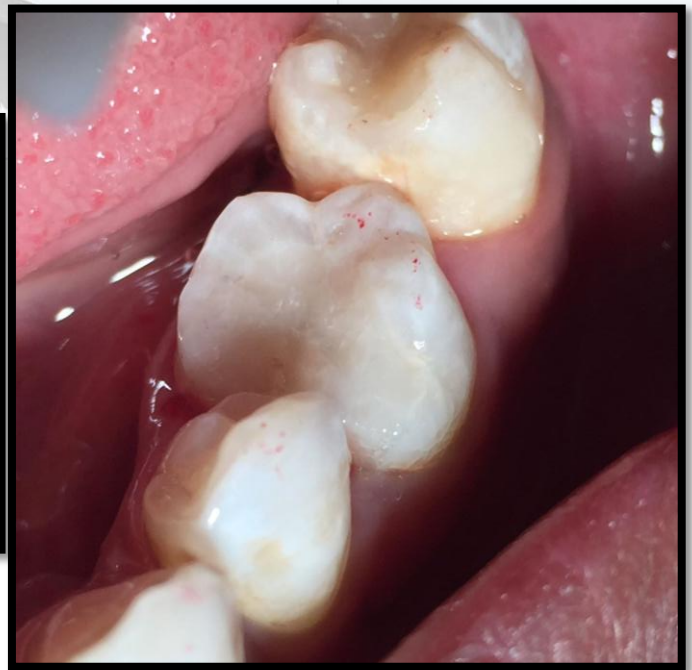
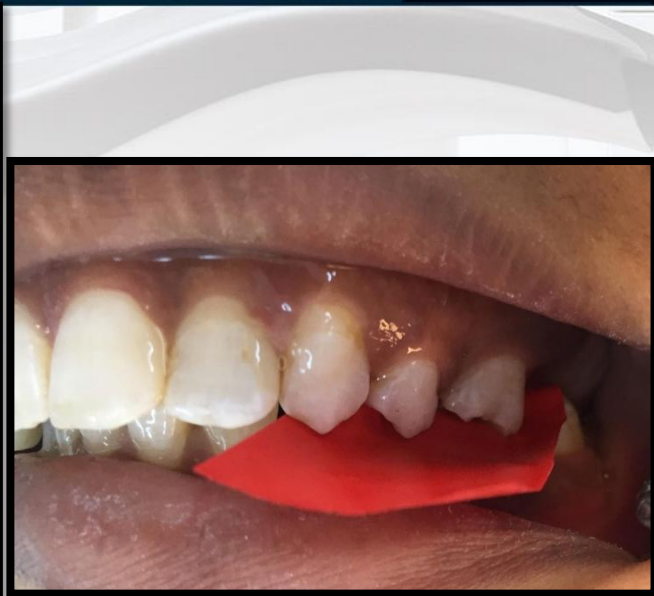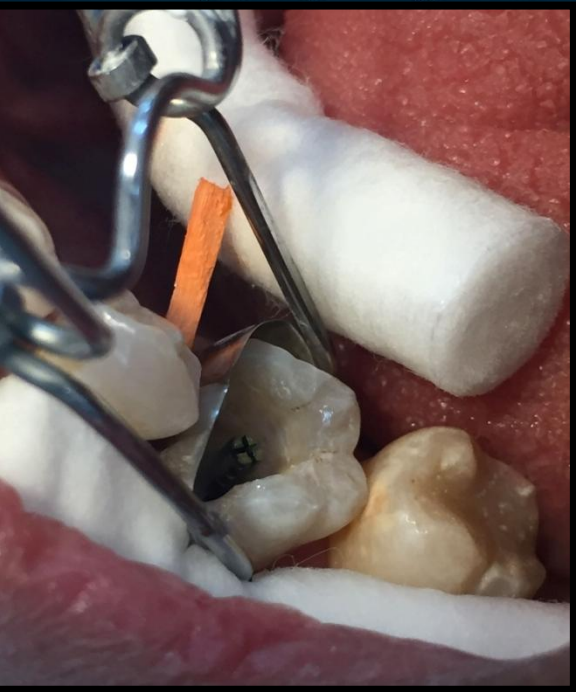✓ 36:

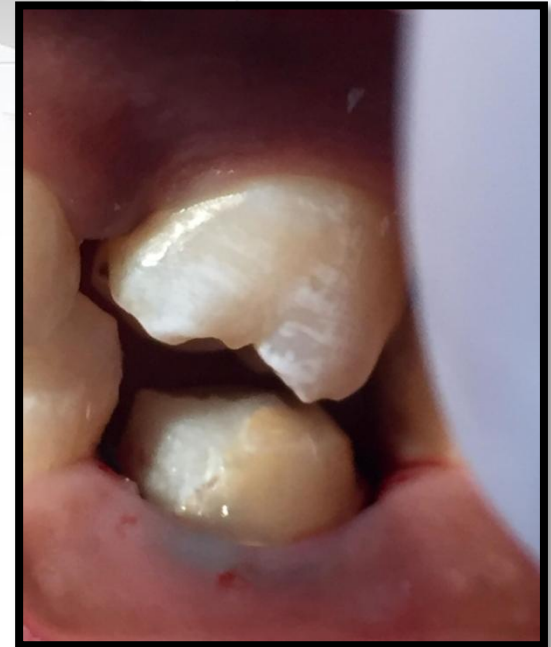
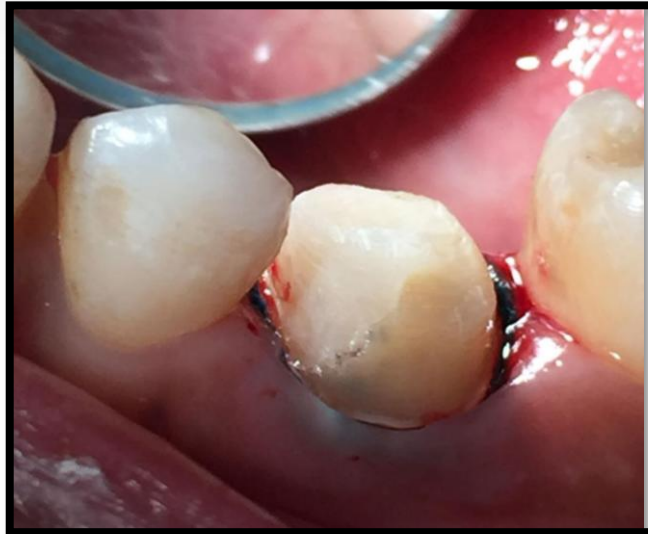
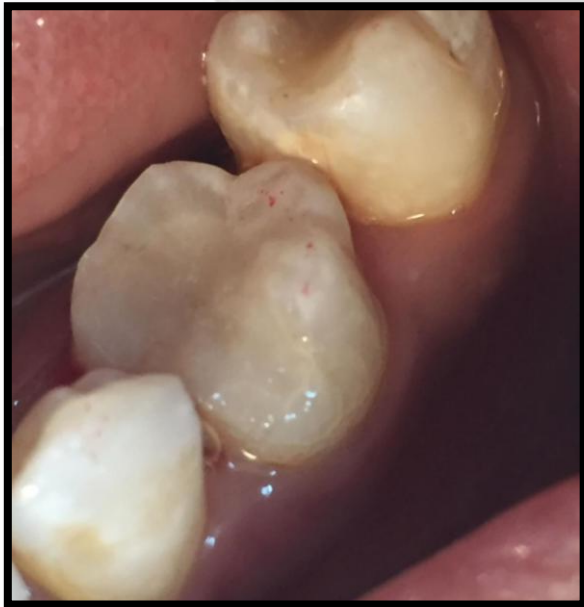1. Post preparation:

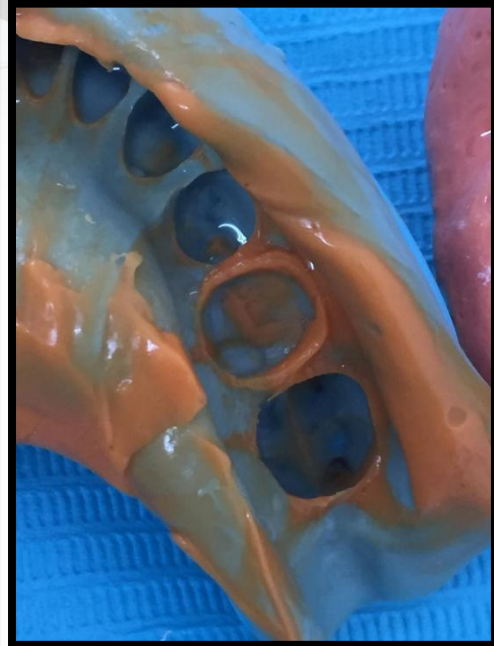
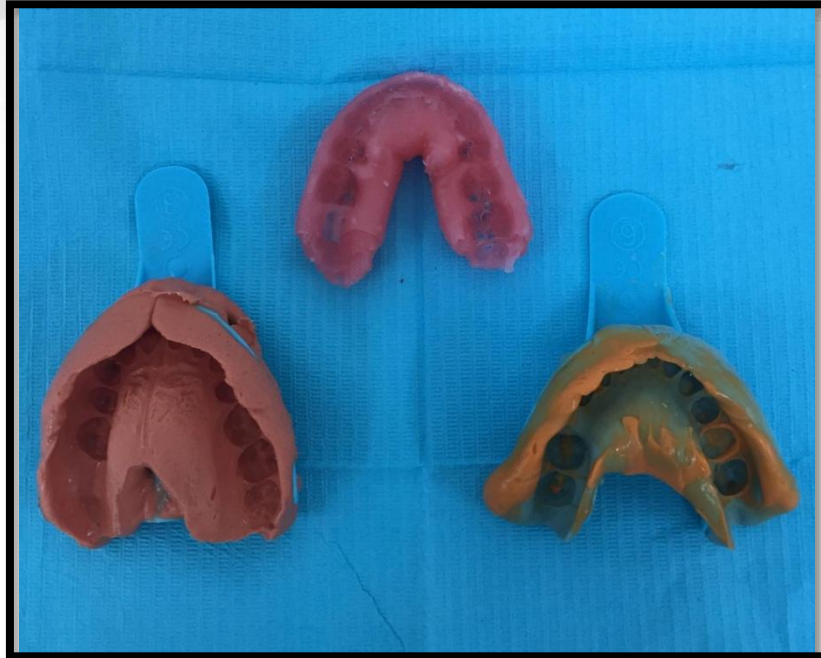
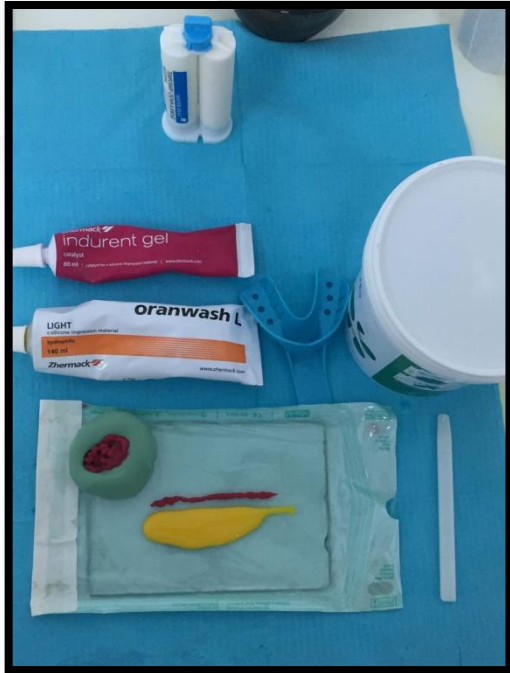





2. Tooth preparation :

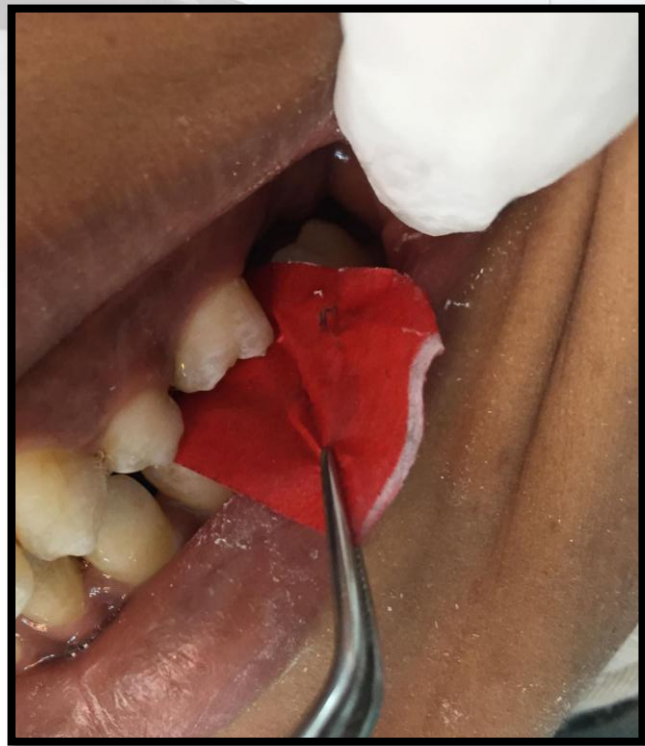
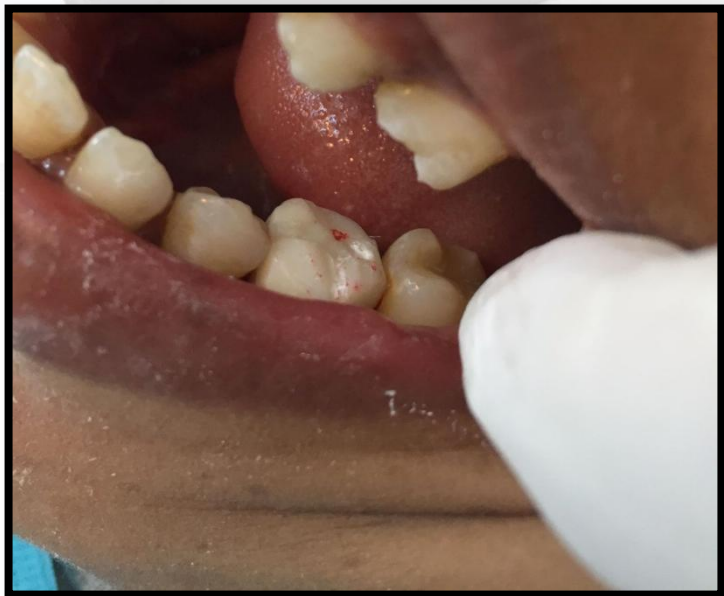

3. final impression:

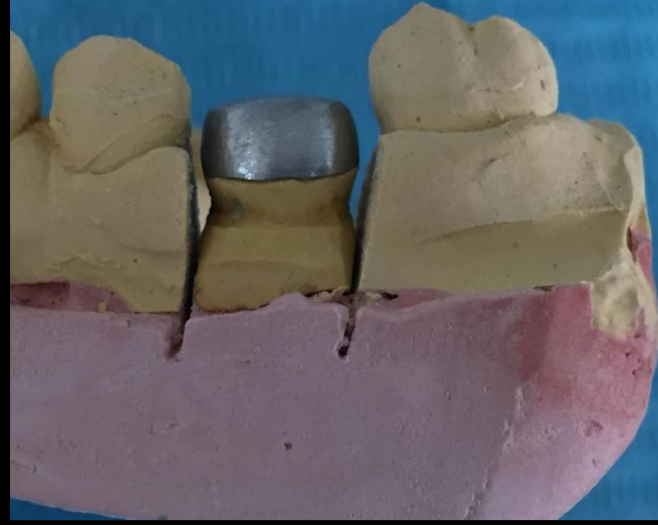
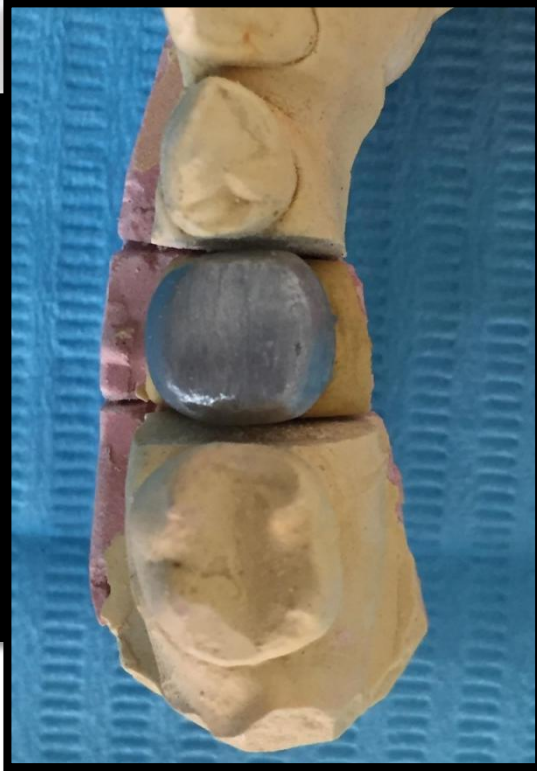
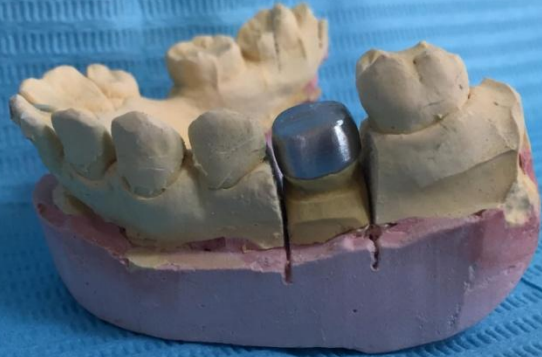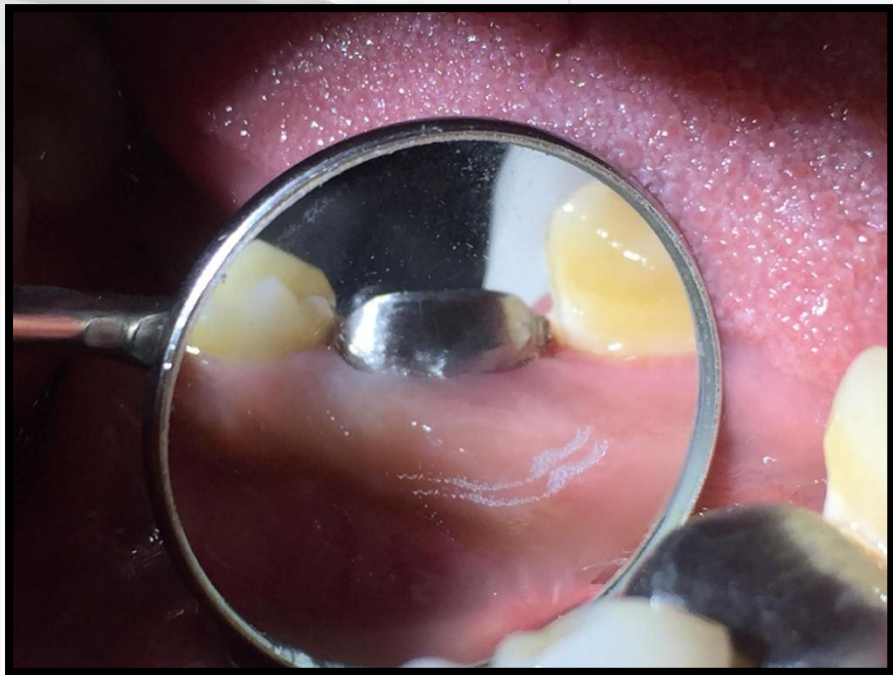4. Temporary crown:

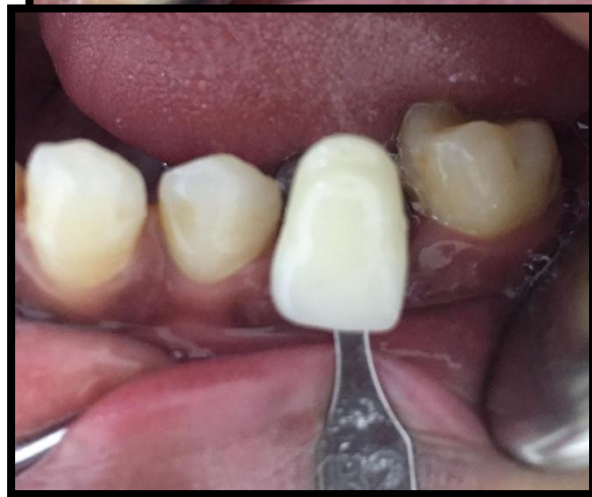
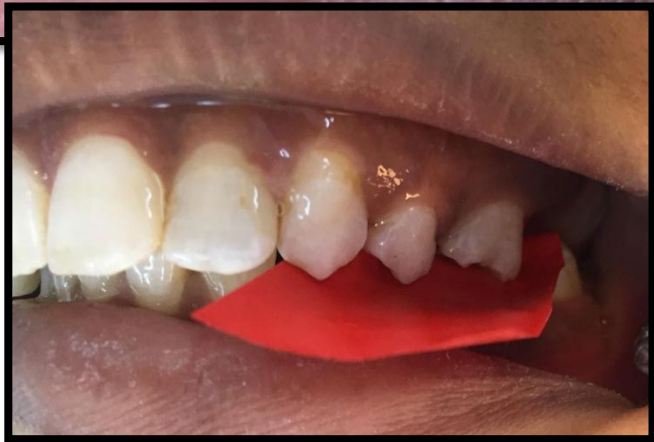
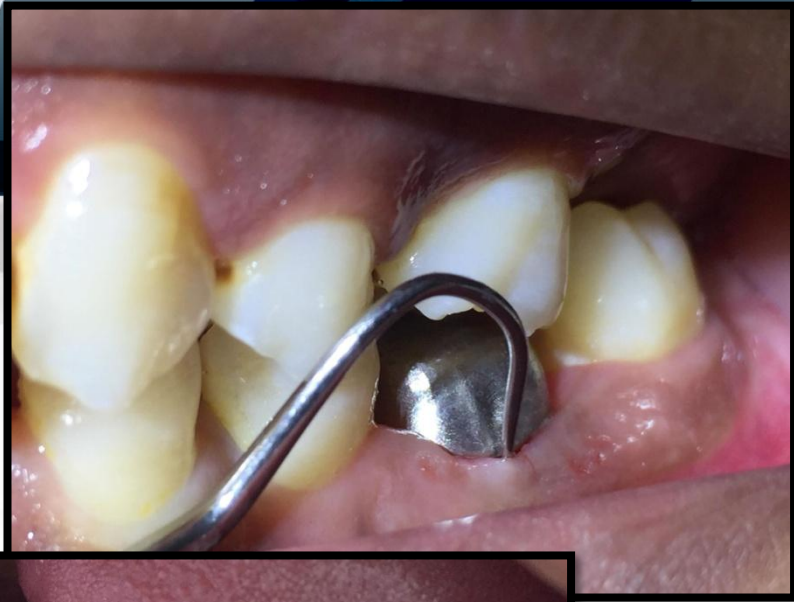
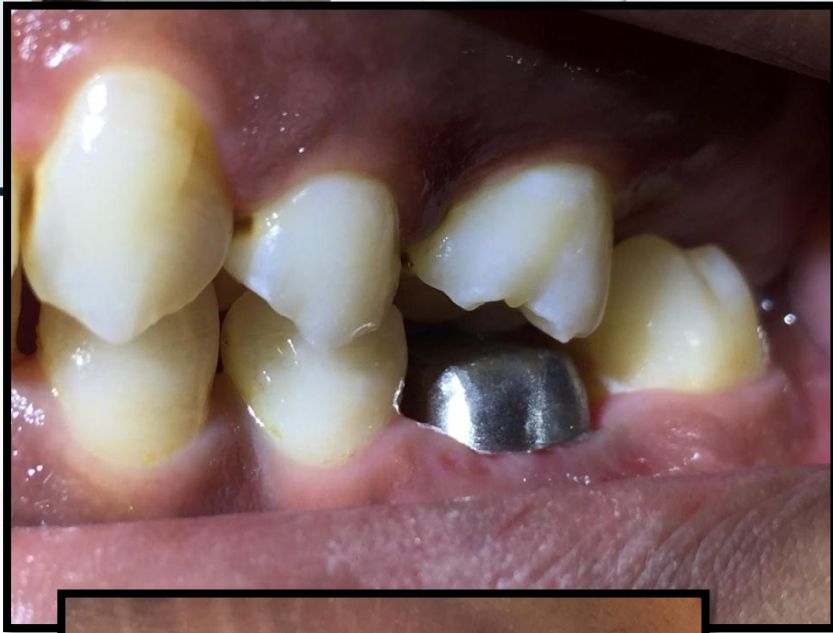
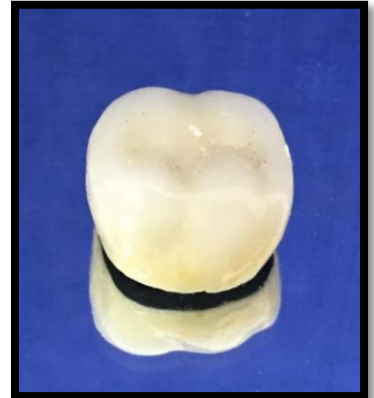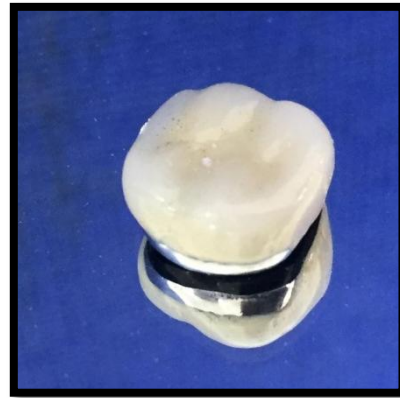
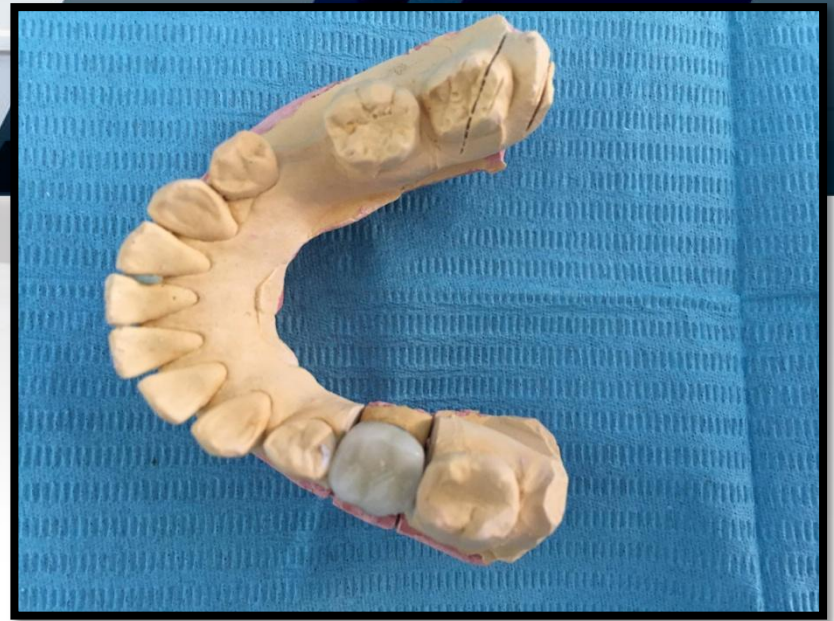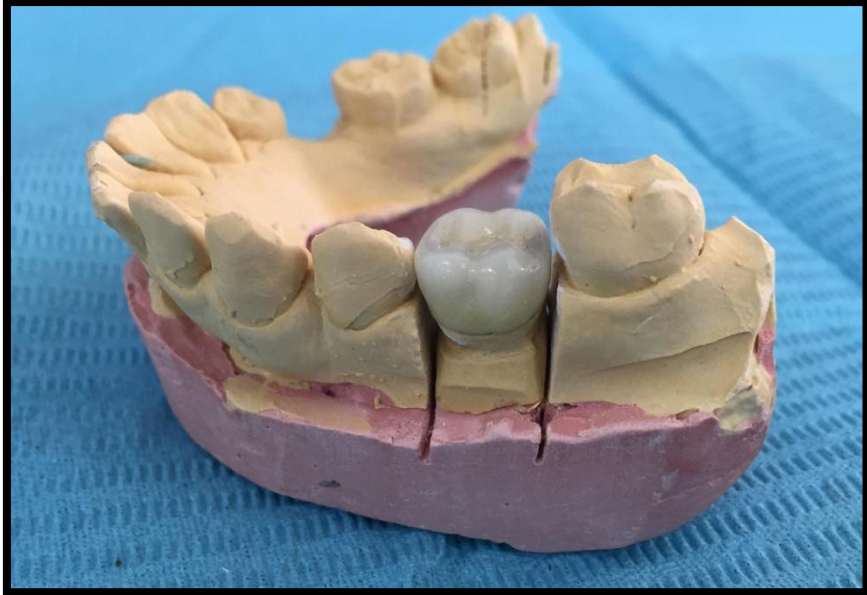5. Metal try-in :



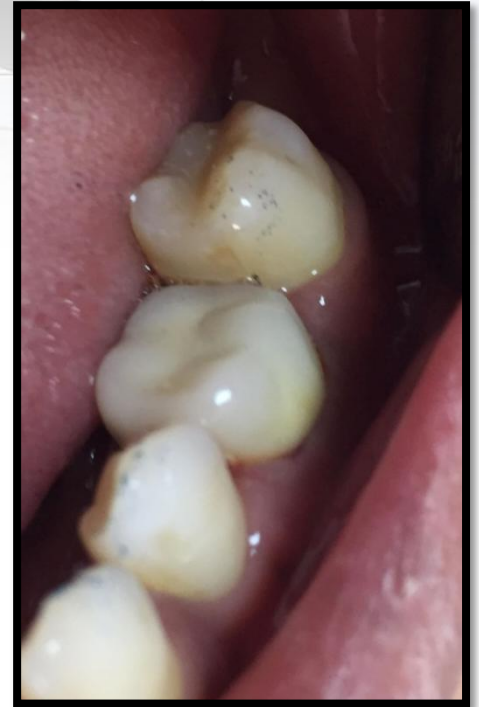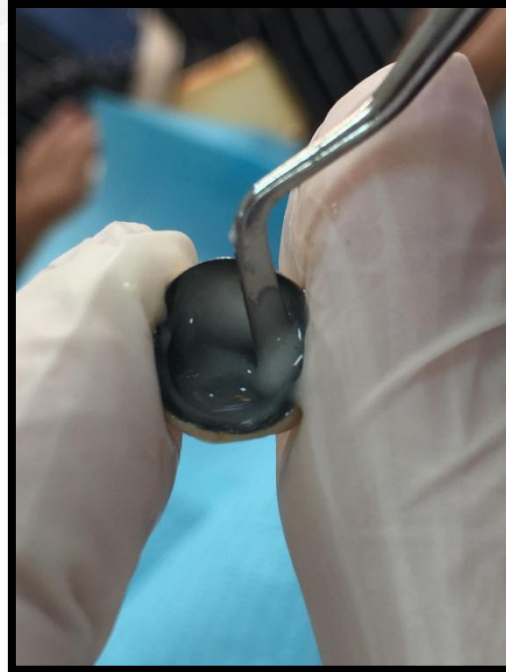

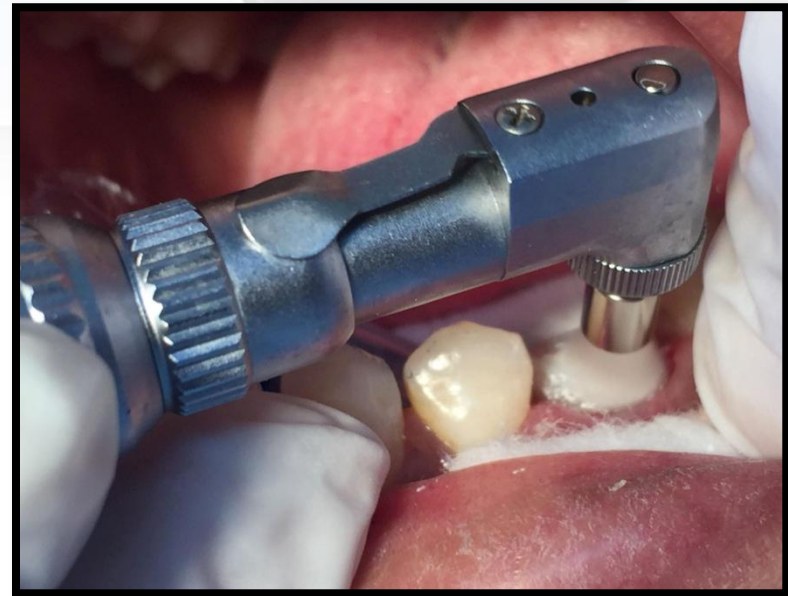
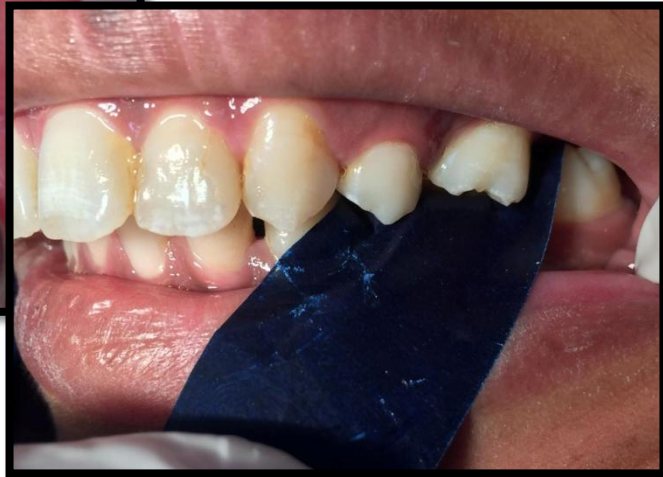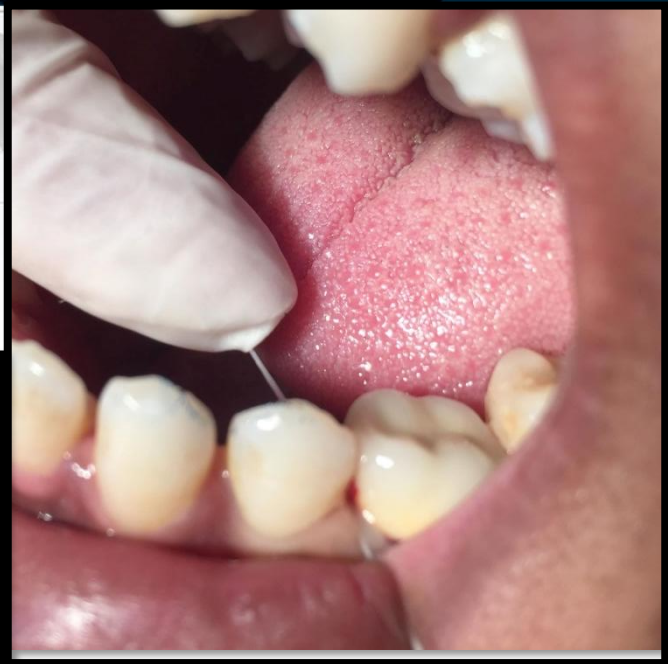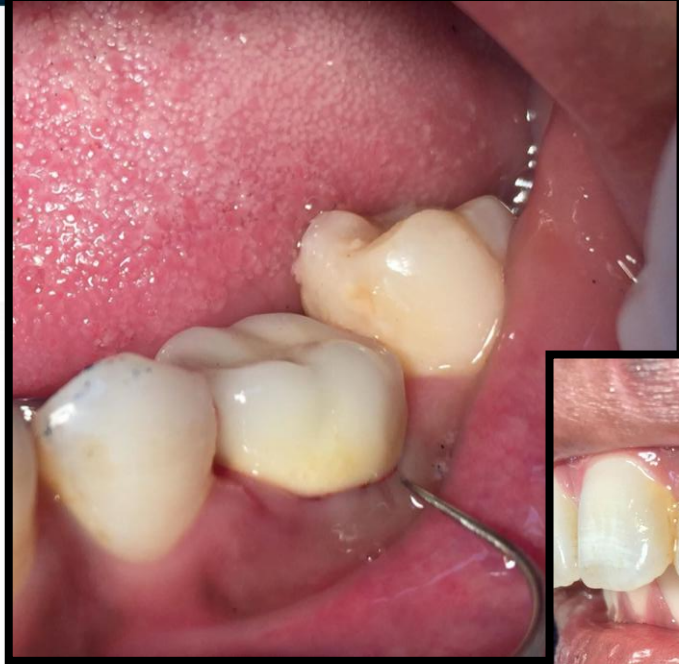


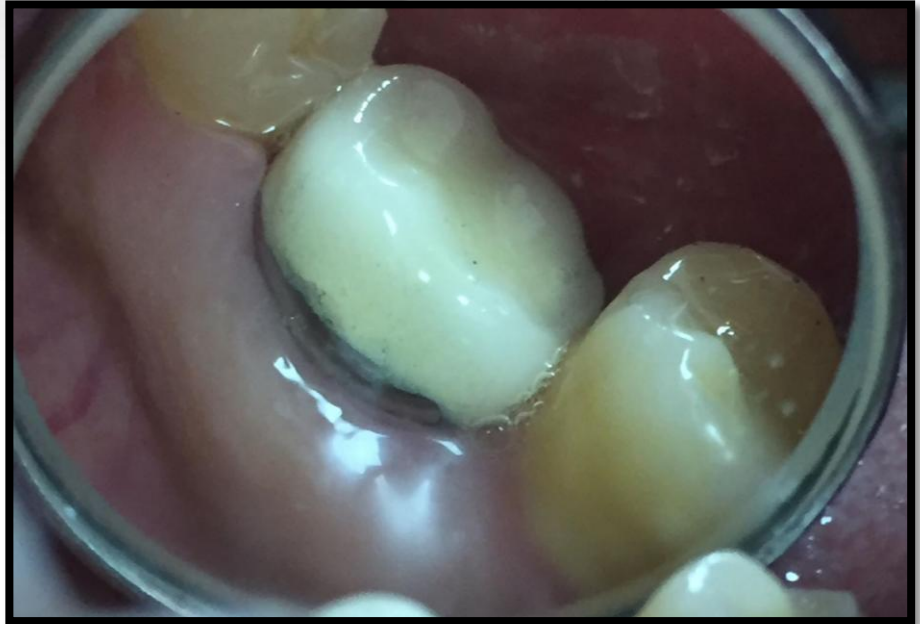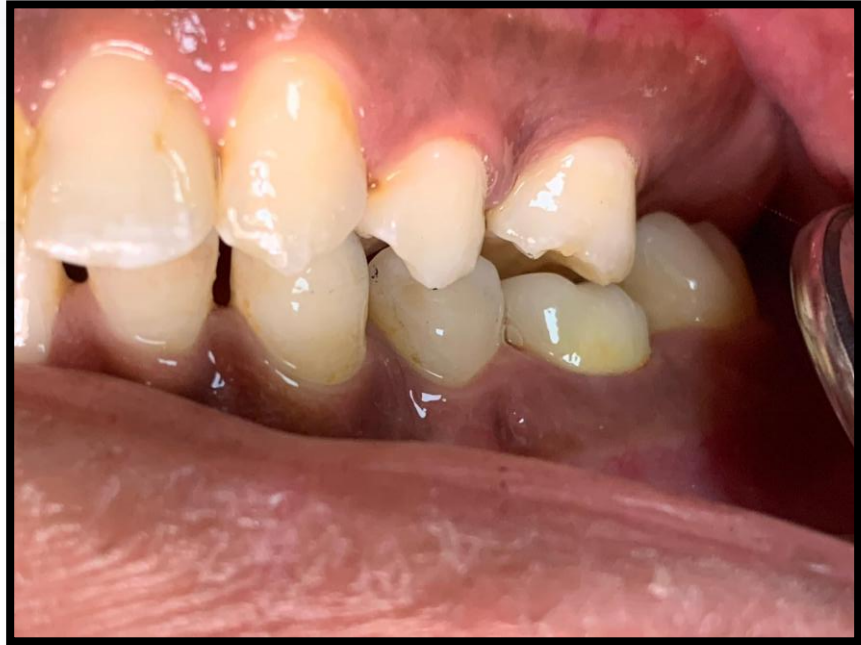6. Insertion of PFM crown.



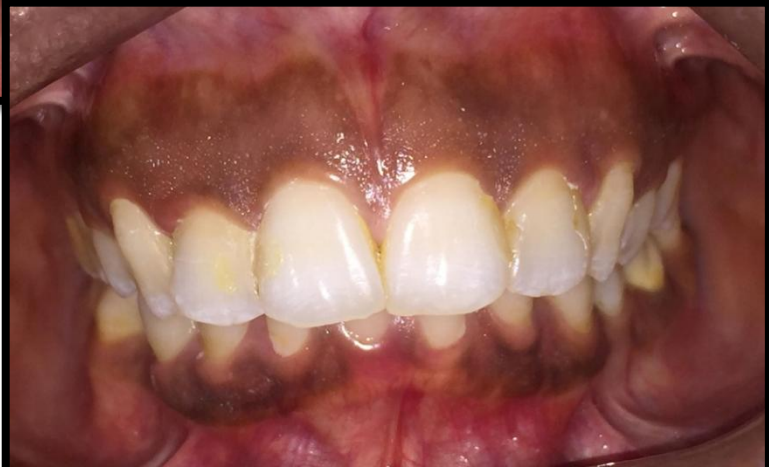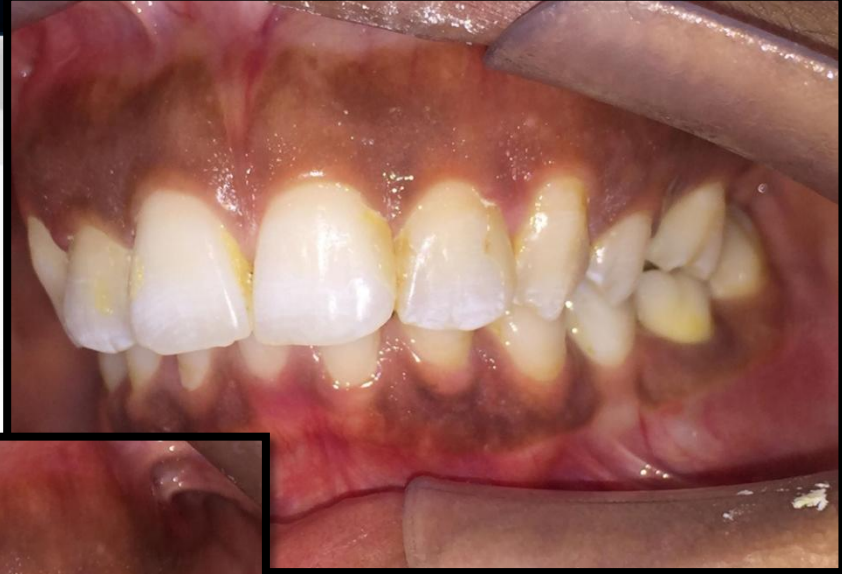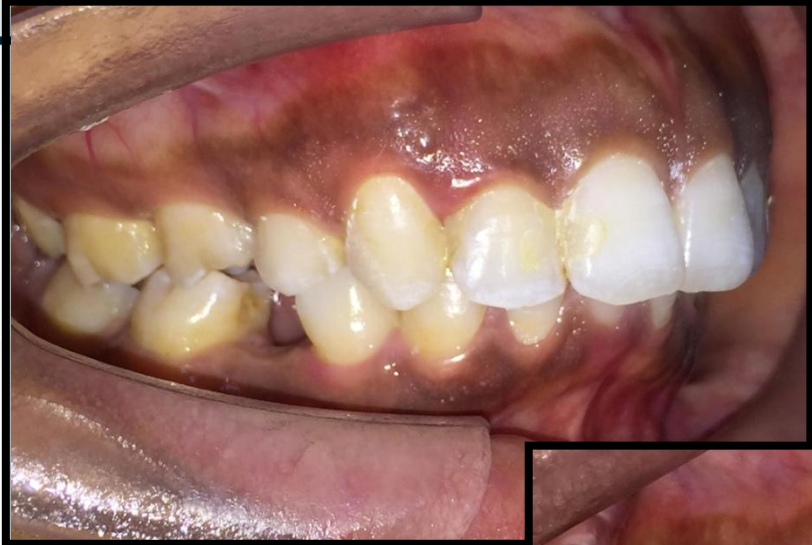7. Cementation of PFM crown:

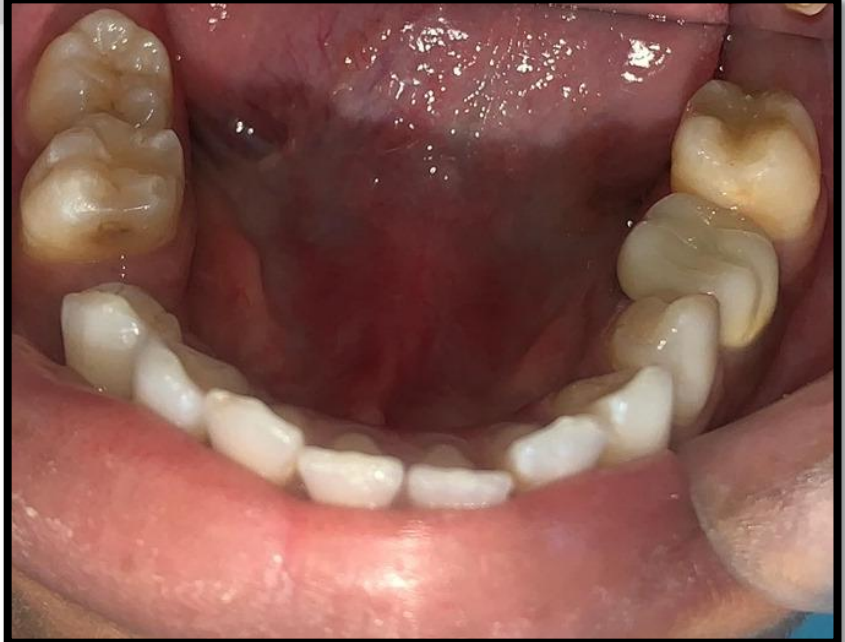
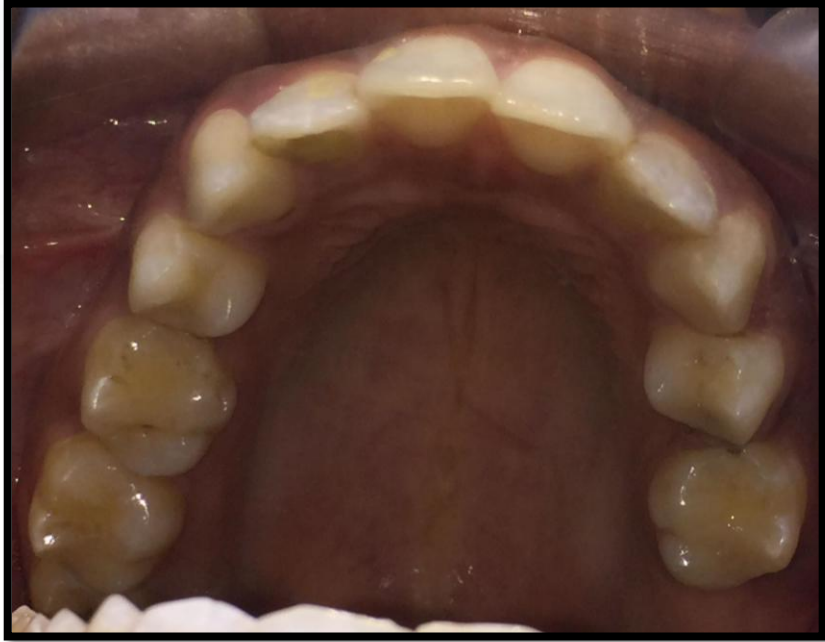




Post operative treatment







Thank you for your attention