

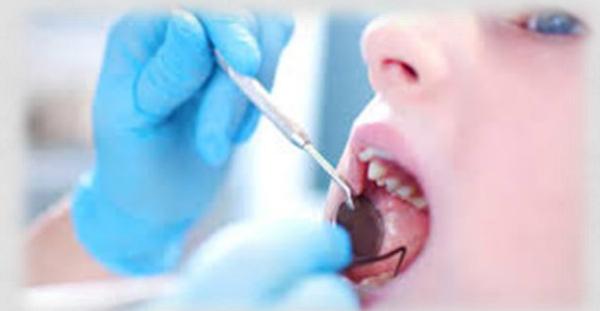

Comprehensive treatment - Full Mouth Rehabilitation case

*PRESENTED BY: ORJWAN MADI
ROLL NUMBER:986*

**THIS WORK WAS ACHIEVED BY THE STUDENT: ORJWAN
UNDER THE SUPERVISION OF DENTAL TEACHING STAFF AT LIBYAN
INTERNATIONAL MEDICAL UNIVERSITY:**

- *Dr. Rafeeq M. Al Kuafi*
- *Dr. Abdelmonem Abdelnabi*
- *Dr. Ali Busnaina*
- *Dr. Khadige Alfallah*
- *Dr. Amal Alawami*
- *Dr. Noha Alkadiky*
- *Dr. Anas Alharati*
- *Dr. Malek Abdelmatiolbe*
- *Dr. Marwa Elsharksi*
- *Dr. Randa ElHasi*
- *Dr . Manal Bazina*
- *Dr. Asma Ben Hareiz*



PERSONAL DATA

****Name : D.M.B***

****birth date : 1973 /10/5***

****Gender: Female***

****Nationally : Libyan***

****Occupation : Technical analysis***

****adders : Alberka***



CHIEF COMPLAINT & HISTORY OF CHIEF COMPLINE

*** C.C :**

Patient came to LIMU clinic want to replace her missing teeth

***H.C :**

The teeth was missed by extraction due to carious with out history of replacement patient now want to replaces due to function and esthetic reason .

Medical history : N.O.S

Drug history : N.O.S

Allergic history : N.O.S

Family history : her mother D.M typell and hypertension

Social history : married have 4 children

not smoker , alcoholic or drug abuser.

P.t is on balanced diet and drinking about 6 to 8 cups of water.

DENTAL HISTORY

***Dental history:**

extraction have been done at 2012

***History of dental treatment Exo,Endo,filling&scaling.**

***Oral hygiene practice :**

***Brushing : irregularly**

***Brushing method : medium tooth brush horizontal**

***Kind of Dentifrice used : not specific**

***any other orophysiotherapeutic Aids :nothing**

EXTRA-ORAL EXAMINATIONS

TMJ Status :

examination reveals no finding

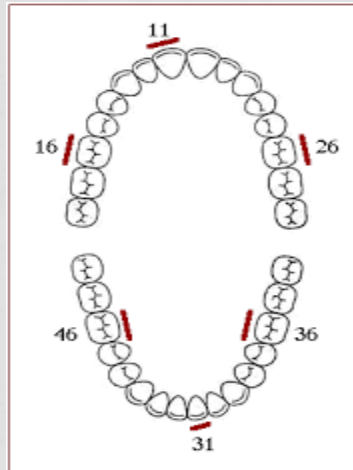
Facial :symmetry

Lymph nod :not palpable

ORAL HYGIENE INDEX

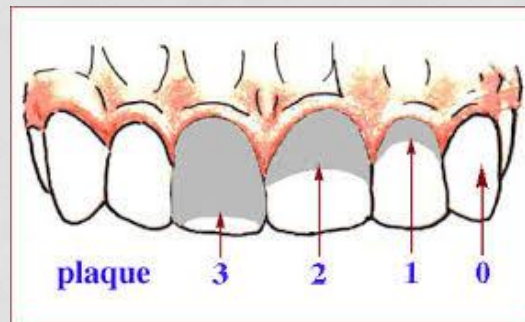
| 16 | 11 | 26 |
|----|----|----|
| 1 | 0 | 3 |
| 1 | 1 | 3 |
| 46 | 31 | 36 |

Plaque index: 1.5



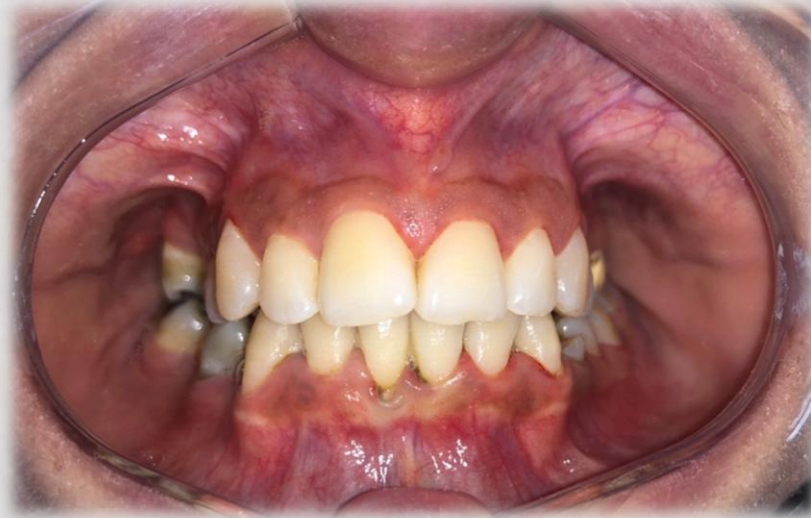| 16 | 11 | 26 |
|----|----|----|
| 0 | 0 | 3 |
| 1 | 3 | 1 |
| 46 | 31 | 36 |

Calculus index: 1.3

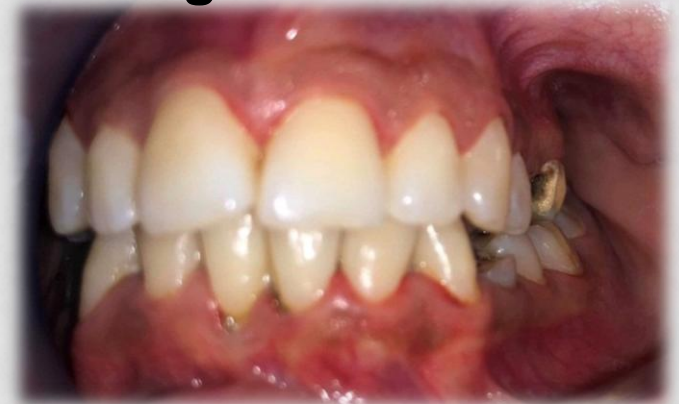
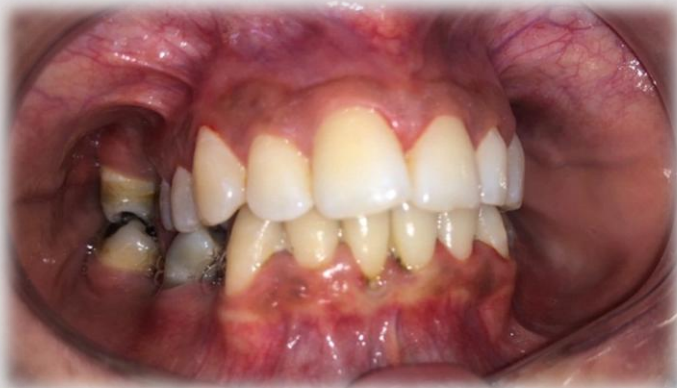
Fair (2.8)

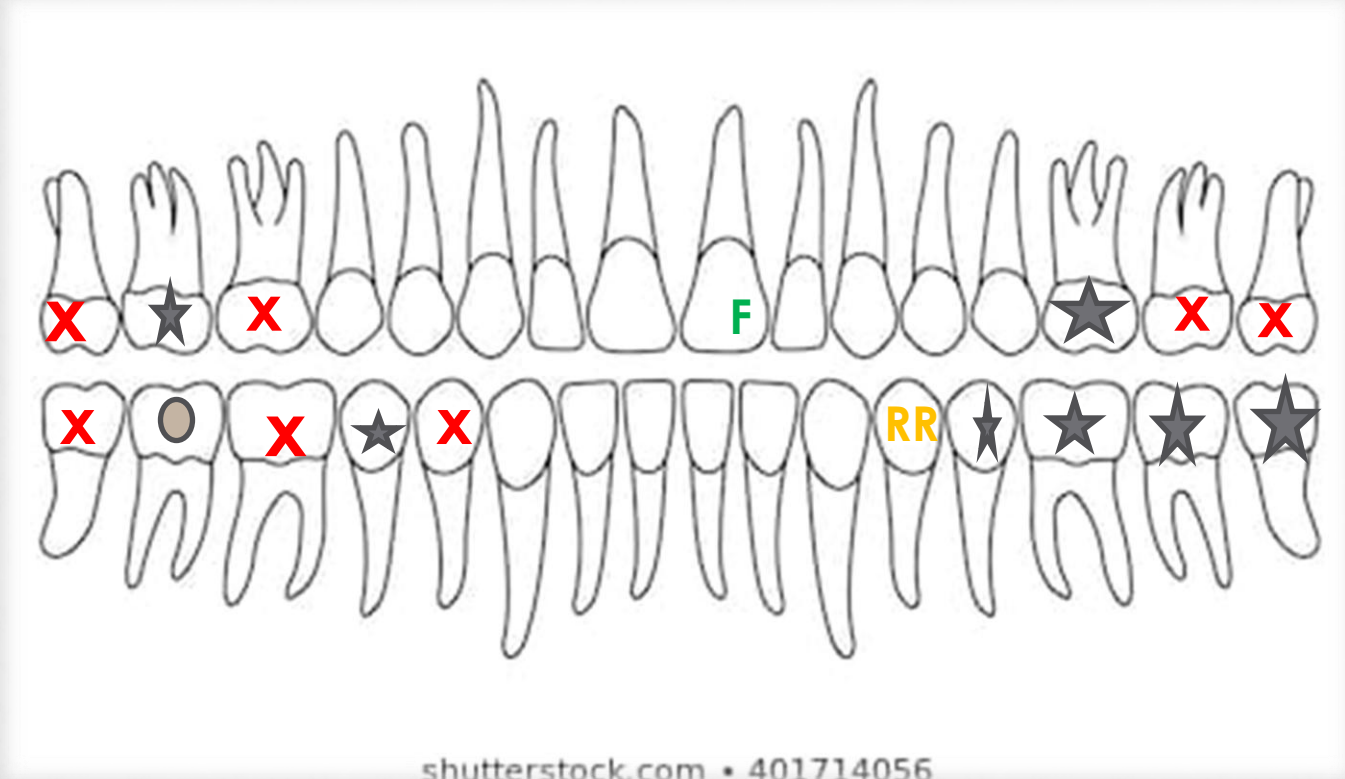
INTRA ORAL PHOTO



Oral mucosa :normal except partial tongue tie



DENTAL CHART

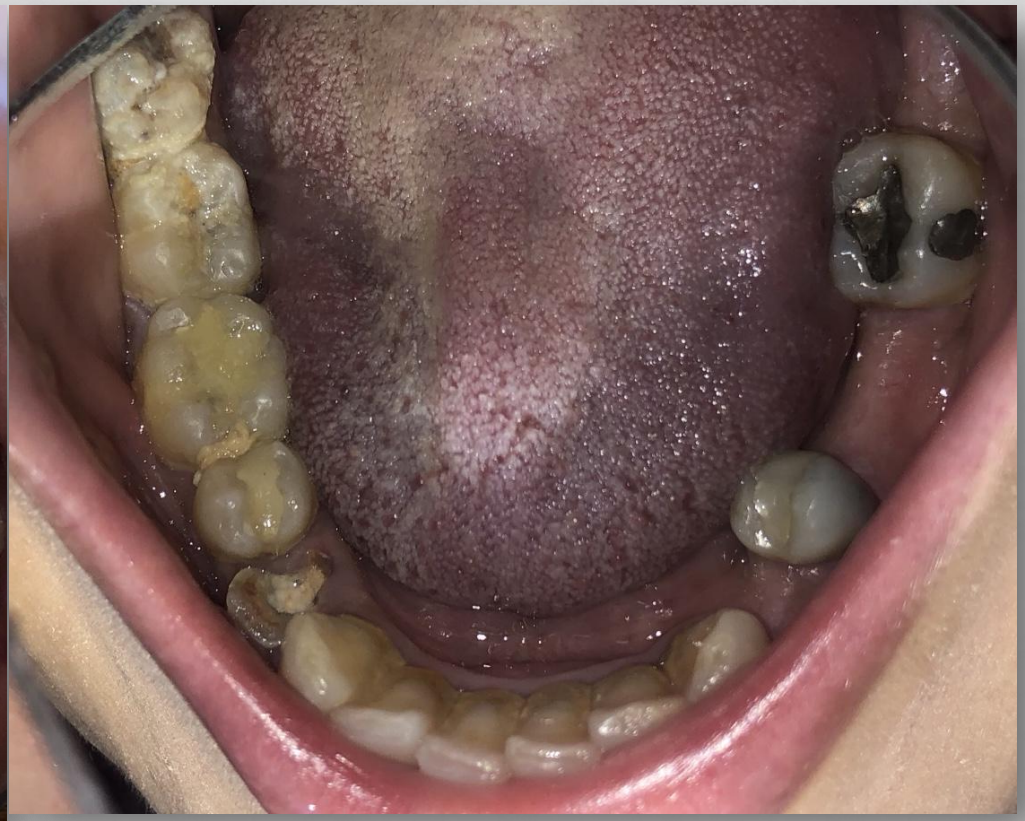
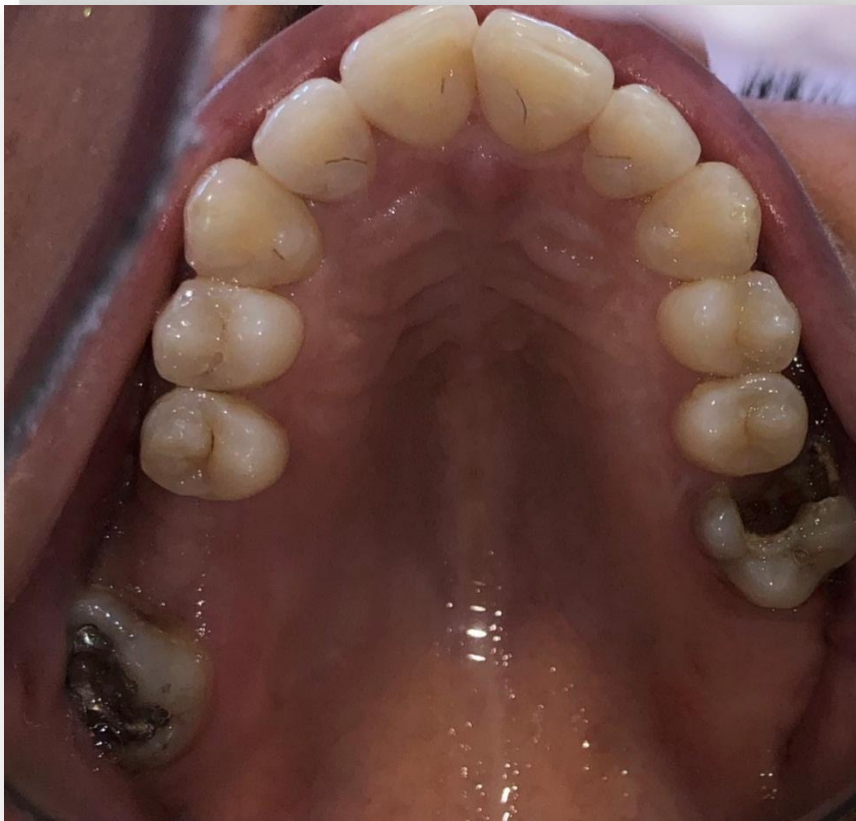
shutterstock.com • 401714056

DMFT:12

X :missing4 **★** :decay6 **F** : fracture1 **RR**: remaining root1 **●** :filling1

UPPER AND LOWER ARCH



PERIODONTAL HEALTH



The gingiva is reddish pink in color , with altered scalloped rounded margin and blunt IDP .

Pocket depth was within normal range for all aspects .

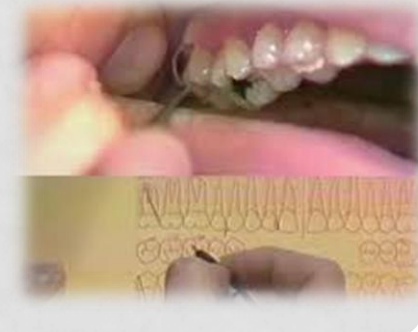There -is bleeding on probing related to upper and lower anterior and posterior teeth.

There is no mobility .

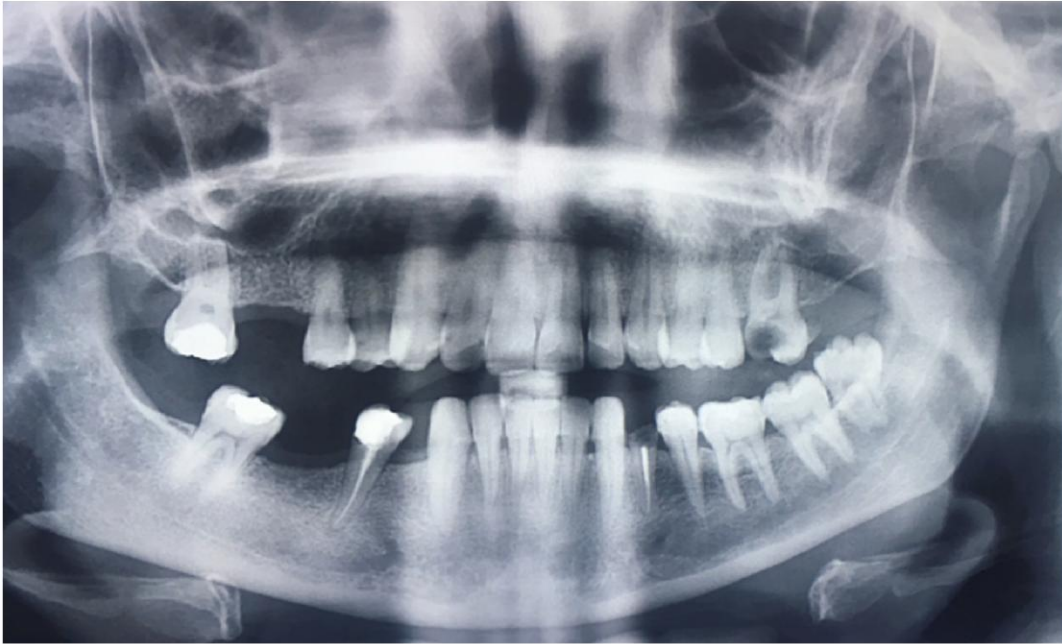There is a recession relater lower left central incisor & second premolar.

Diagnosis:

Localized mild chronic periodontitis.



ORTHPANTOMOGRAPH



Radiographic show:

- Localized Mild horizontal bone loss in Lower anterior teeth.**
- Calculus also lower anterior teeth**
- missing teeth**
- Endodontic treated teeth**
- Restored teeth**

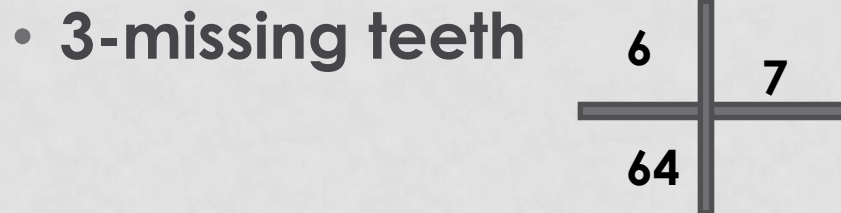
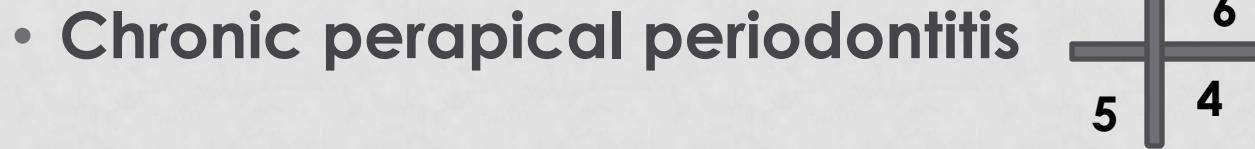
The patient is unidirectional group function occlusion

The incisor relationship : class I

Class III according to Kennedy classification

FINAL DIAGNOSIS

- 1-localized mild chronic periodontitis

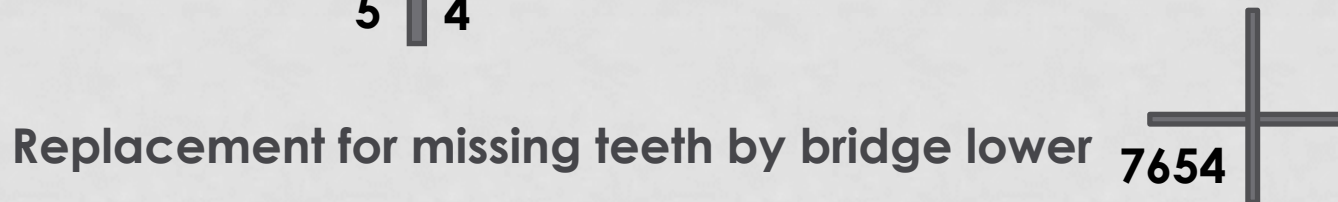
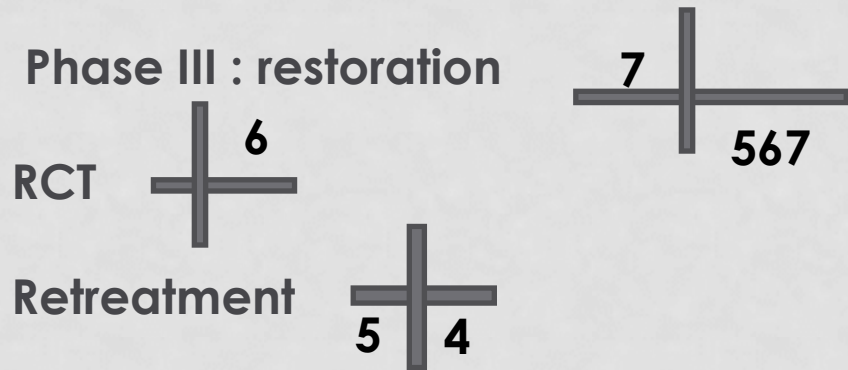


TREATMENT PLAN



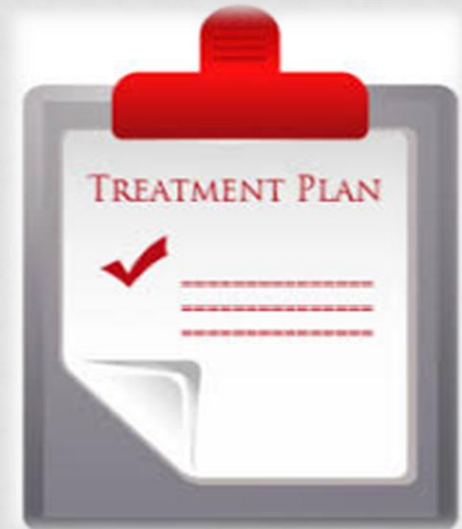*Emergency phase : not indicated for emergency
 *Phase I : O.H instruction , scaling and root planning
 Diet sheet and pit& fissure sealant

* Phase II : extraction lower left 8 crown lengthening lower left4

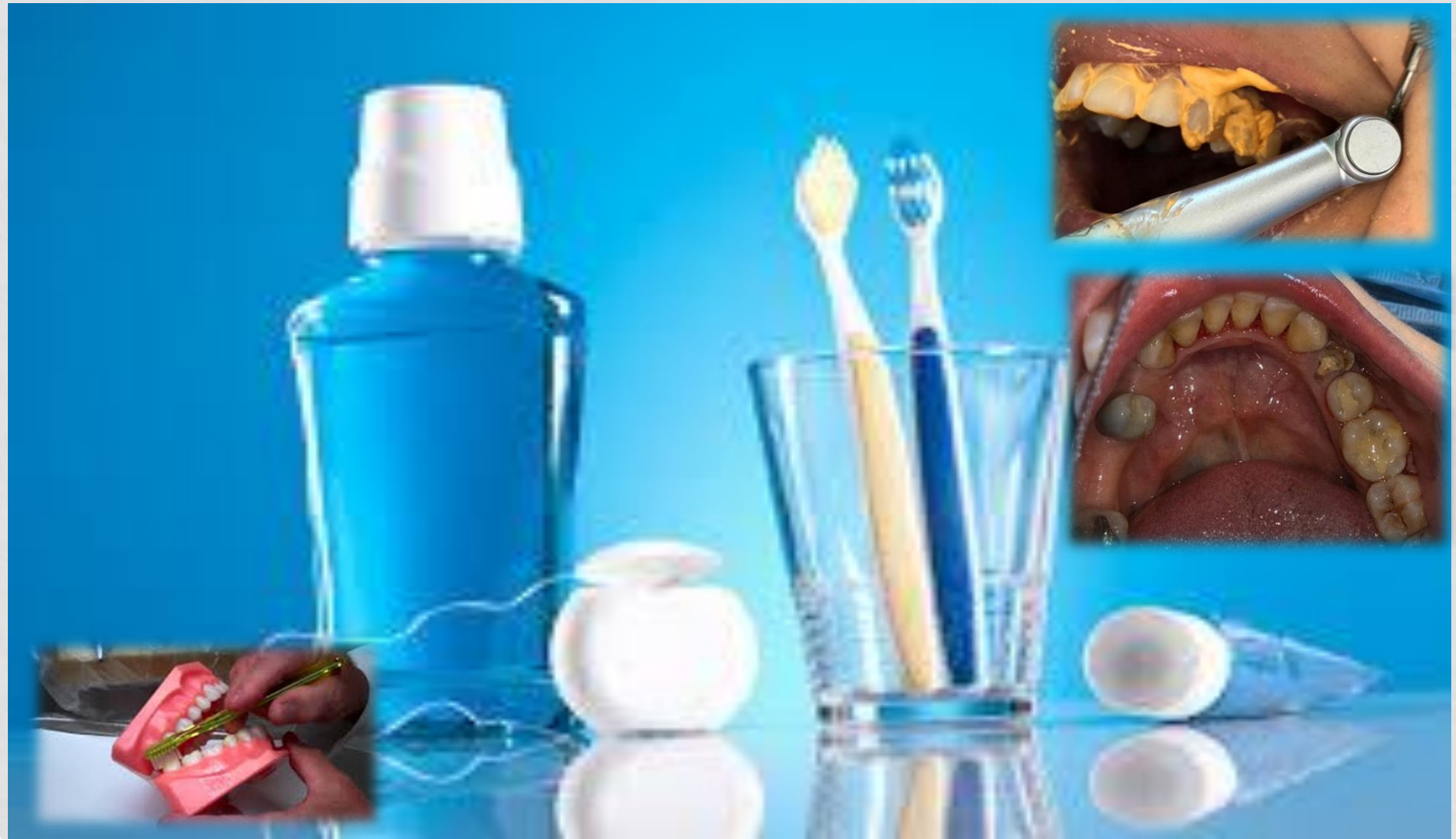

crown lower left 4, partial removable upper right 6

*Phase IV : re evaluation 1week and 1month



PHASE I THERAPY

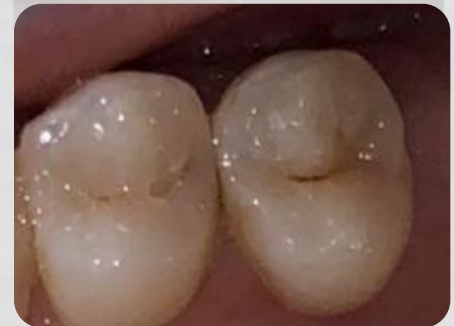
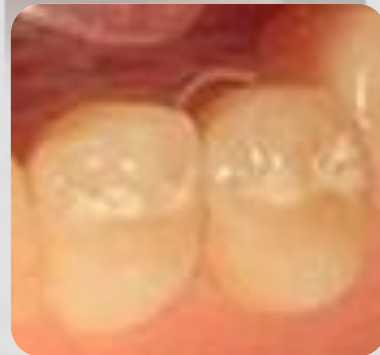
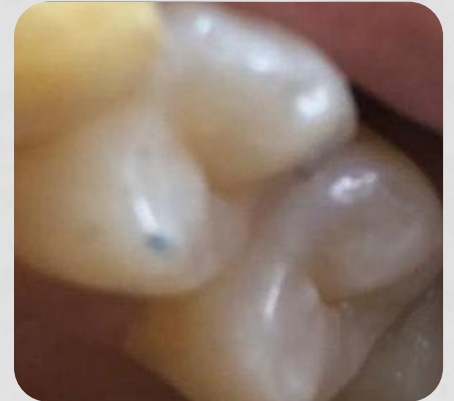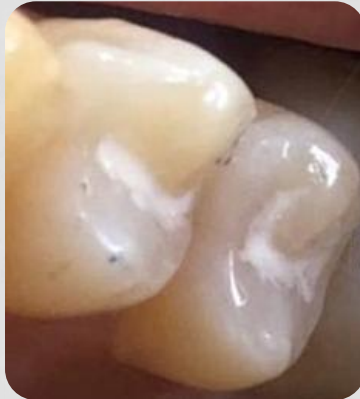DIET SHEET

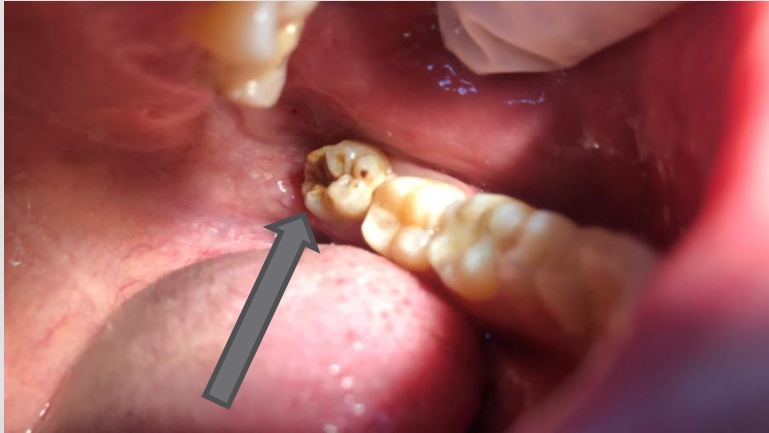
Patient Name: _____ Gender: M/F Date of Birth: 1973
 Occupation: _____ Address: _____

| نوع الوجبة | الأكولات والمشروبات | الساعة | الأيام |
|------------|-----------------------------|--------------|---------|
| فطور | حليب وشاي وكحك | 7:30 | السبت |
| غداء | تيكة قهوة / | 10:00 | |
| عشاء | خبز سلاطة • ككرو/مبة | 2:00 | |
| | دبس بدينا قازوزة | 8:00 | |
| | عسل امان قبل النوم | | |
| فطور | نكافن شكوط / صبا | فطور 7:30 | الاحد |
| غداء | طاجين دجاج سلاطة + خبز | 2:30 | |
| عشاء | سبوتة + قهوة | 5:00 | |
| | بيتره قازوزة | 8:00 | |
| | عسل امان قبل النوم | | |
| فطور | حليب وشاي كيك ناشف | 8:00 | الاثنين |
| غداء | مكرونه + لحم + سلاطة + بيبر | 2:00 | |
| عشاء | قهوة + فريجة | 5:00 | |
| | همبورجر + قازوزة | 8:30 | |
| | عسل امان | | |

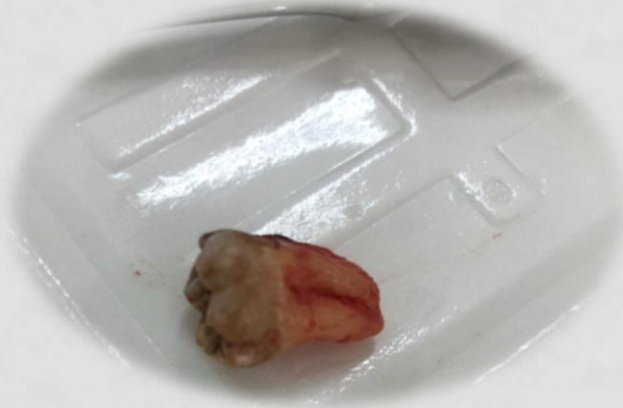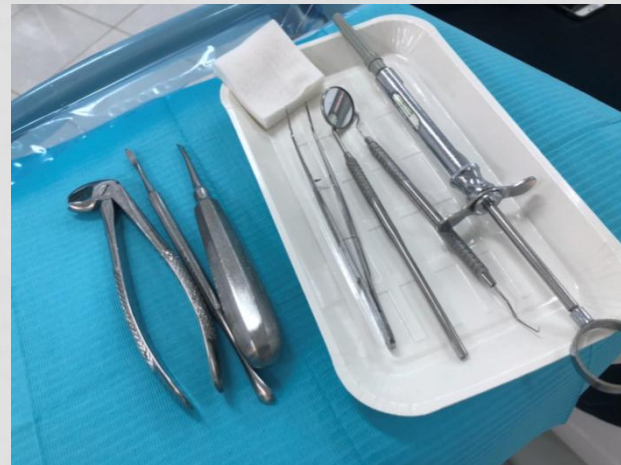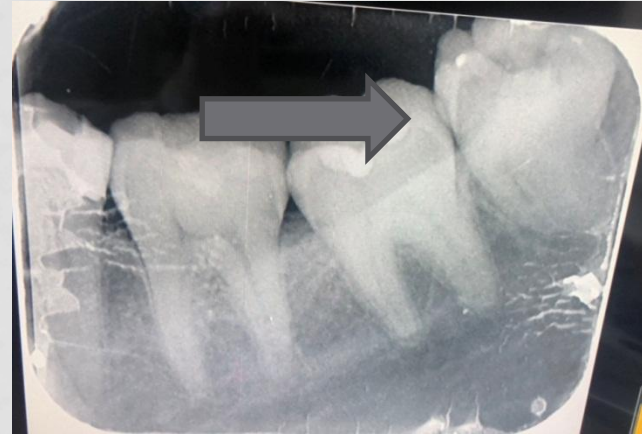PIT AND FISSURE SEALANT



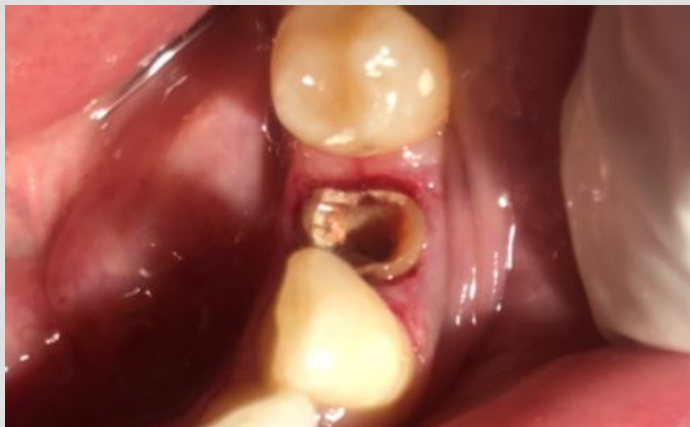
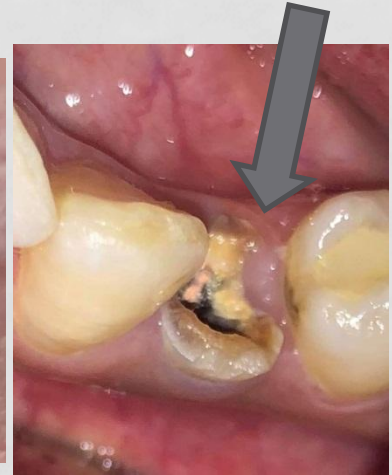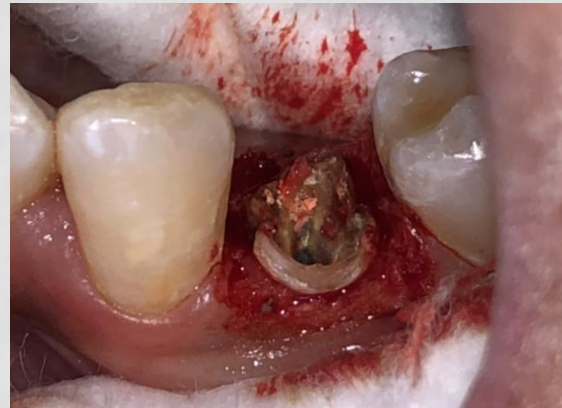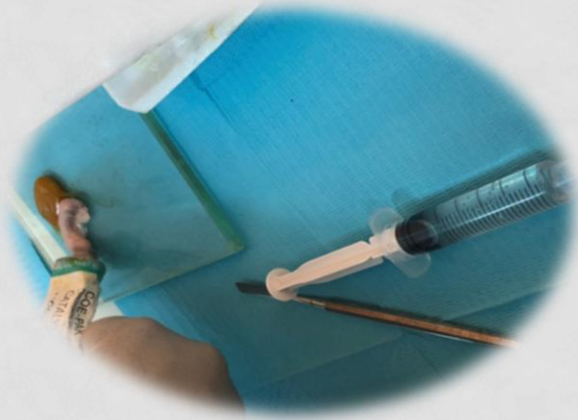
PHASE II THERAPY



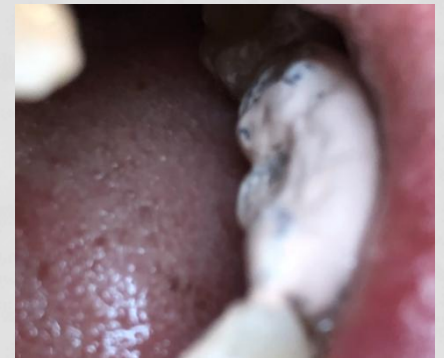extraction



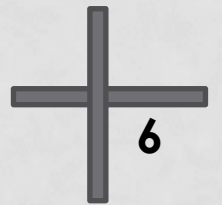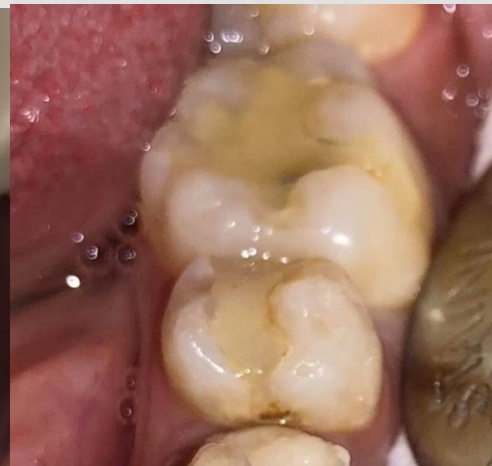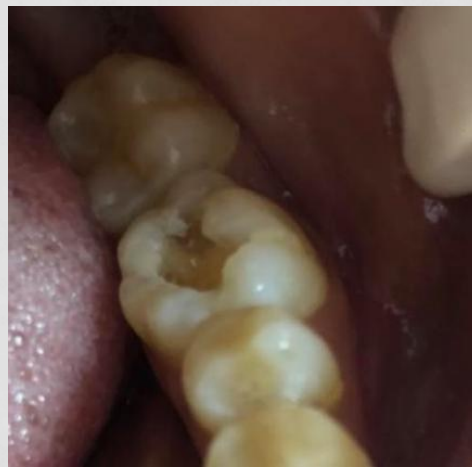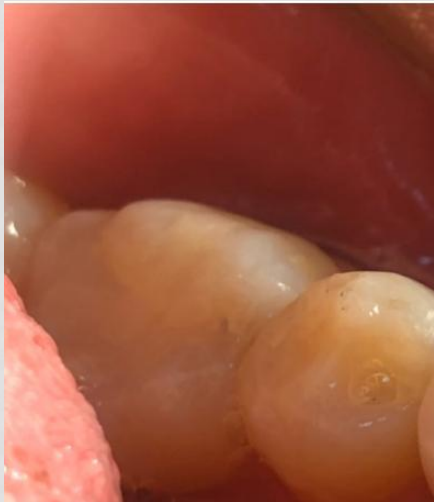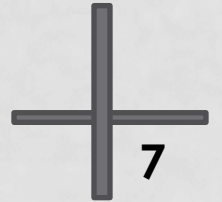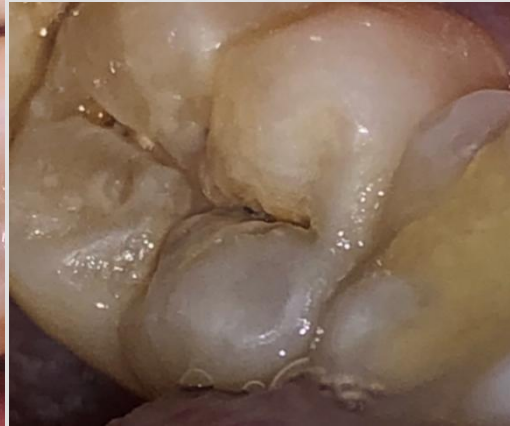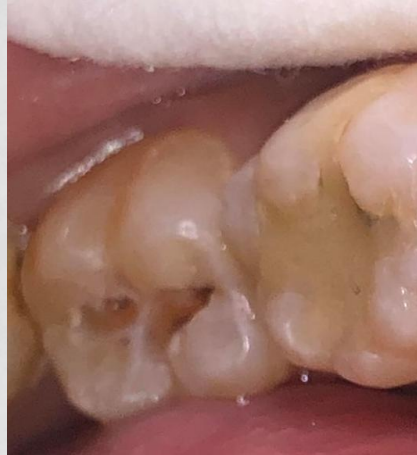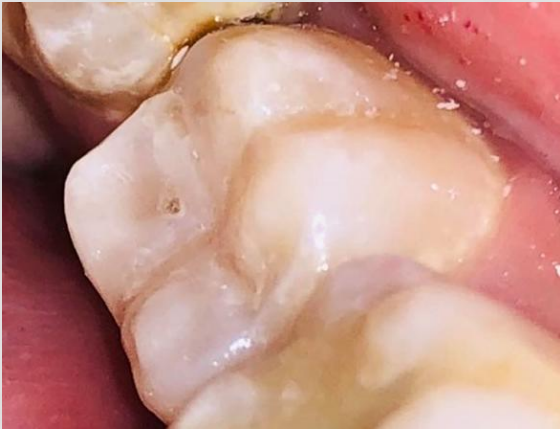CROWN LENGTHENING

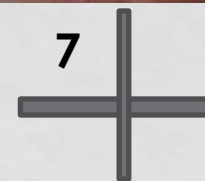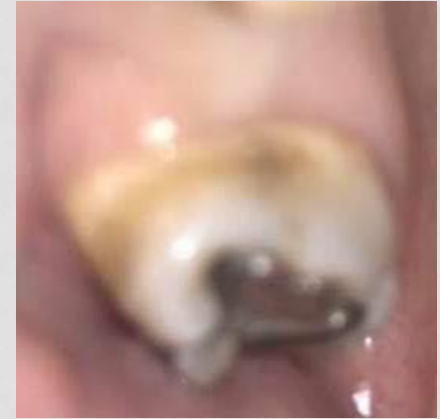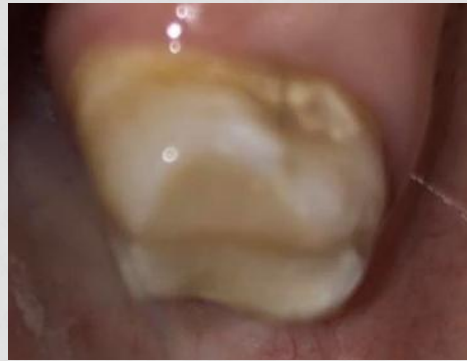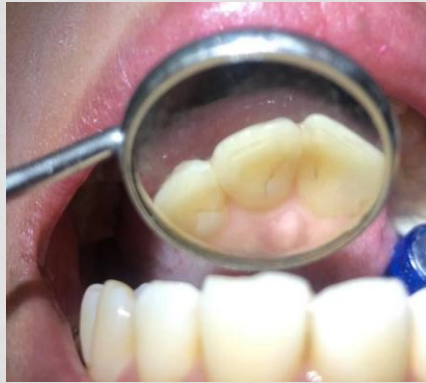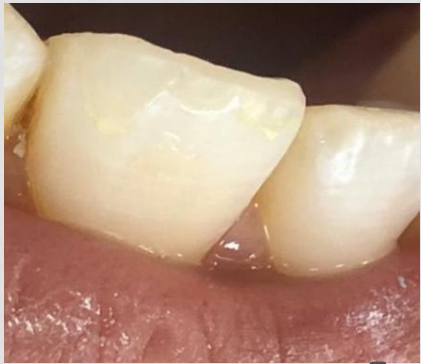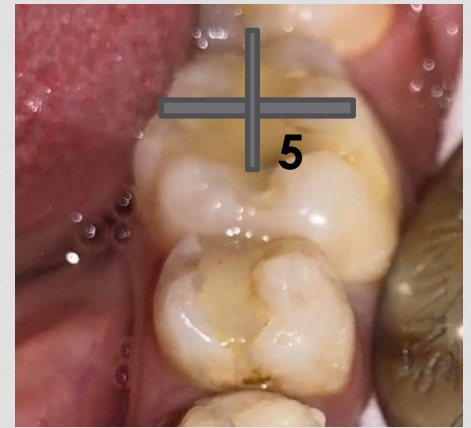


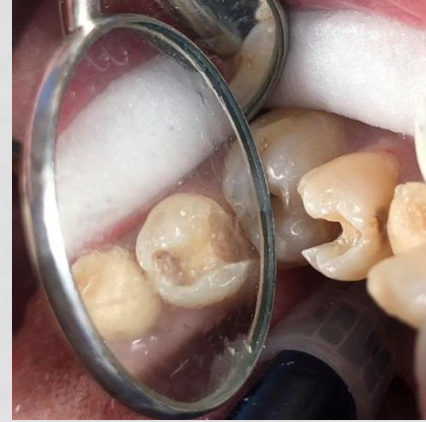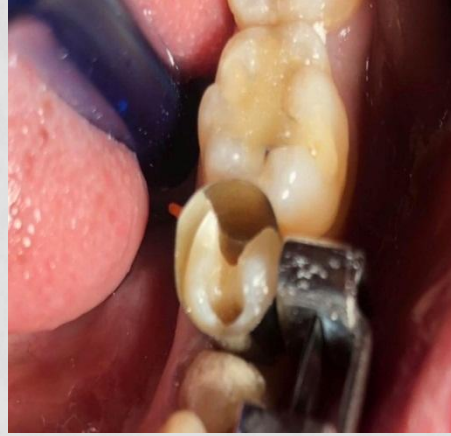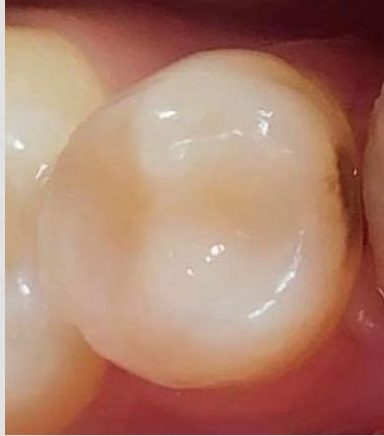After 1 week

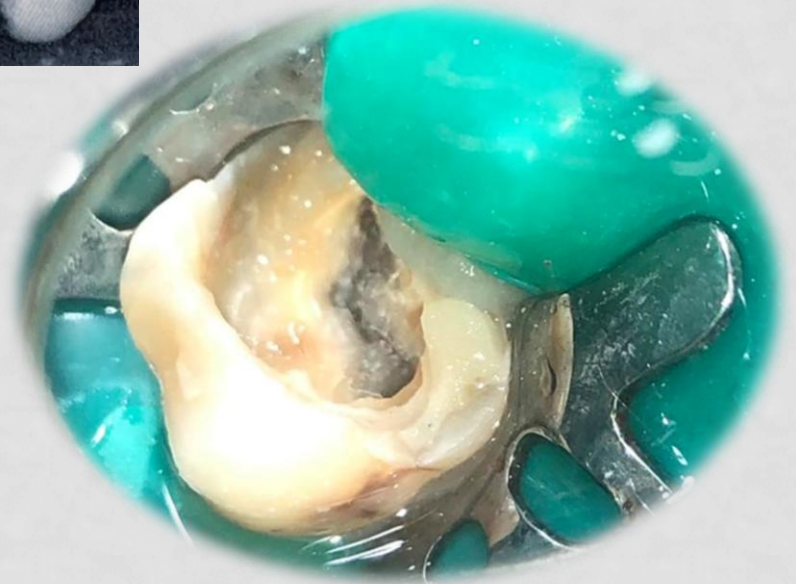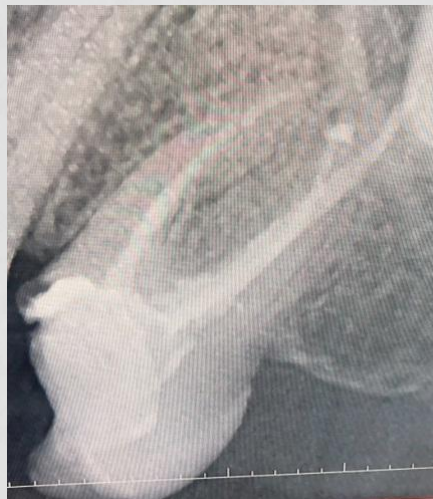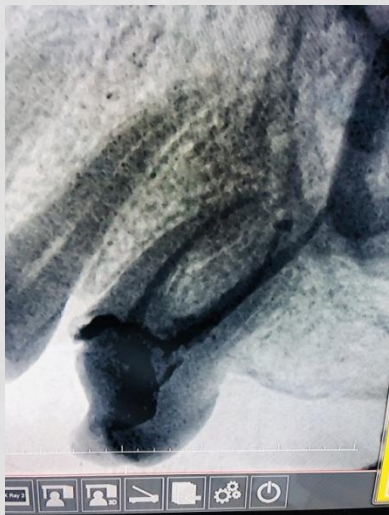
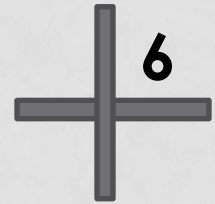


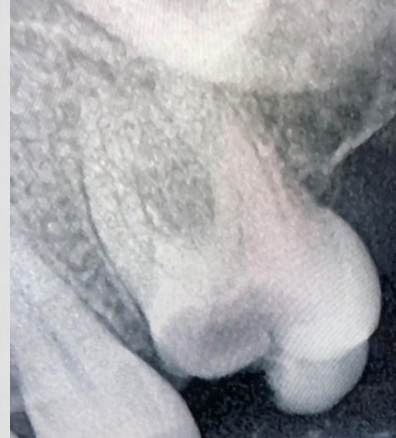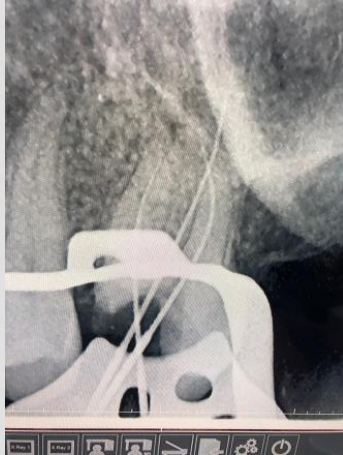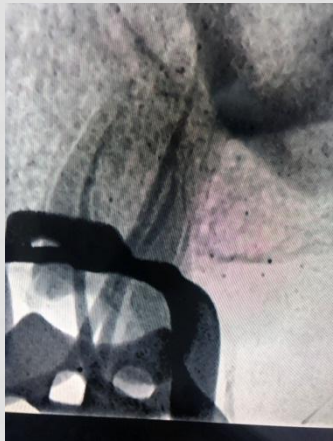PHASE II (RESTORATION)

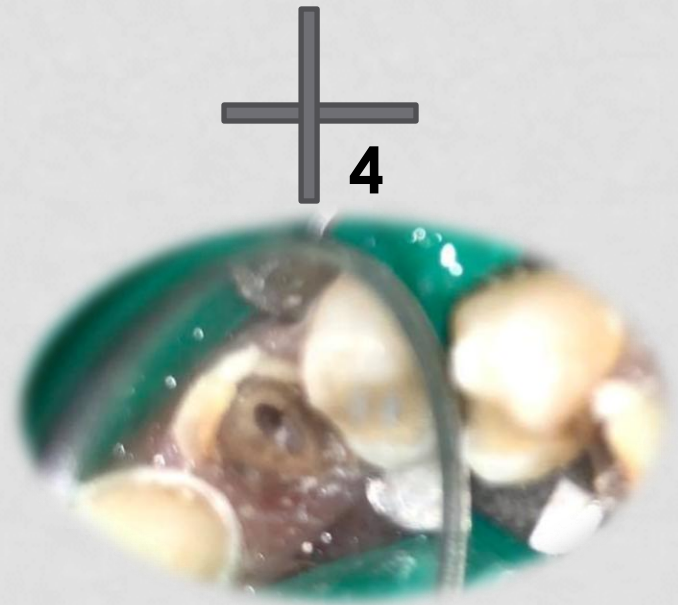
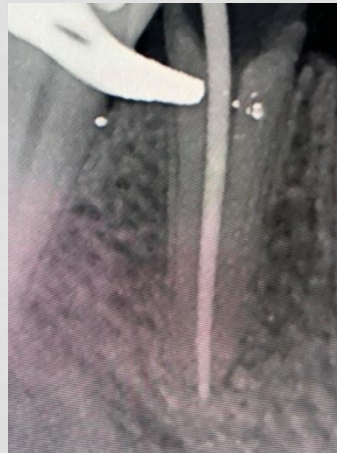
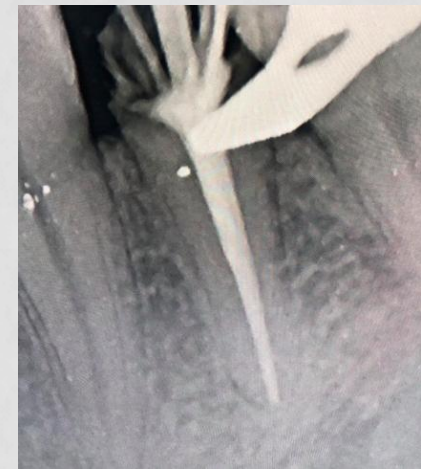
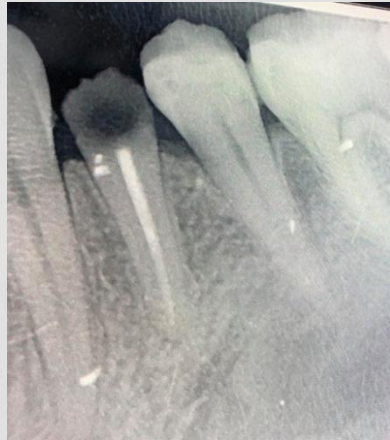
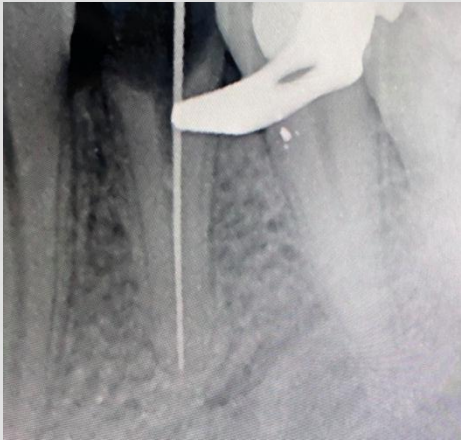
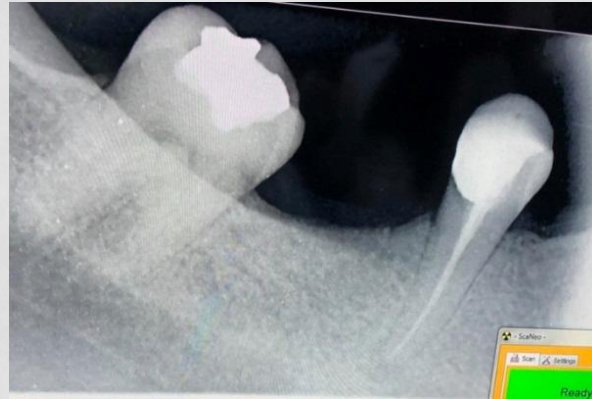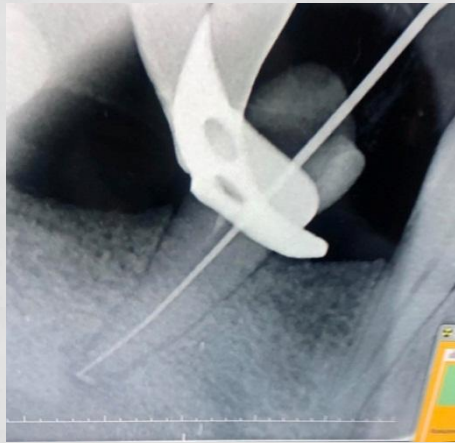ENDODONTIC TREATMENT



ENDODONTIC RETREATMENT

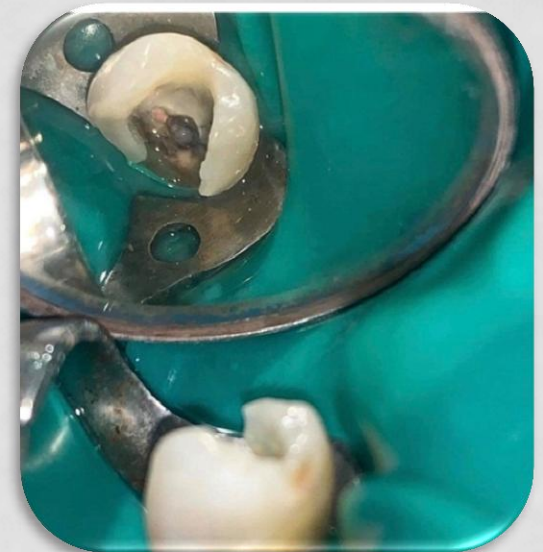
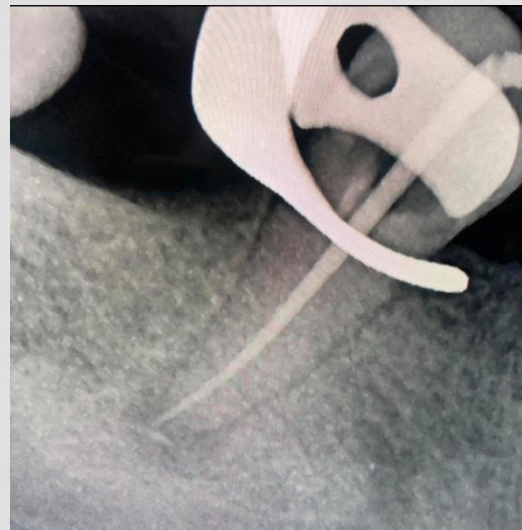
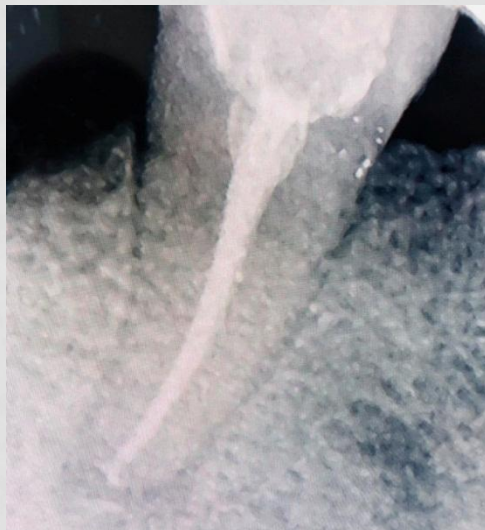

ENDODONTIC RETREATMENT

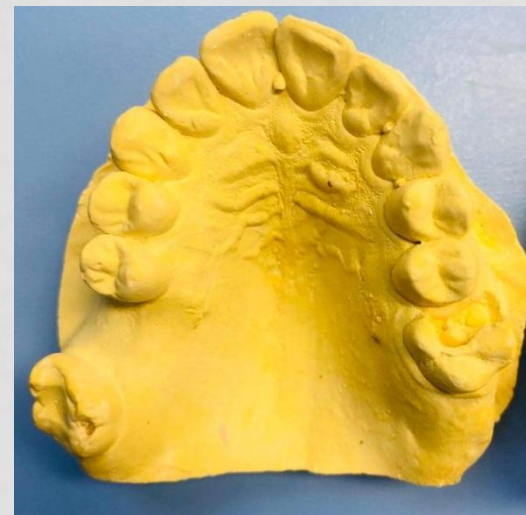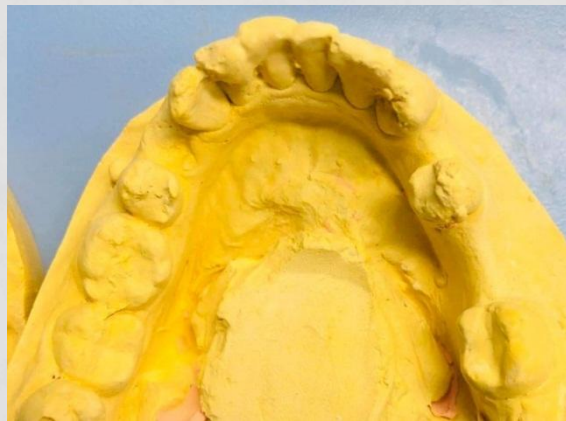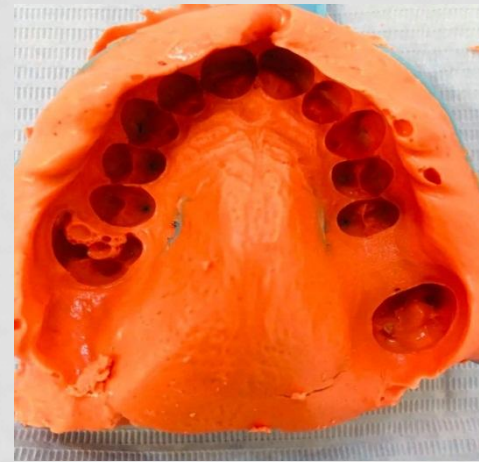
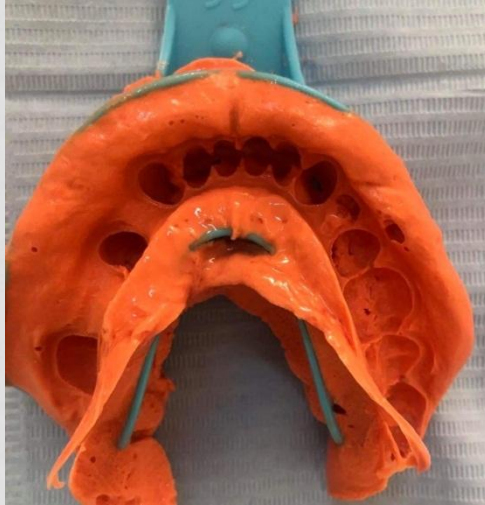


+

5

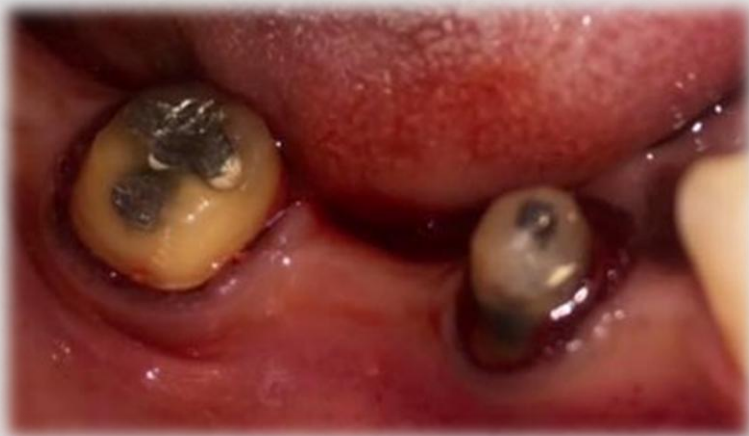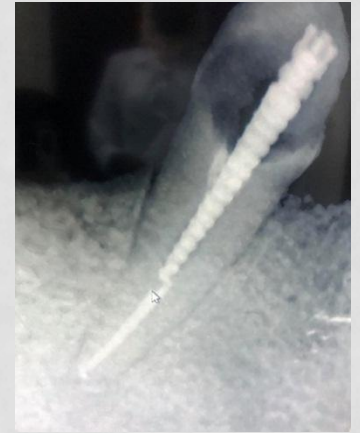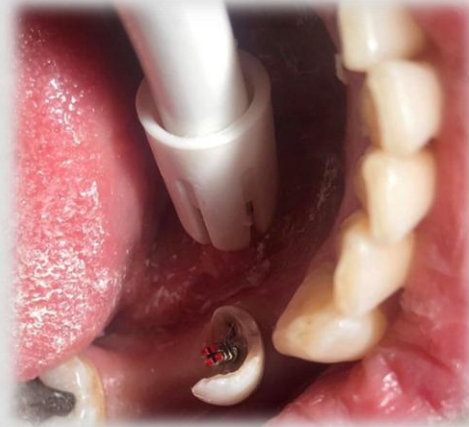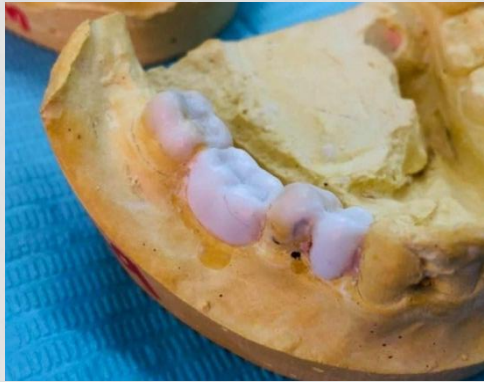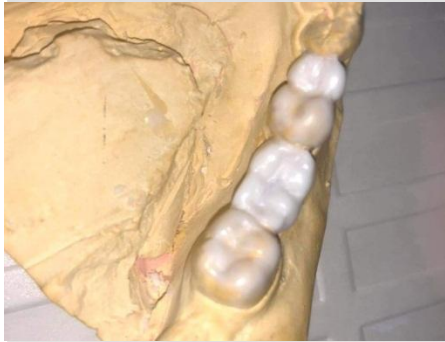


IMPRESSION

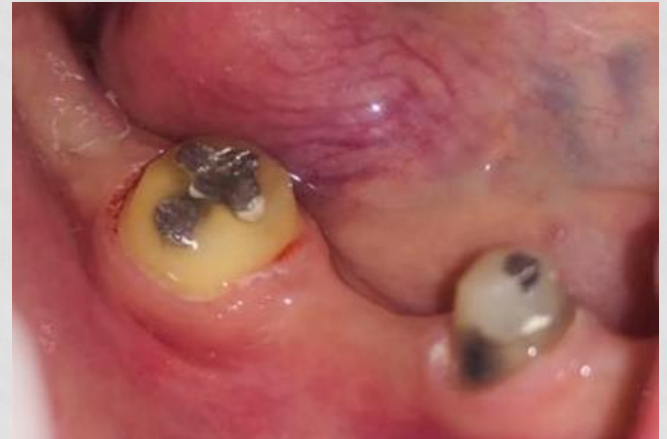


FIXED BRIDGE

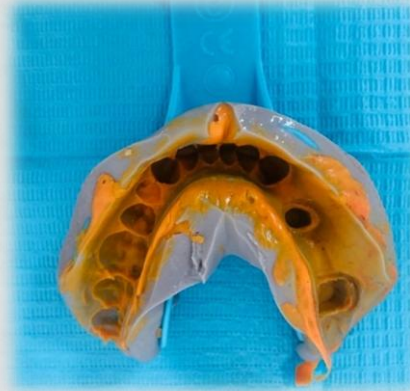
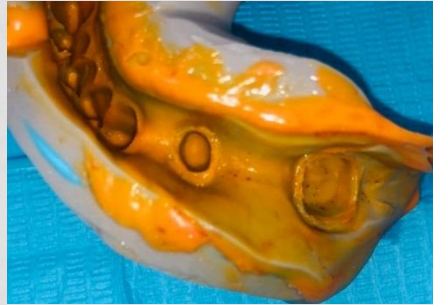
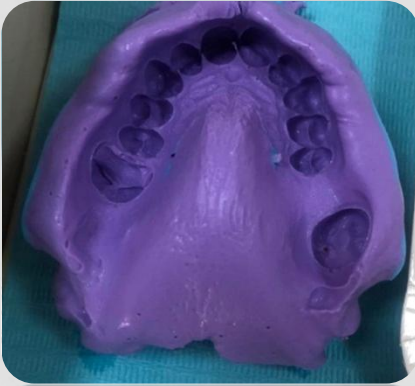7654



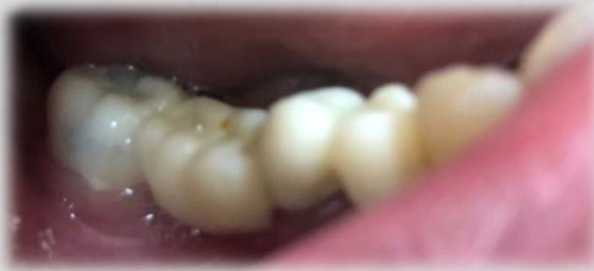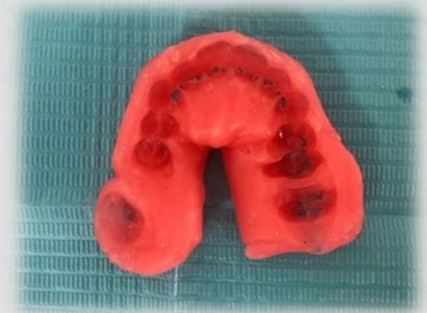
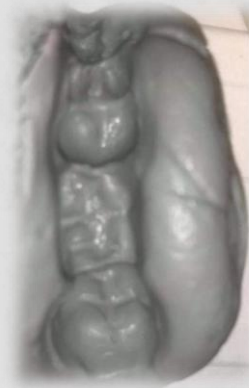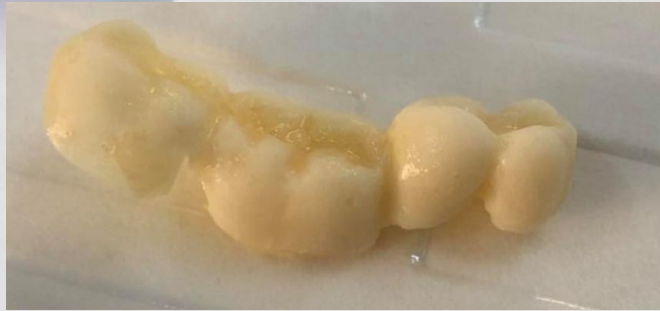Retraction
cord



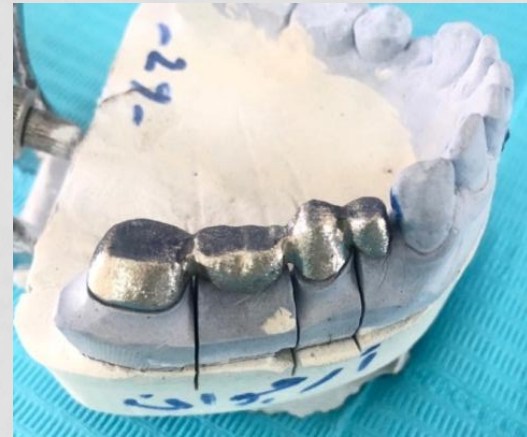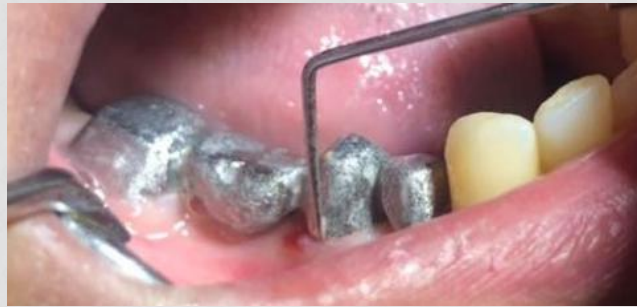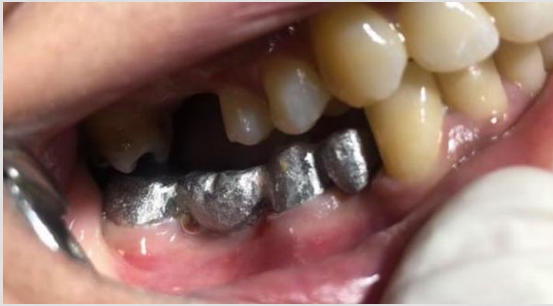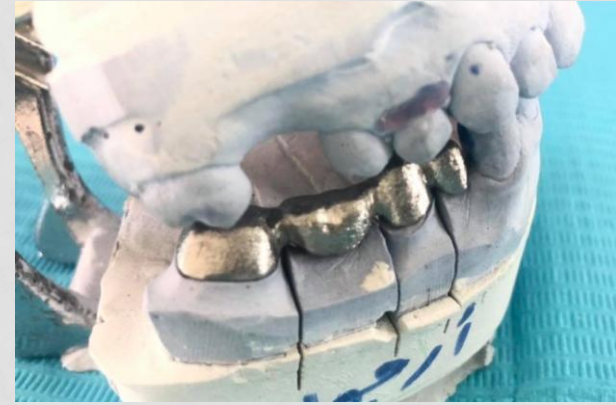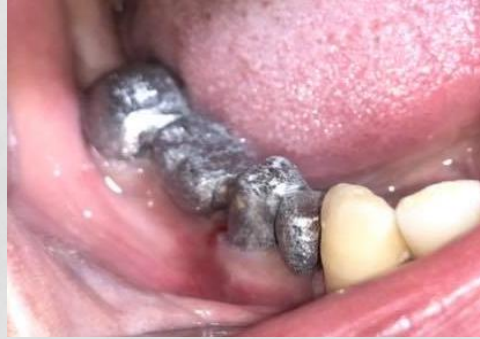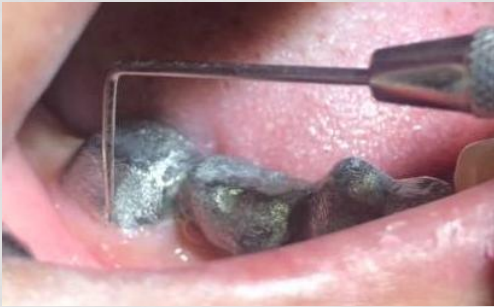FINAL IMPARTATION

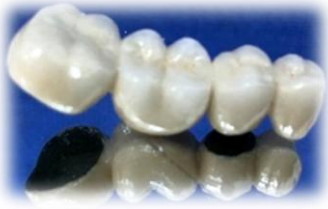

**Temper
bridge**

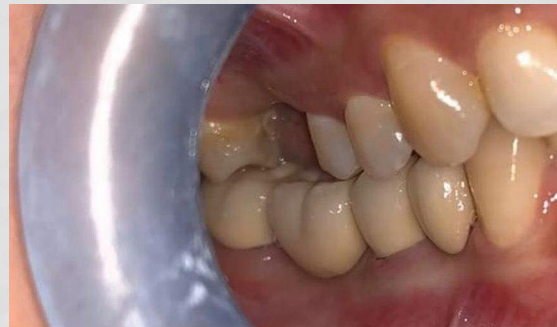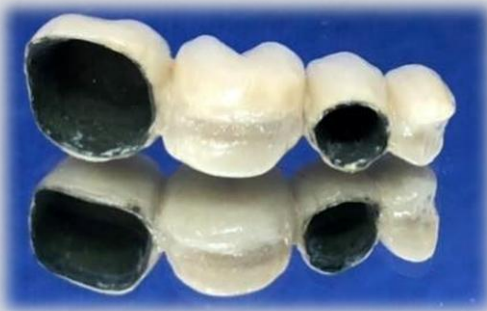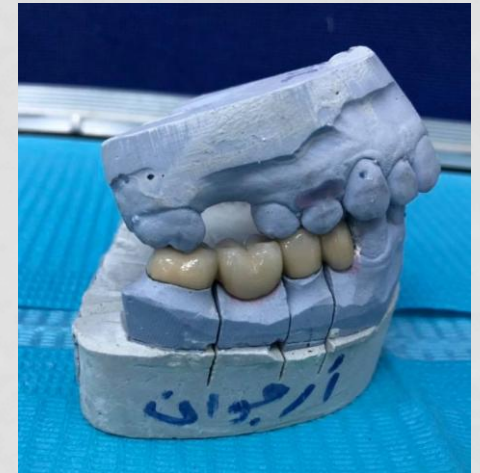


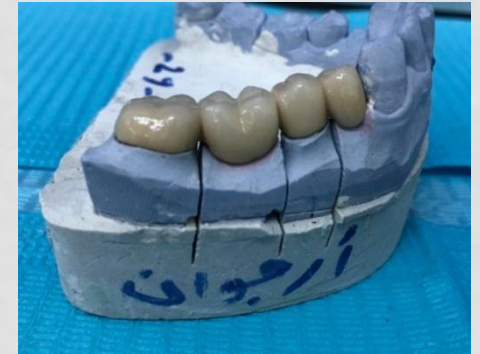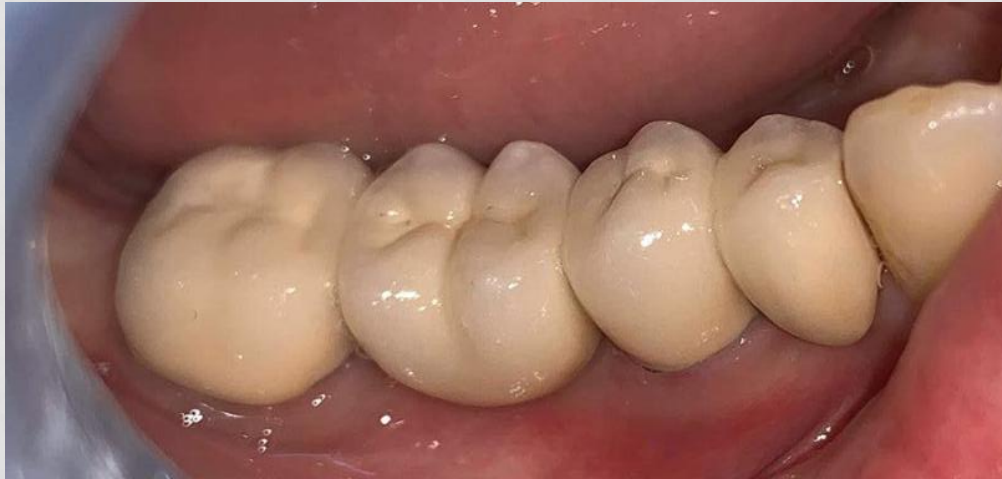TRY IN

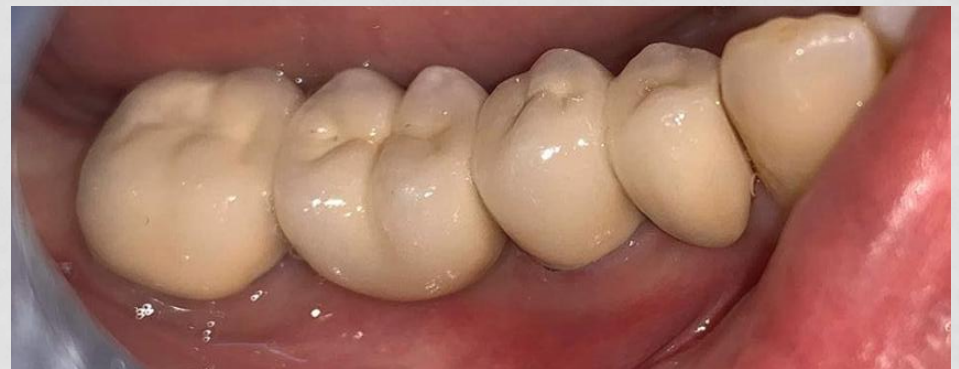
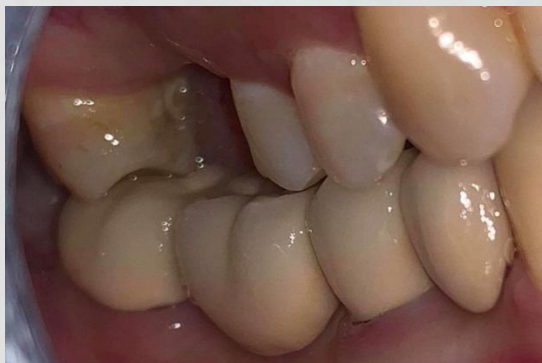
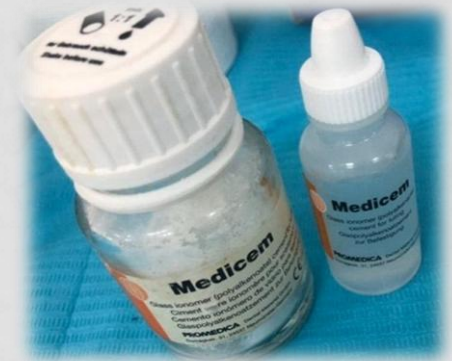
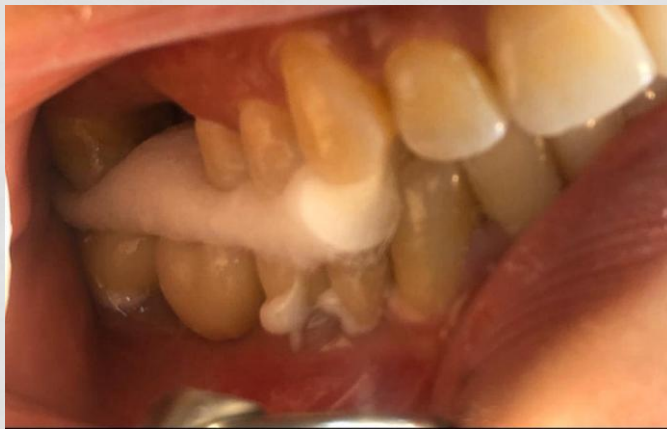
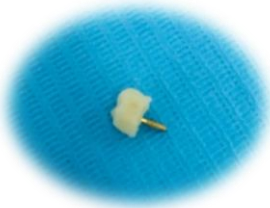TRIAL CEMENTATION

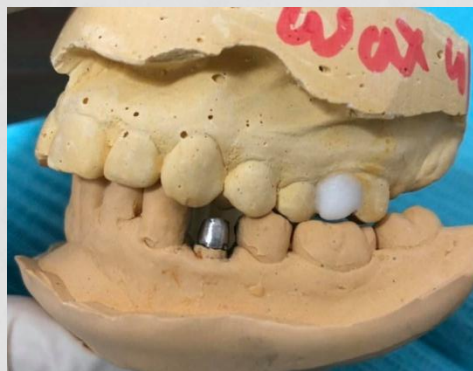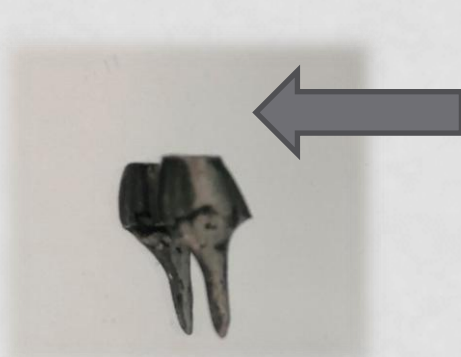
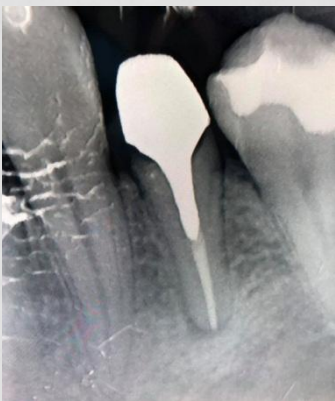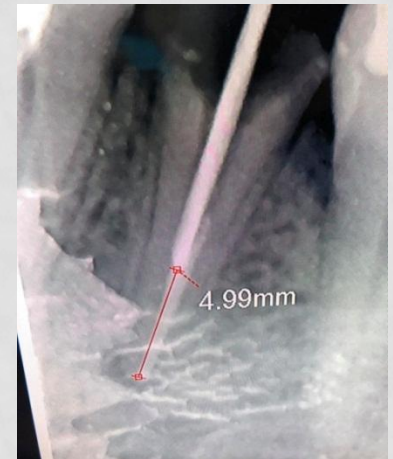
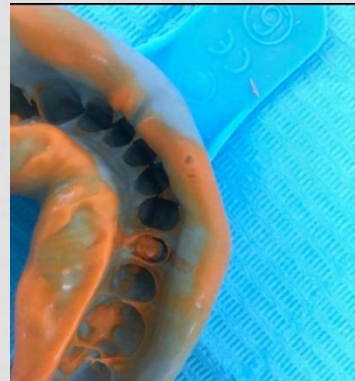


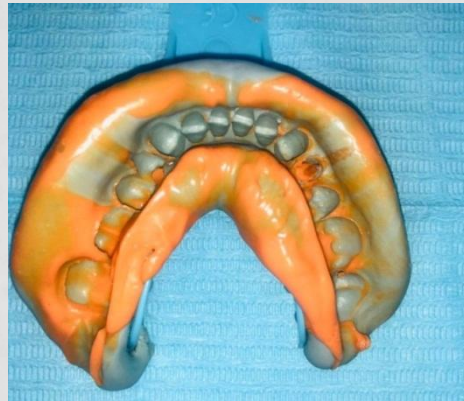
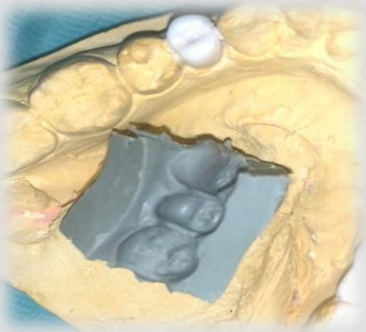FINAL CEMENTATION

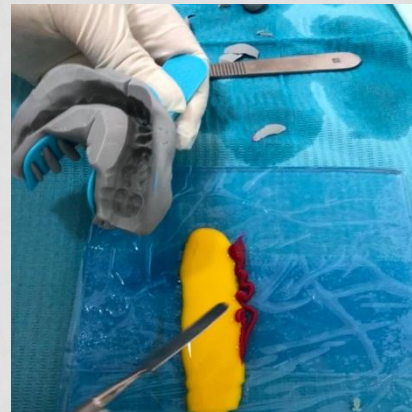
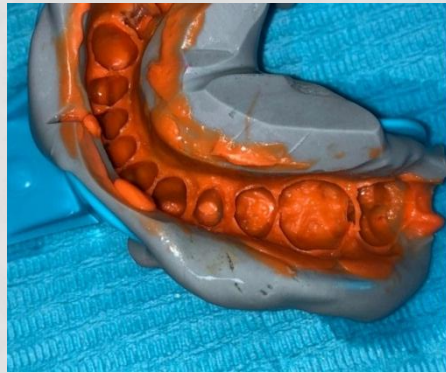
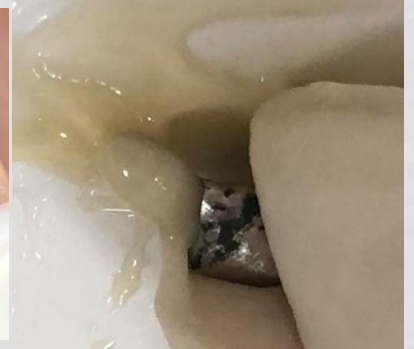
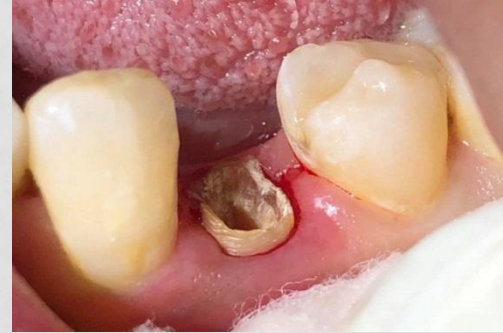
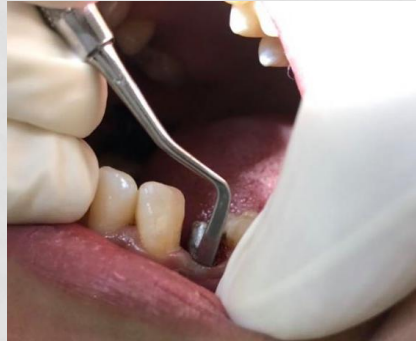
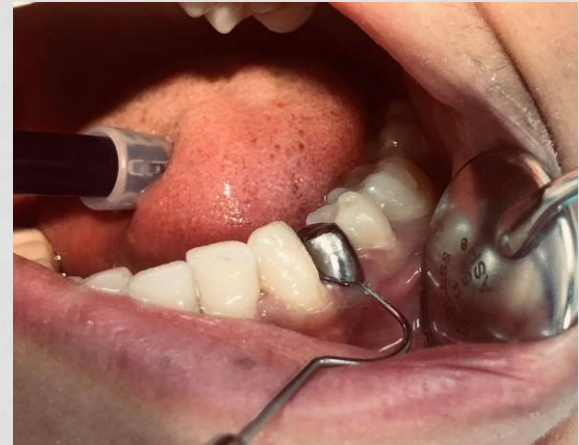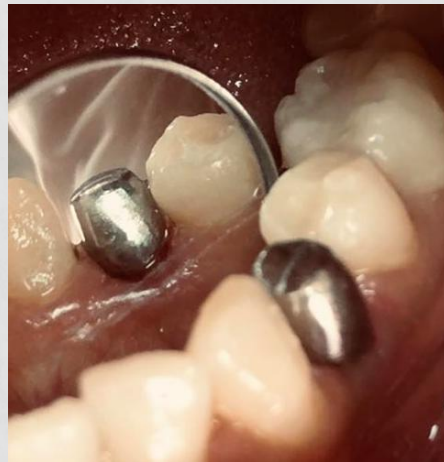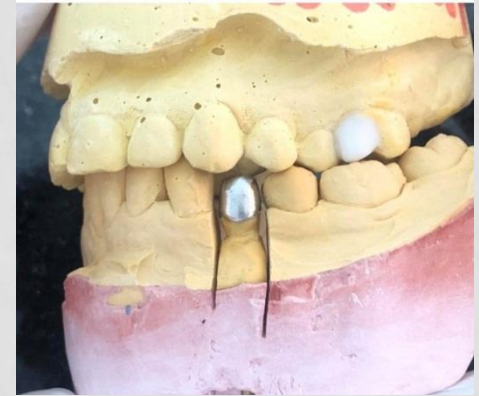
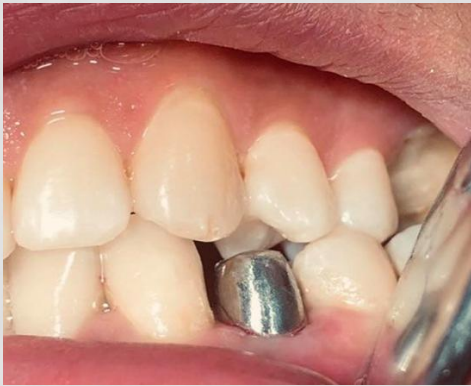POST CORE AND CROWN



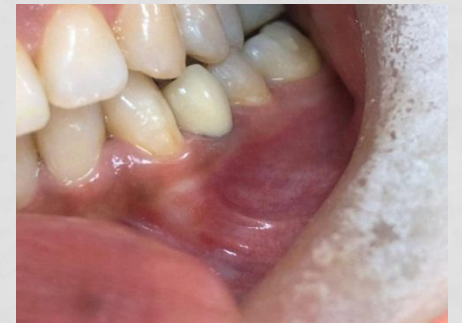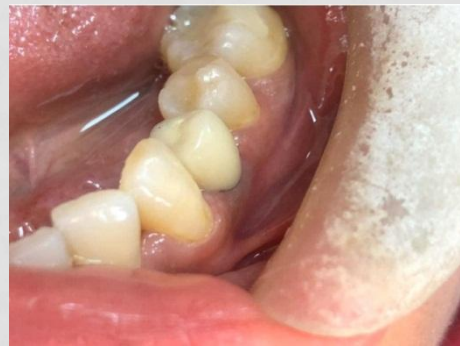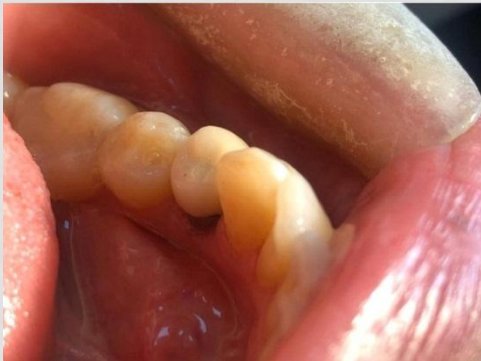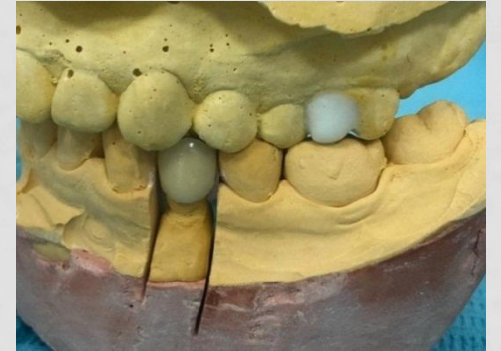
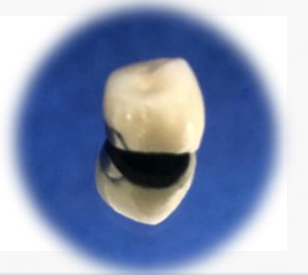
Custom
made
post



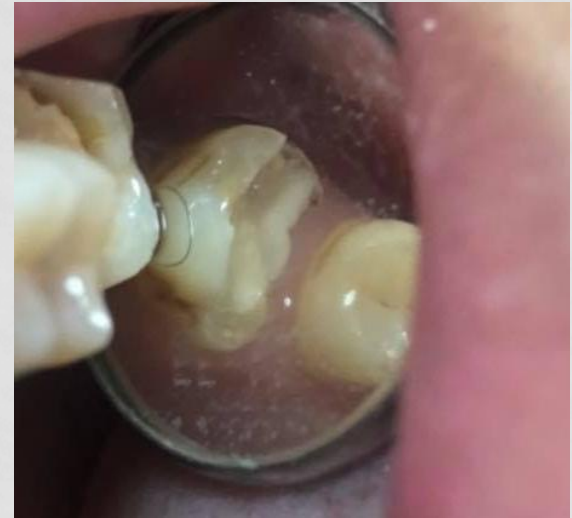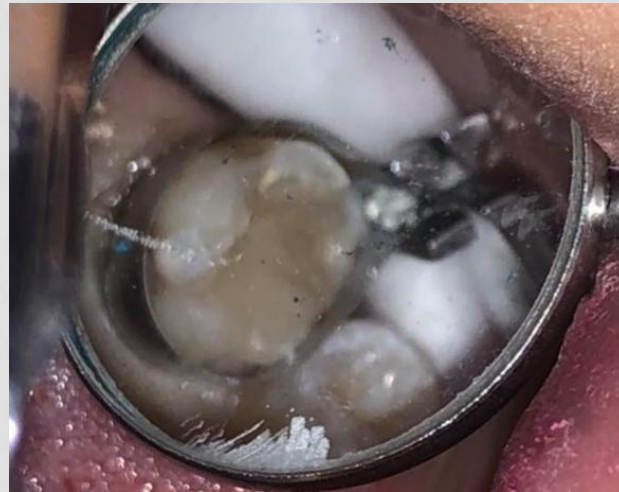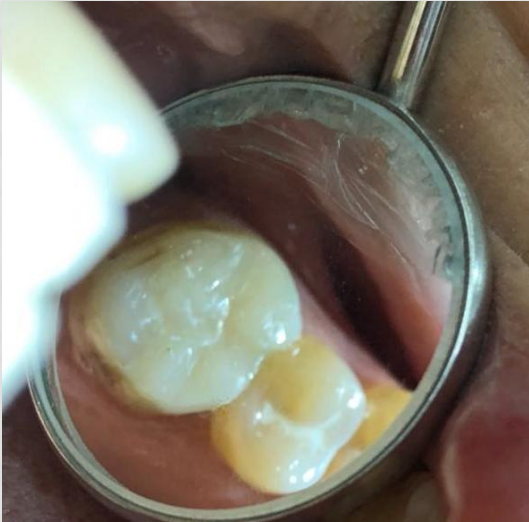TRY IN



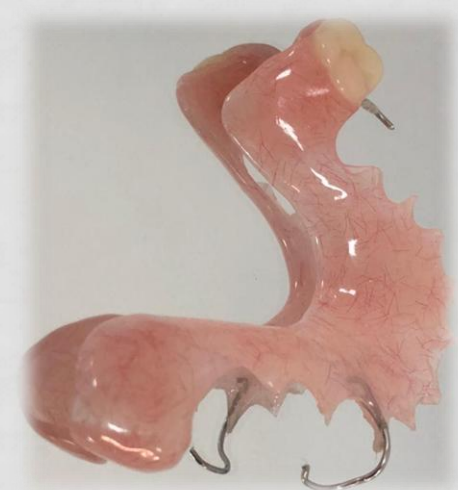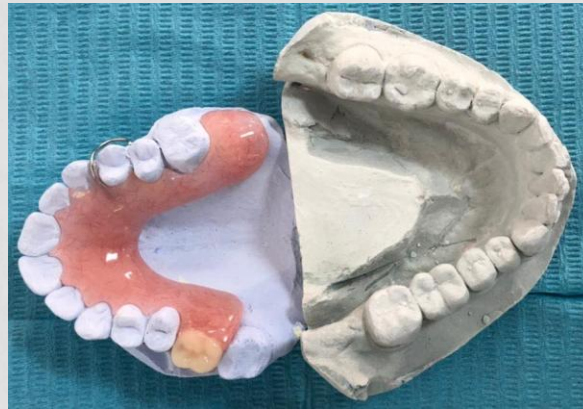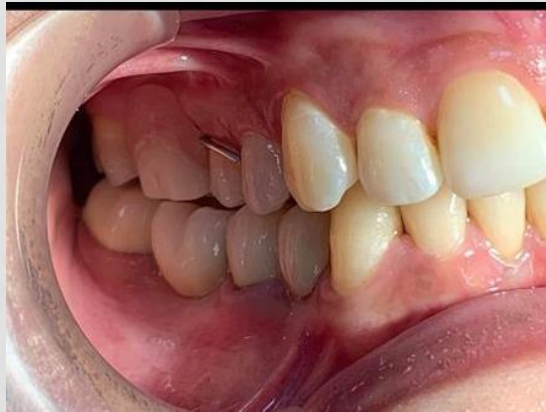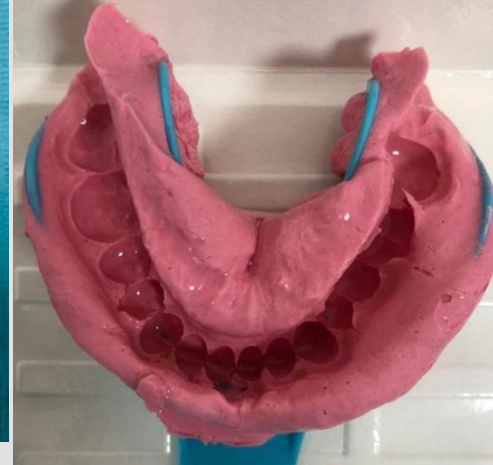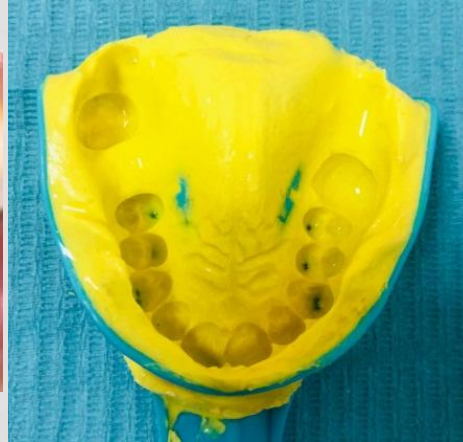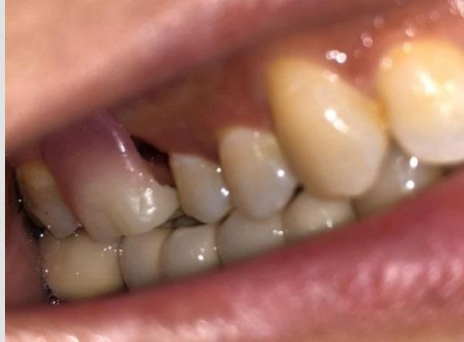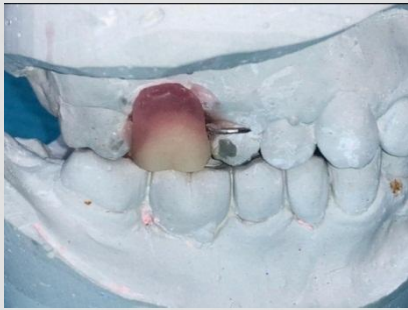INSERTION



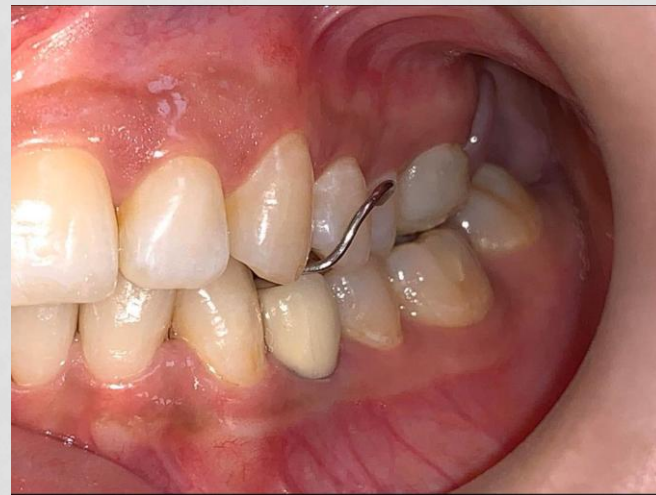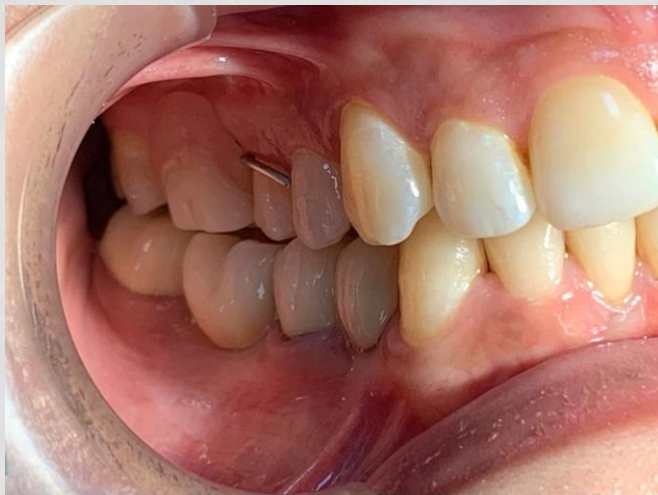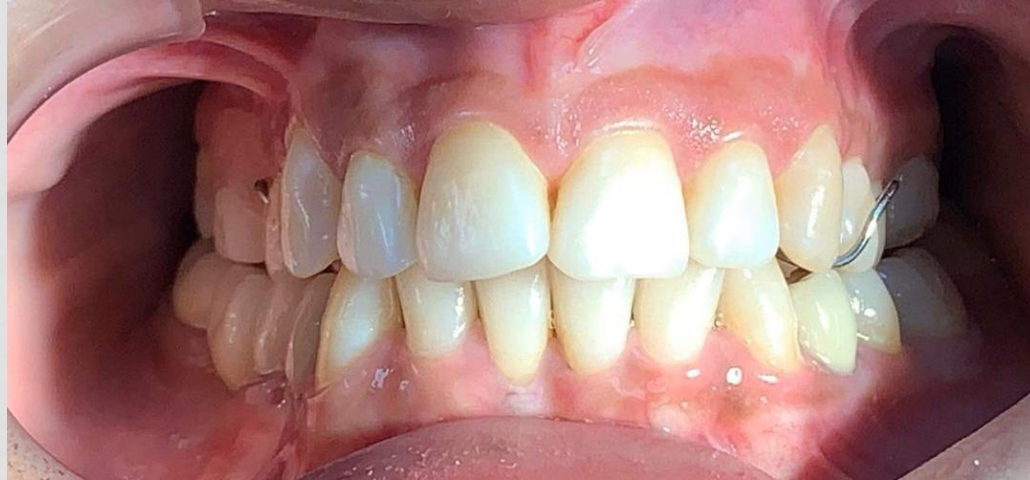BUILD UP COMPOSITE FOR \perp ⁶

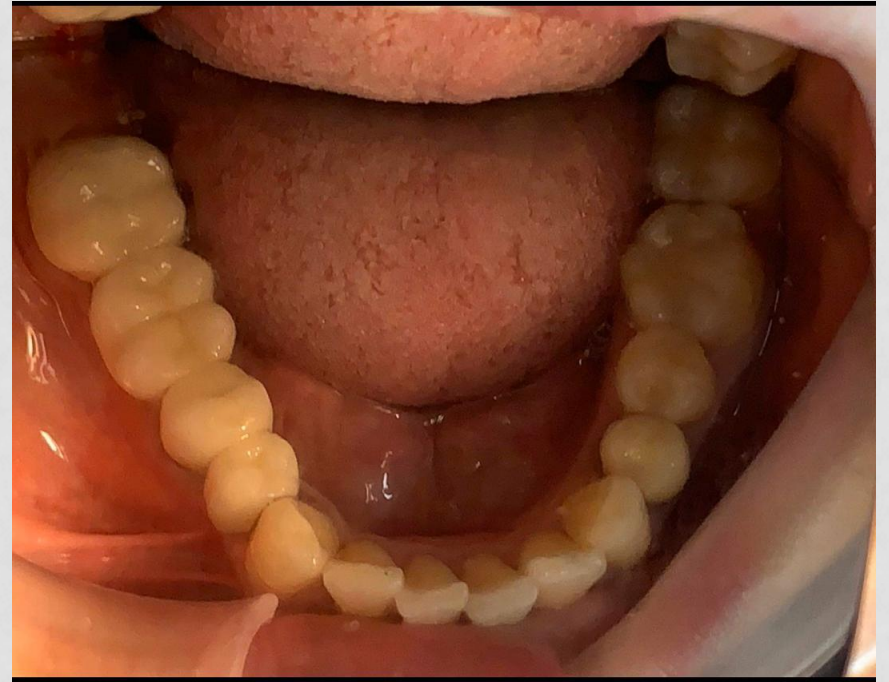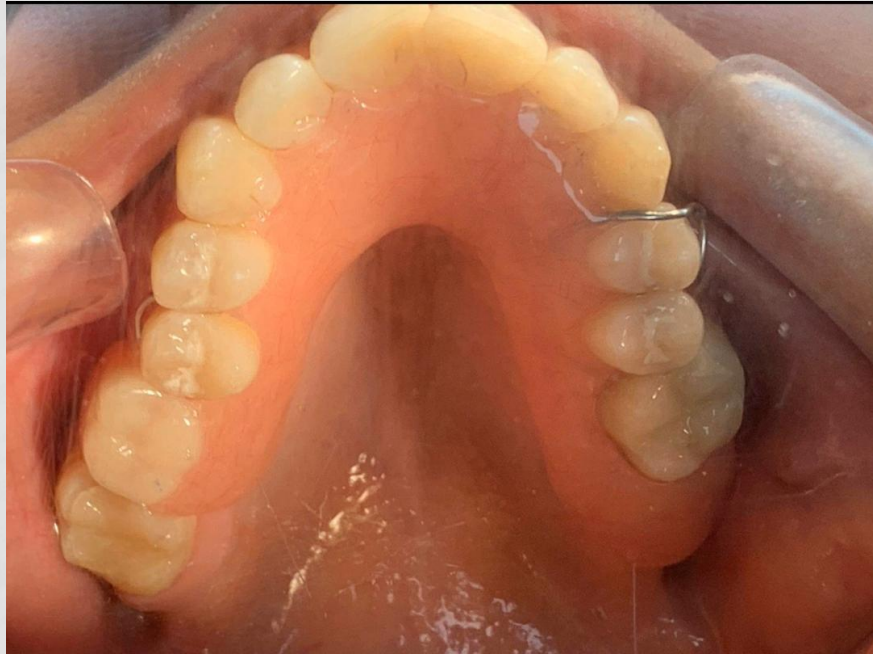


UPPER REMOVABLE PARTIAL ⁶+



AFTER TREATMENT

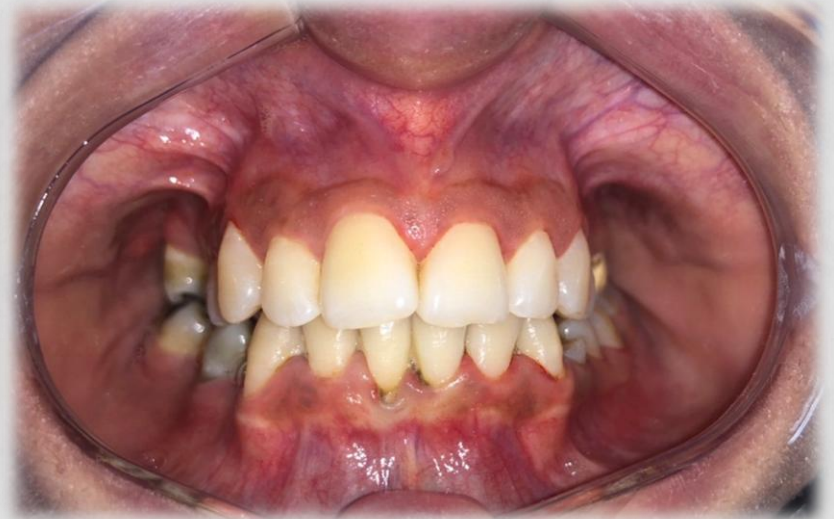
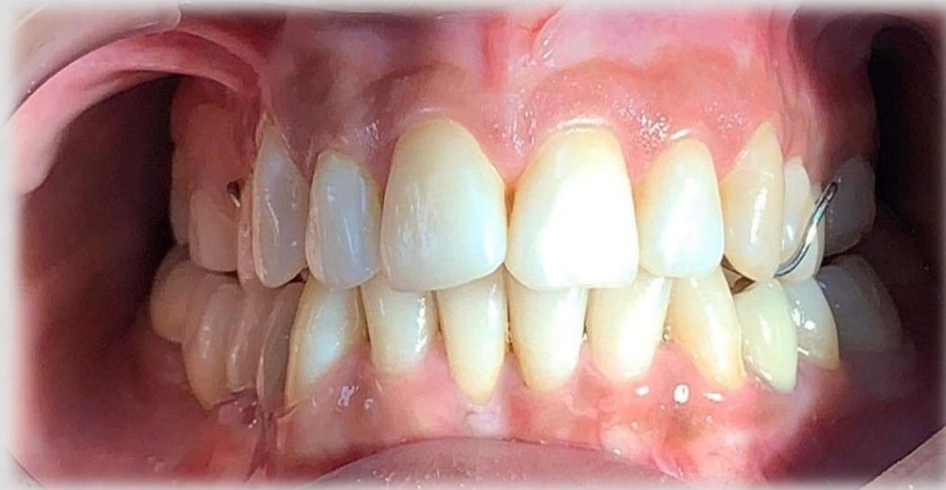


After



Before



Thank
You

