

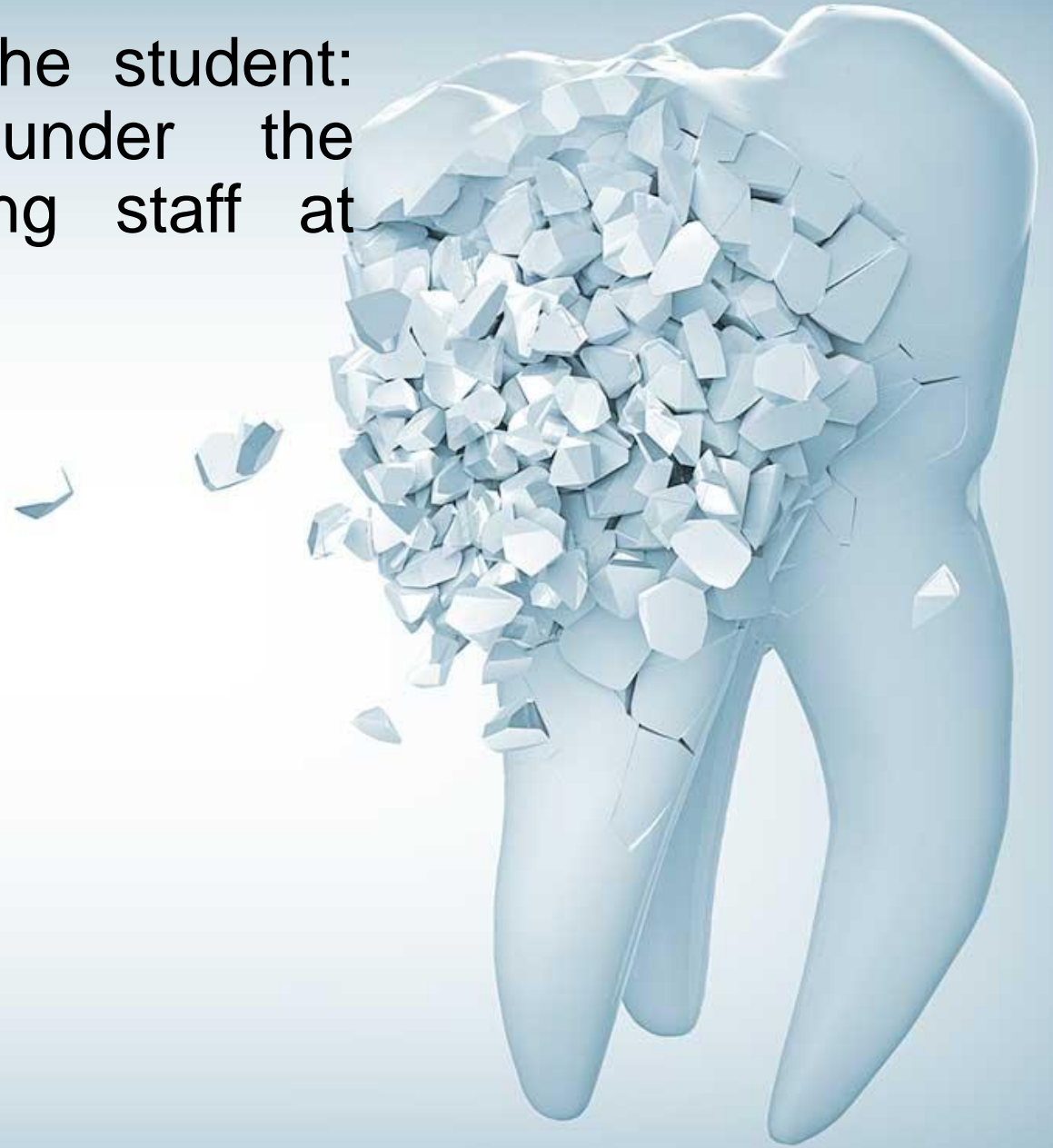
Libyan International Medical University Faculty of Dentistry

- Comprehensive Case Presentation



- The work was achieved by the student: Ahmed Mustafa Aldenali under the supervision of dental teaching staff at LIMU:

- Prof. Sanosi Mohammed.
- Dr. Rafik Alkowafi.
- Dr. Abdelmonem Abdelnabi
- Dr. Masoud Alojaly.
- Dr. Ali Bosnayna.
- Dr. Omer Alhuni.
- Dr. Rabea Alhuni.
- Dr. Abdelsalam Alhadad.
- Dr. Nuha Alkadeki
- Dr. Asma benharez
- Dr. Amal Alawami



Introduction:

Full mouth rehabilitation is defined as the restoration of the form and function of the masticatory apparatus to as nearly a normal condition as possible.

Personal Information:

Name: W.M.A.

Gender: Female.

Nationality: Syrian.

Date of birth: 1955 / 10 / 20

Occupation: House wife.

Address: Almasaken – Benghazi.

History

Chief complain:

Patient attended dental clinic at LIMU to replace her missing upper & lower anterior & posterior teeth that were missing since 3 years ago.

History of chief complain:

Previous extractions were done with no complications.

She gave a history of removable appliance construction in the last year but it wasn't comfortable.

She felt it was moving during speaking & she couldn't tolerate it due to its rocking.

Past & recurrent medical history:

- Medical history: She is hypertensive since 10 years ago / last reading was 130/85mmgh from two days.
- History of hospitalization: Never.
- Medication: Lisinopril 10mg. (ACEI)

Past dental history:

She is symptomatic patient, last visit was 3 months ago for extraction of upper mobile teeth with no complications.

Allergy:

No history of known allergies.

Social history: Married with 8 sons & 3 daughters, not smoker & not alcohol drinker.

Family history: Hypertensive & diabetes running in their family.



Oral hygiene practice:

Brushing: irregular brushing with hard toothbrush.

Brushing method: Horizontal & vertical.

Kind of dentifrice used: Nothing specific.

Clinical Examination:

Extra oral examination:

No swelling or sinus.

Lips: competent.

Face form: Ovoid.

Profile: Straight.

Skin: NAD.

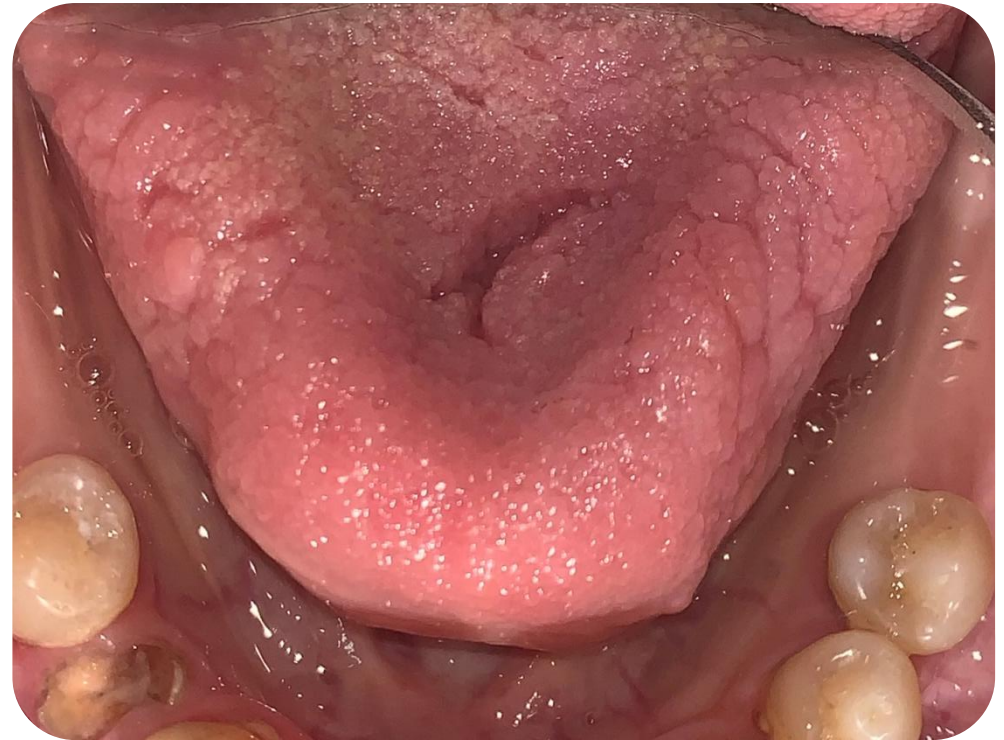
Facial symmetry: Symmetrical.

TMJ: No clicking, not tender,
no deviation, no dislocation.

Lymph node: Not palpable,
not tender.

Intraoral Examination

Soft tissue examination:
Fissured tongue.



Intraoral Examination

Soft tissue examination:

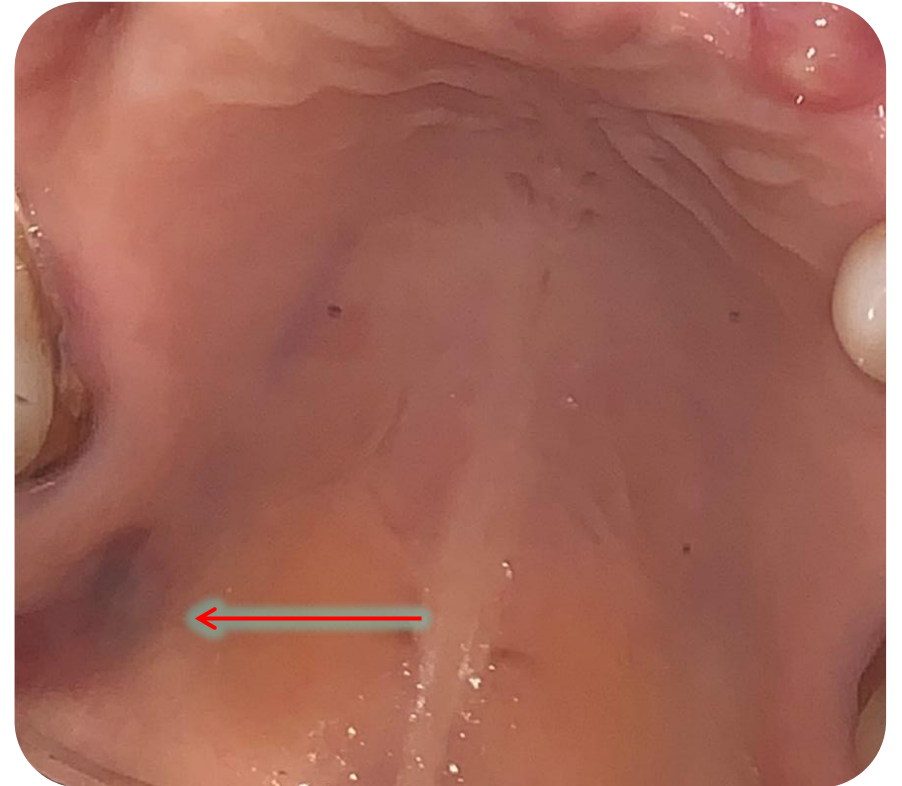
On clinical examination there was solitary pigmented macule posterior to the tuberosity.

It was clearly demarked from the surrounding normal mucosa.

Ovoid in shape about 8mmx5mm.

Reddish brown in color.

Smooth surface, no ulcer or erosion or surface necrosis.



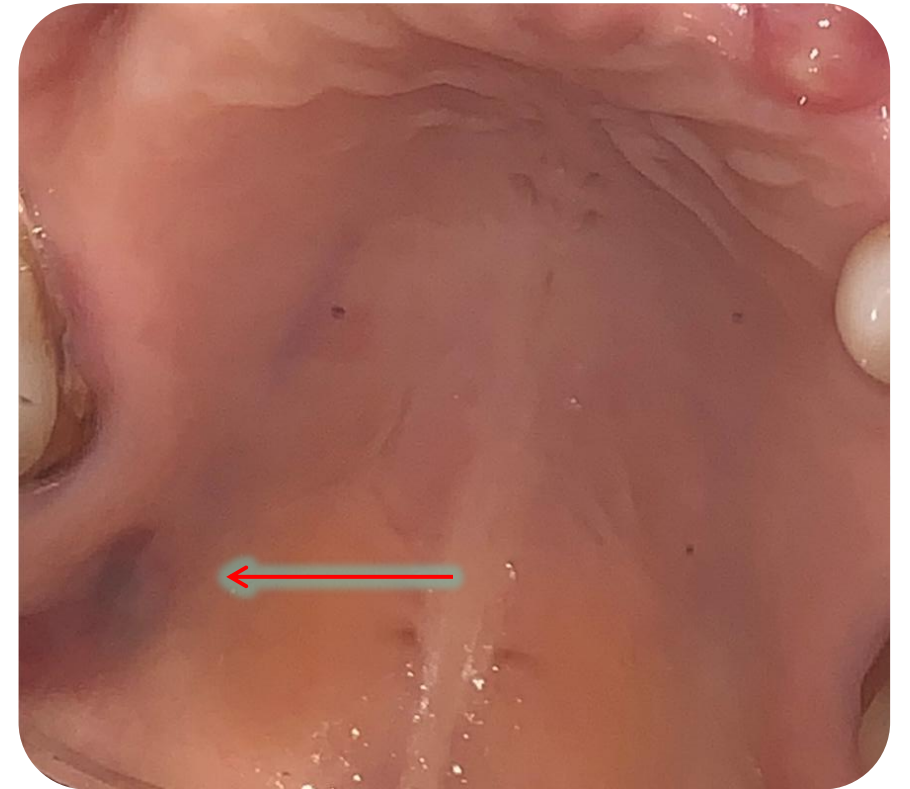
Intraoral Examination

Soft tissue examination:

On palpation it was not tender, not blanching on pressure.

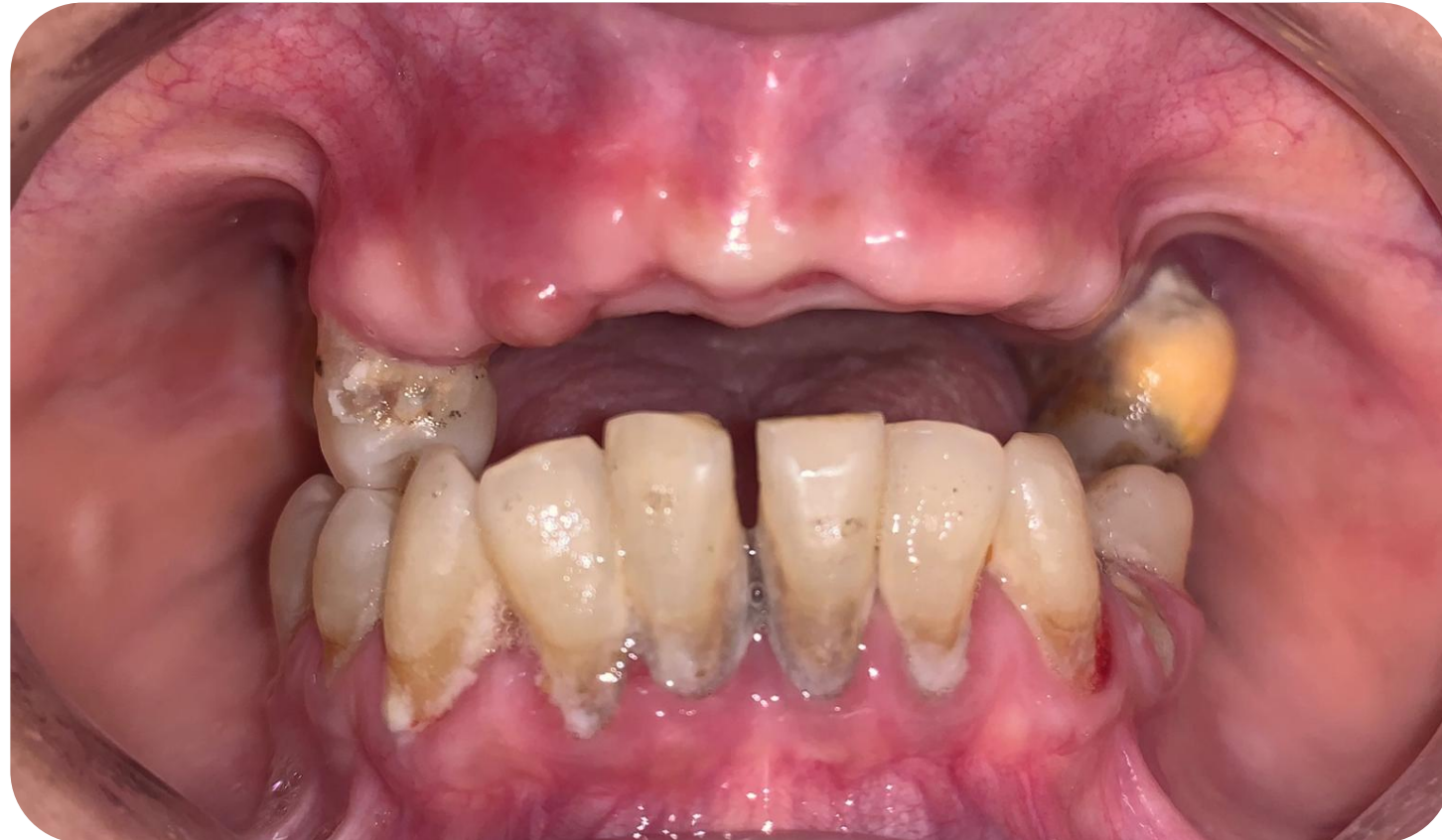No destruction detected to the underlying supporting bone.

Patient wasn't aware of the lesion.



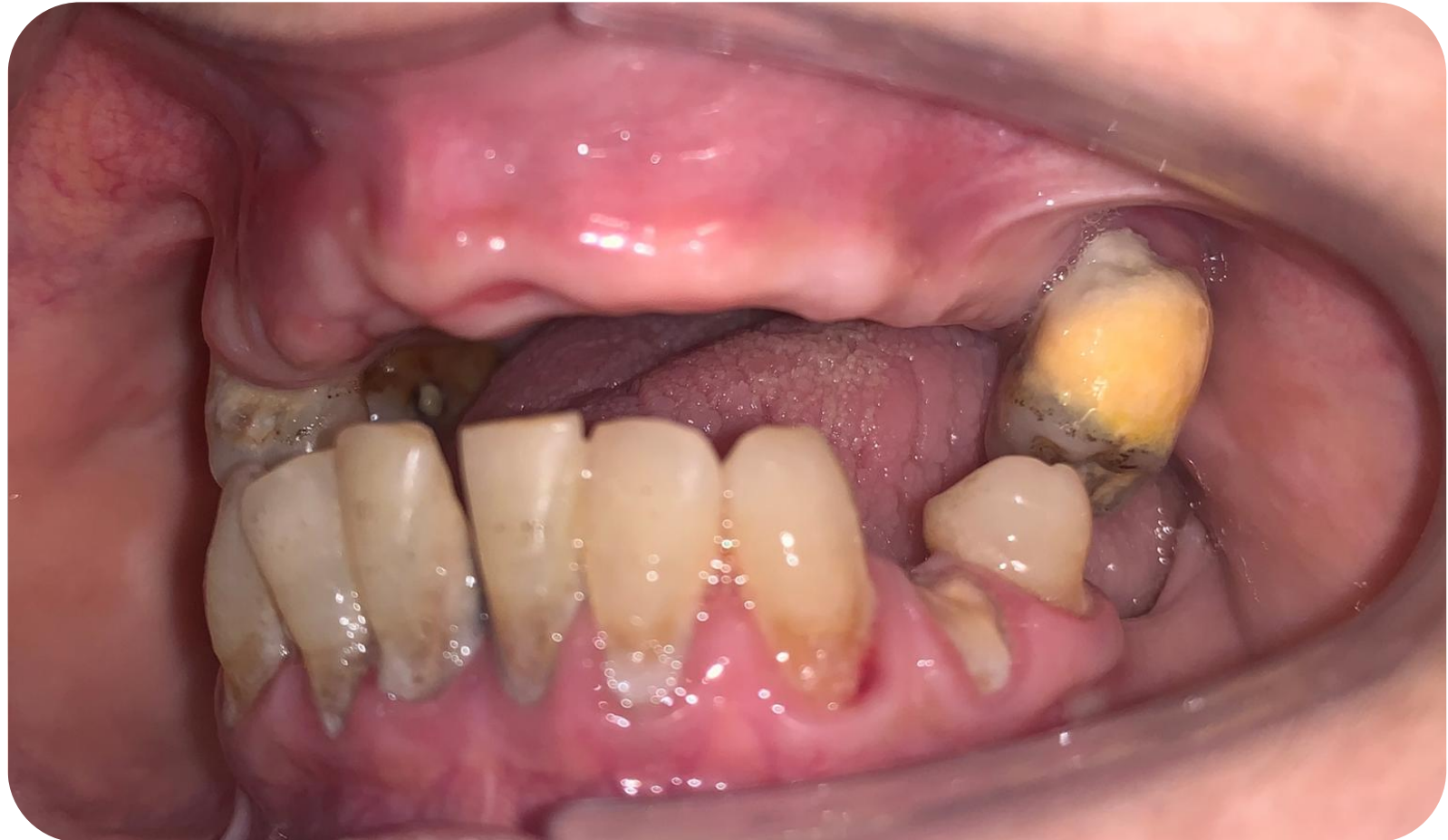Intraoral Examination

Hard tissue examination: Frontal view.



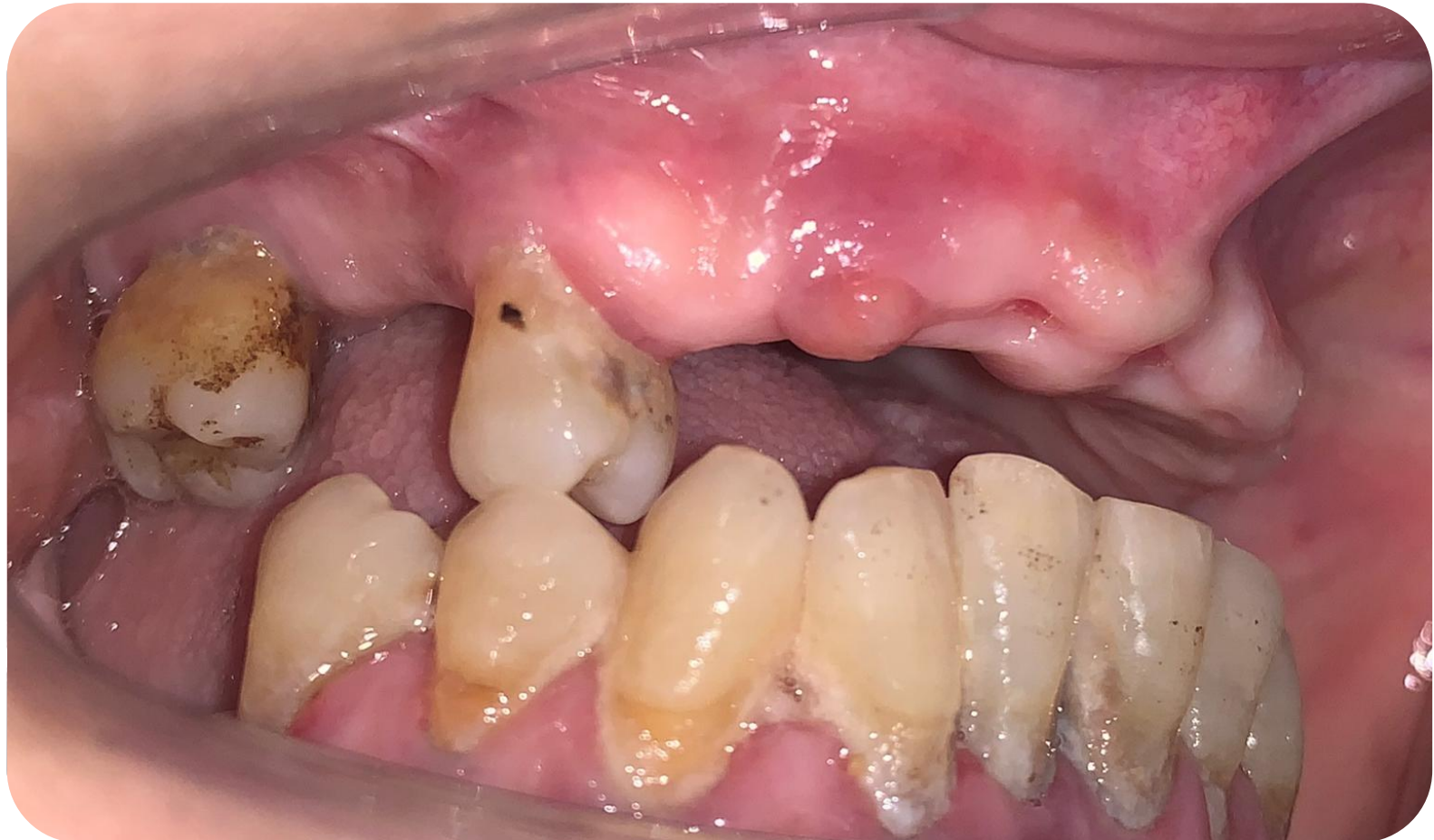Intraoral Examination

Hard tissue examination: Lt lateral view.



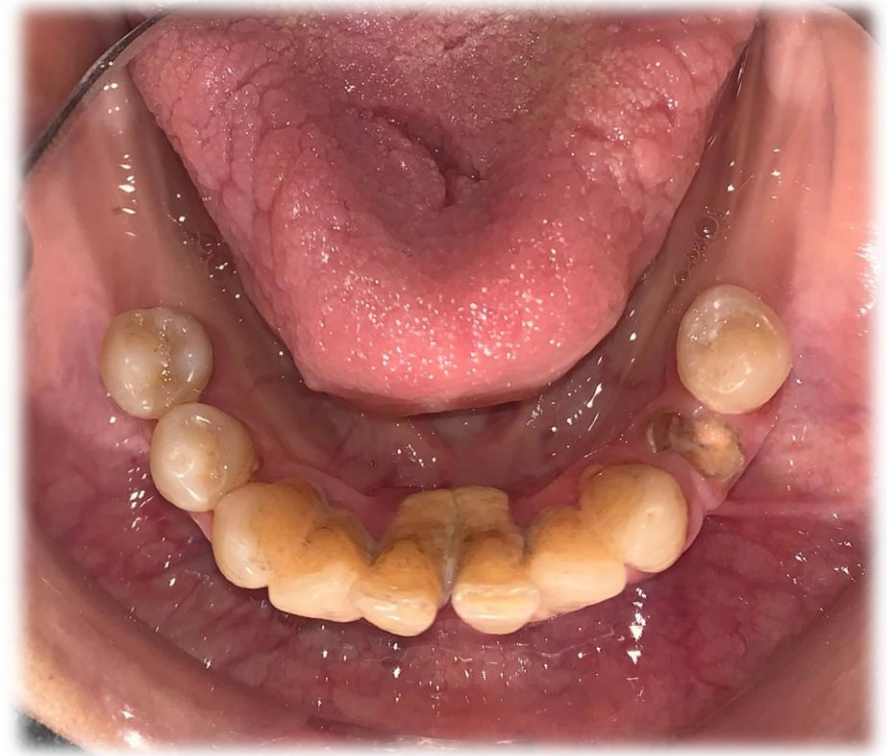Intraoral Examination

Hard tissue examination: Rt lateral view.



Intraoral Examination

- **Hard tissue examination:**
- Mandibular arch.



8	7	6	5	4	3	2	1	1	2	3	4	5	6	7	8
M	M	M									R.R		M	M	M

Dental status:

- Teeth present:

4321	123 5
------	-------

- Carious teeth:

7 4 2	7
	4

- Restored teeth:

--	--

- Missing teeth:

65 3 1	123456
76	67

DMFT:

$$5 + 14 + 0 = 19. \text{ high score}$$

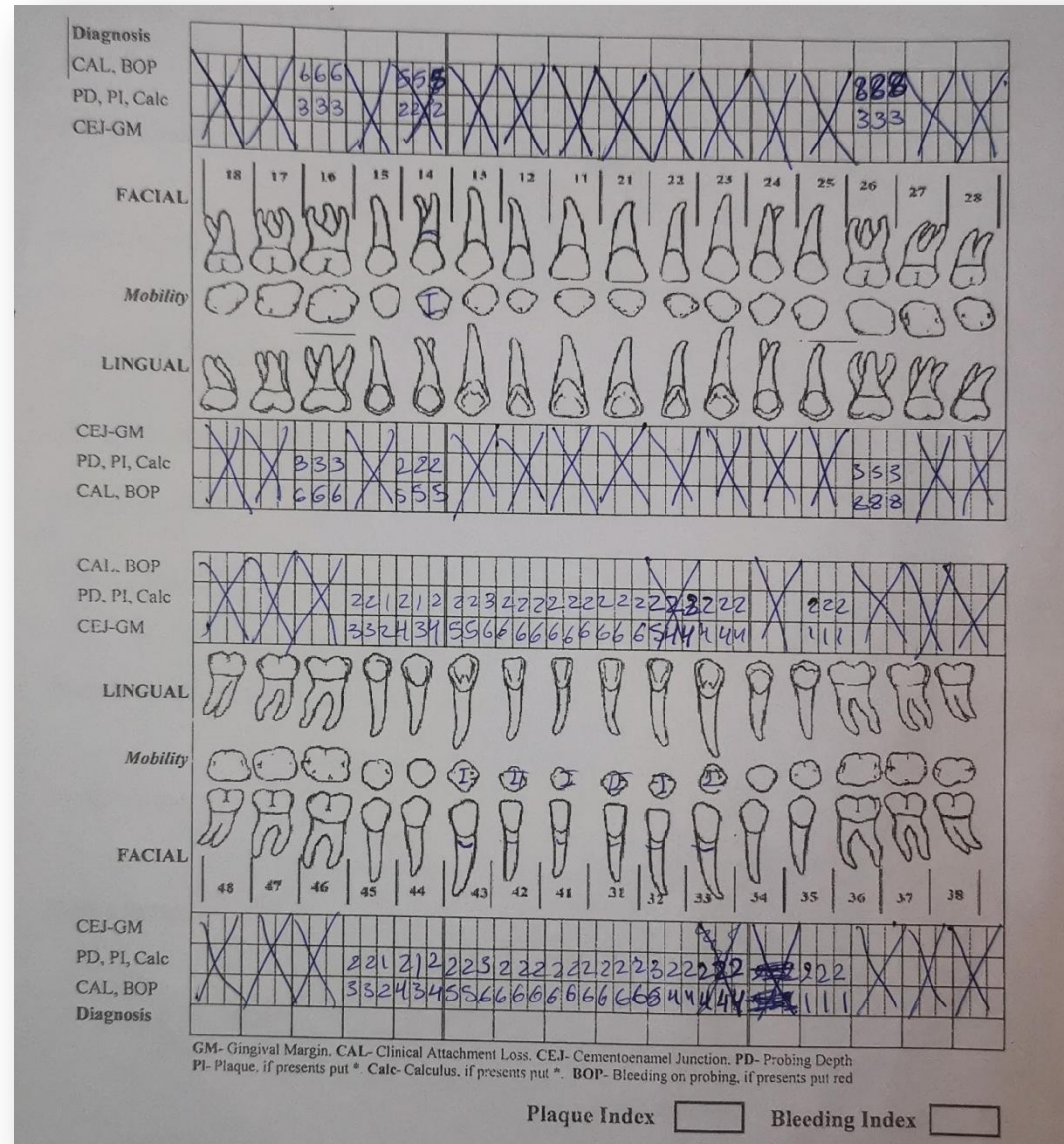
Gingival Status:

	Max. Right Posterior	Max. Anterior	Max. Left Posterior
Color	Red	Red	Red
Contour	Round edge with blunt IDP.		Round edge with blunt IDP.
Size	No enlargement.	No enlargement.	No enlargement.
Consistency	Soft and edematous	Soft and edematous	Soft and edematous
Stippling	Absent	Absent	Absent
Position	Apical to CEJ		Apical to CEJ
Bleeding	Present	Present	Present
Exudation	Absent	Absent	Absent

Gingival Status:

	Man. Right Posterior	Man. Anterior	Man. Left Posterior
Color	Red	Red	Red
Contour	Round edge with blunt IDP.	Round edge with blunt IDP.	Round edge with blunt IDP.
Size	No enlargement.	No enlargement.	No enlargement.
Consistency	Soft and edematous	Soft and edematous	Soft and edematous
Stippling	Absent	Absent	Absent
Position	Apical to CEJ	Apical to CEJ	Apical to CEJ
Bleeding	Present	Present	Present
Exudation	Absent	Absent	Absent

Periodontal Status



Adequacy of attached gingiva:

Fremitus test: -ve.

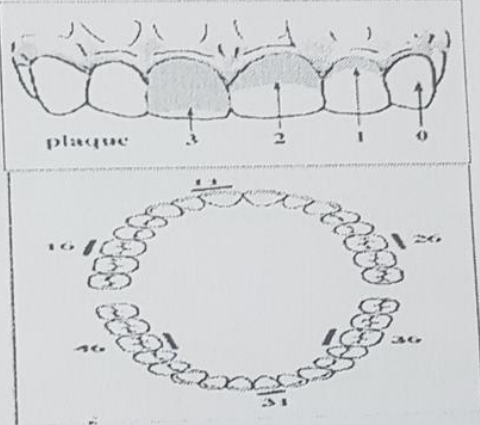
Frenal attachment: Normal.

Halitosis: Present.

Oral Hygiene

Oral Hygiene Index-Simplified:

16	11	26
3	/	3
/	3	/
46	31	36



16	11	26
2	X	2
X	2	X
46	31	36

Plaque Index = $\frac{9}{6} = 1.5$

OHI-S = + =

Good (0-1.2),

Fair (1.3-3),

Poor (3.1-6)

Calculus Index = $\frac{6}{6} = 1$

OHI-2 = + =

Plaque Index = $\frac{9}{6} = 1.5$

Good (0-1.2),

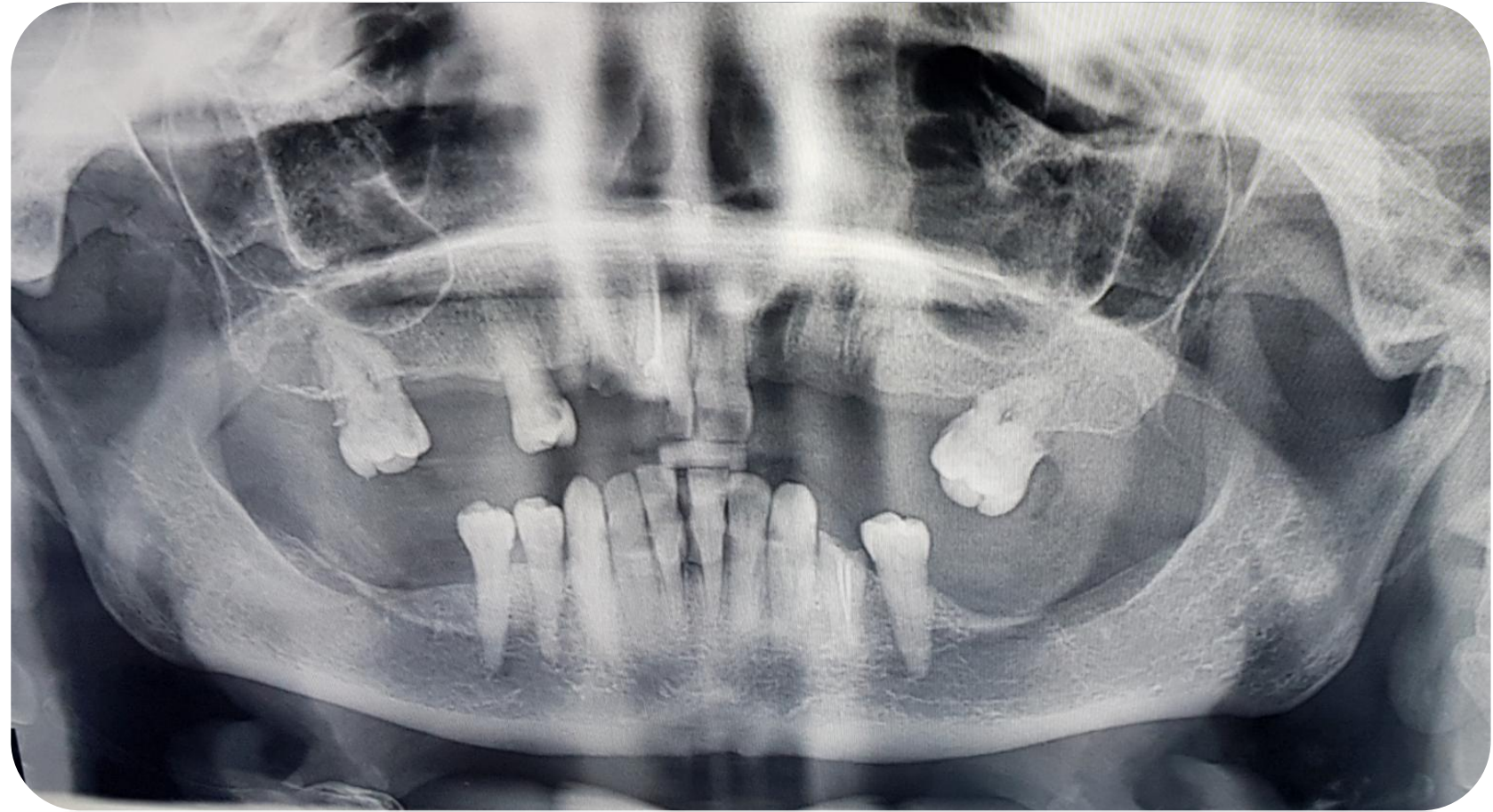
Fair (1.3-3),

Poor (3.1-6)

Calculus Index = $\frac{6}{6} = 1$

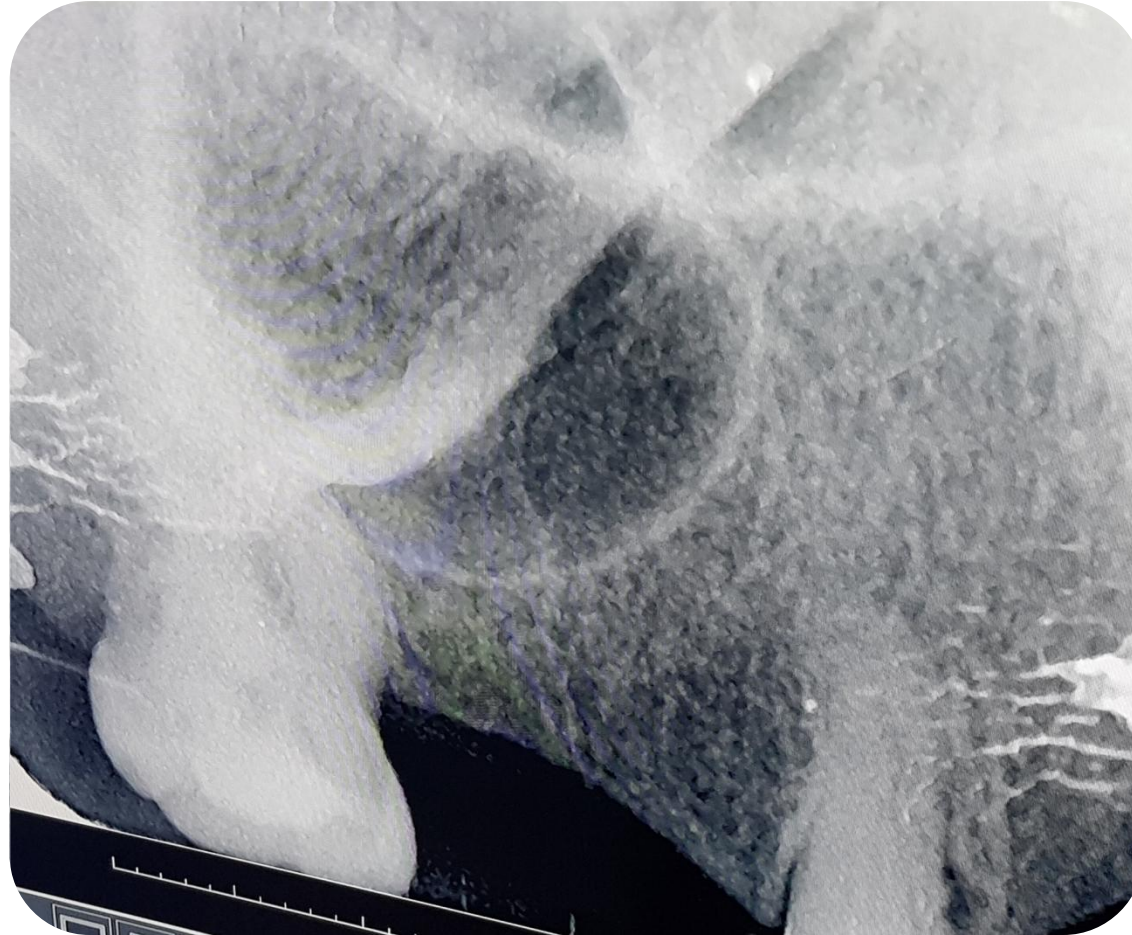
Investigation

OPG



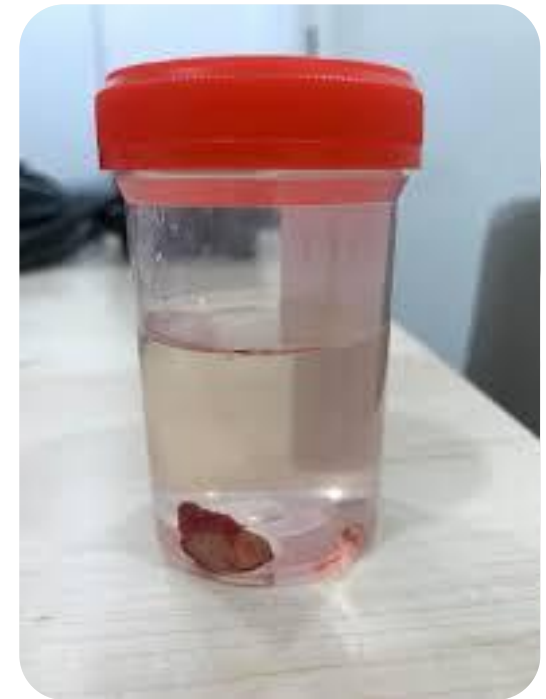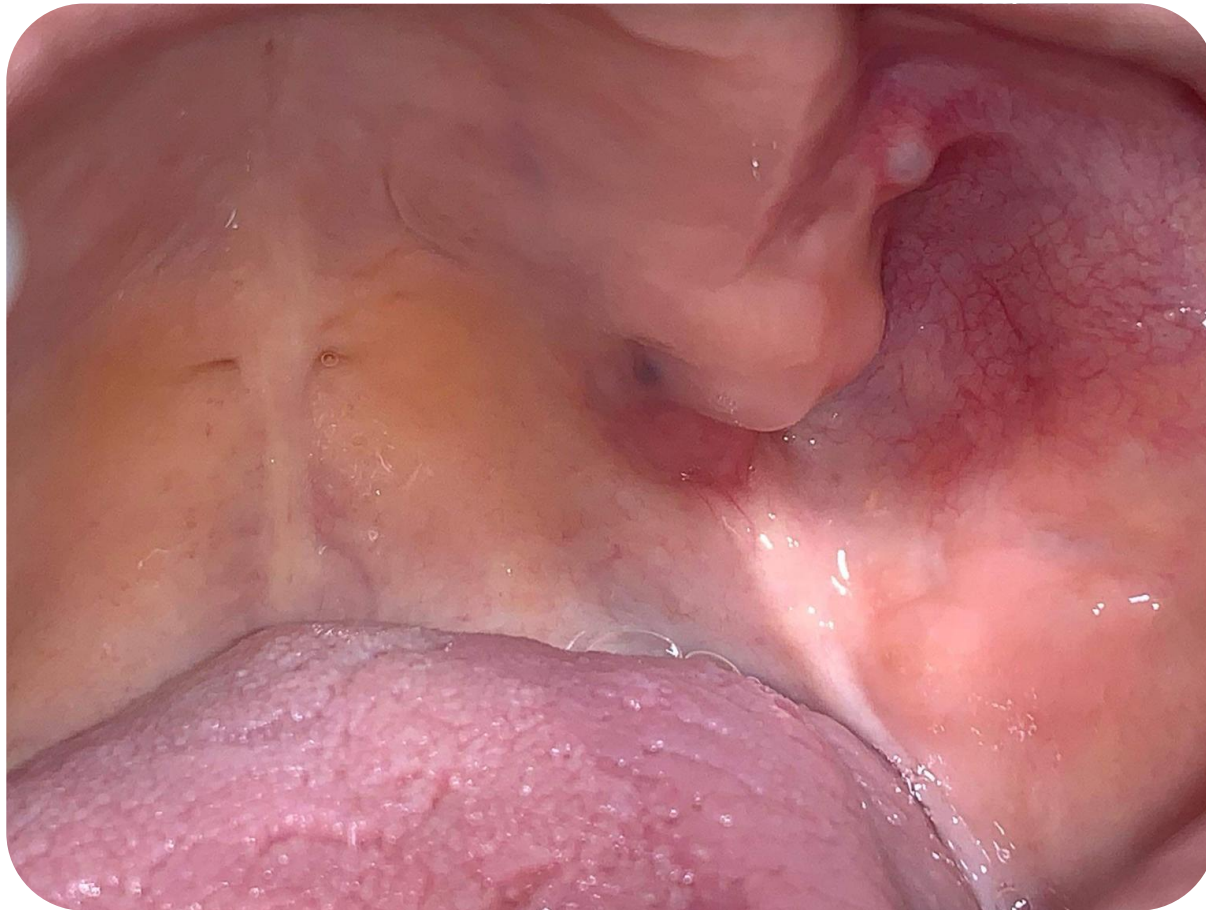
Investigation

IOPA



Investigation

Excisional biopsy.



Gross examination:

Two tiny soft tissue pieces

Microscopic examination:

The section shows benign hyperplastic squamous epithelium with underlying fibrous stroma contains large foci of hemorrhage and few inflammatory cells, no malignancy

Final diagnosis:

Benign squamous epithelium with secondary hemorrhage, no malignancy

Final Diagnosis

Regarding to chief complain:

- Class III mod 2 in upper arch.
- Class I in lower arch.

Generalized moderate to sever chronic periodontitis.

Final Diagnosis

Carious teeth:

•Mesial caries: $\frac{4}{\quad}$

•Occlusio distal caries: $\frac{7}{\quad} \mid \frac{7}{\quad}$

•Remaining roots: $\frac{2}{\quad} \mid \frac{4}{\quad}$

Treatment plan:

- **Emergency phase:** No need.

- **Phase I:**

- OHI + scaling & localized root planning
- Fluoride application.

- **Re-evaluation of phase I.**

- **Phase II:**

- Extraction of R.R $\frac{2}{4}$ & $\frac{7}{7}$
- Alveoplasty of upper left alveolar ridge “Maxillary tuberosity”

- **Phase III:**

- Filling $\frac{4}{}$ & replacement missing teeth.

- **Phase IV:**

- Maintenance & recall.

Inform Consent

الجامعة الليبية الدولية للعلوم الطبية

كلية طب وجراحة الفم والأسنان

موافقة للأذن بالعلاج

أقر أنا / بطاقة شخصية رقم:

ويكامل ارادتي أنني أعطي موافقتي اللفظية والكتابية للبدء والاستمرار في العلاج بعيادات كلية طب الأسنان بالجامعة الليبية الدولية للعلوم الطبية والذي يتضمن

..... فليع + علاج اللثة + طاقم + جنس نبي مدخر لسنة

وقد تم شرح التشخيص المرضي لحالتي والخيارات المختلفة المتوفرة لمعالجتها والأعراض الجانبية والمخاطر التي قد تصاحب العلاج والمشاكل التي قد تنتج عن عدم العلاج والمدة التقريبية اللازمة للانتهاء منه والتكلفة الاجمالية للعلاج وفقا للرسوم الرمزية المقررة كما اتفهم ان هذا العلاج قد تم تنفيذه من قبل طالب أو طبيب امتياز تحت الاشراف المباشر لأعضاء هيئة التدريس بالكلية.

أسم المريض:

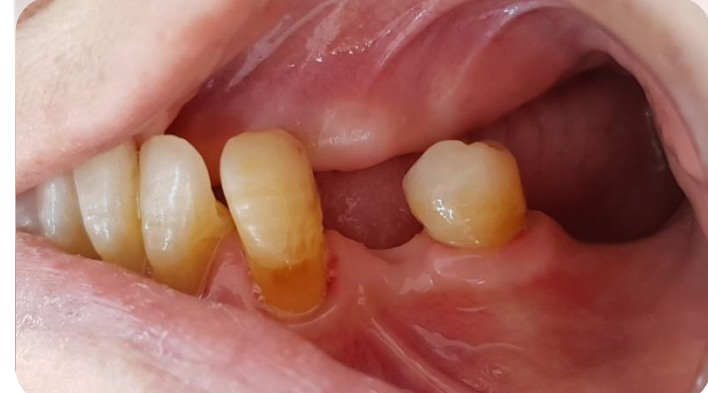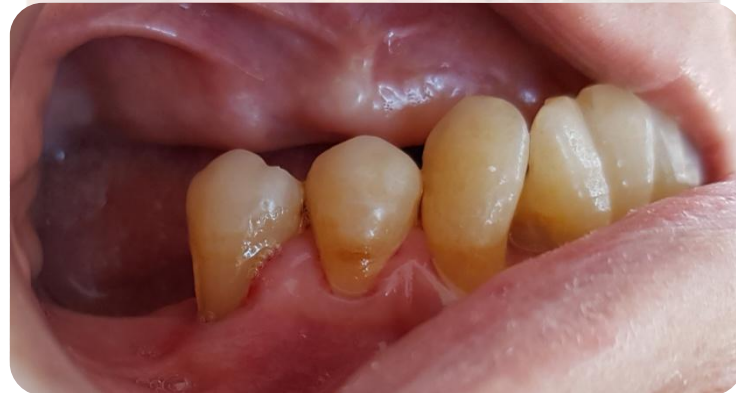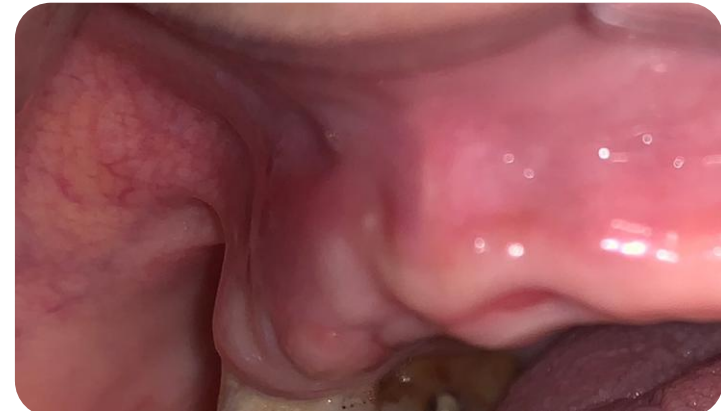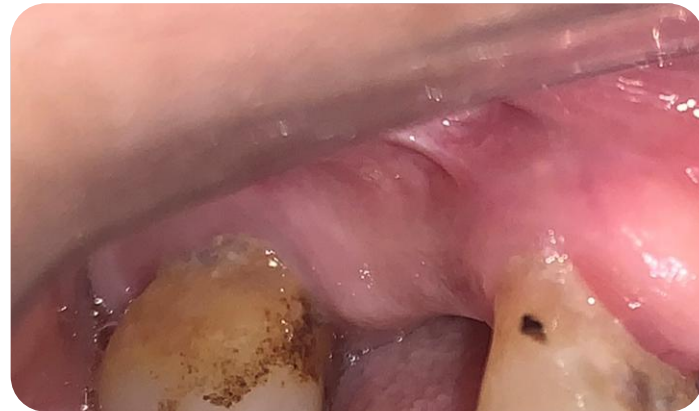توقيع المريض: 

اسم الطالب أو طبيب الامتياز: 

الأستاذ المشرف:

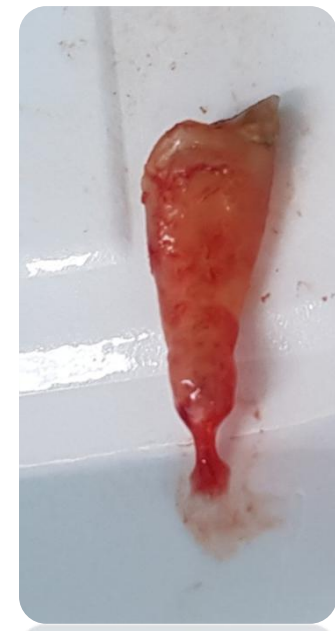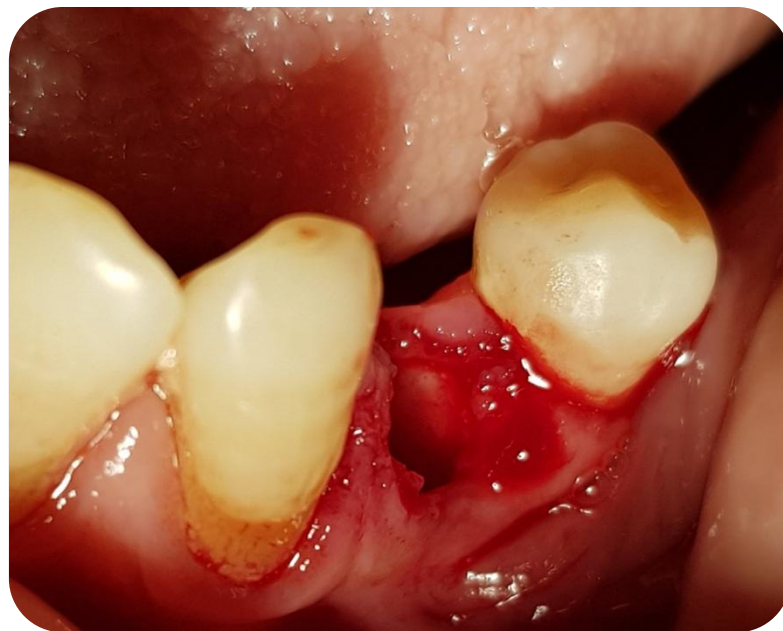
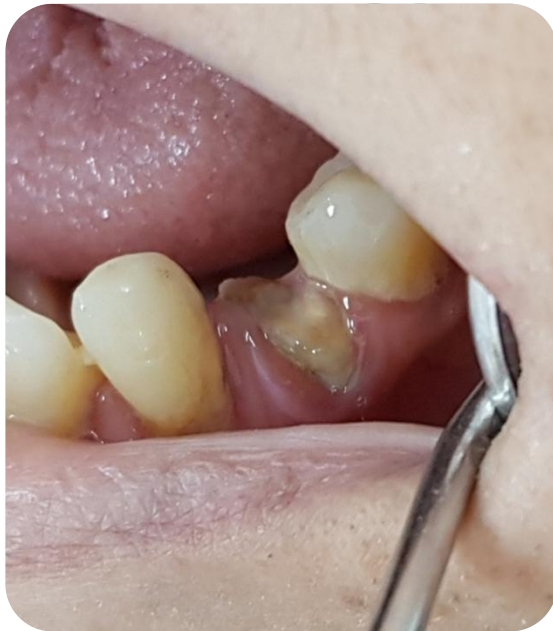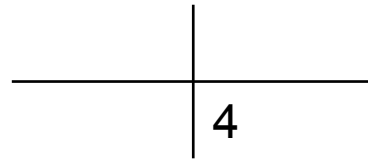
Phase I

OHI + scaling & localized root planning



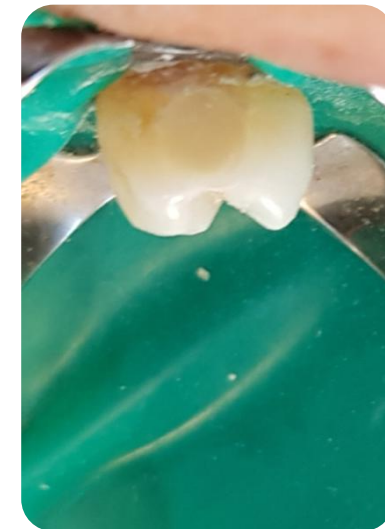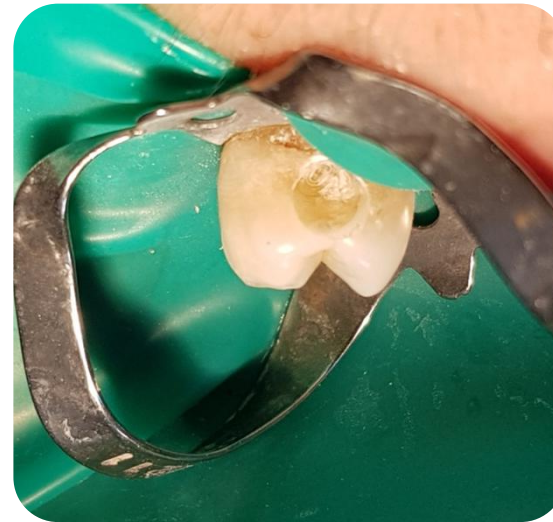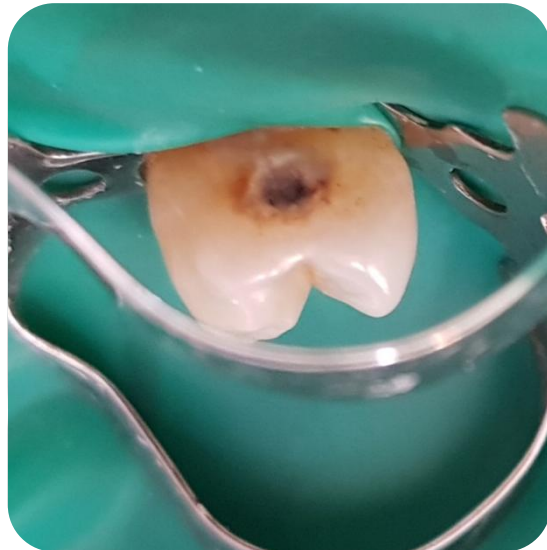
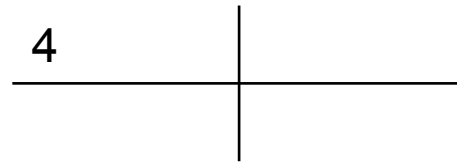
Phase II

Extraction of R.R



Phase II

Deep caries lesion management (Indirect pulp capping)



نوع الوجبة	المأكولات والمشروبات	الساعة	الأيام
فطور	سكينة	7:00	الخميس
فطور	قهوة + كيلة	9:00	
غداء	قهوة + طاغوت	11:30	
غداء	سكينة	1:30	
عشاء	رز بالخلطة + موالج + قزوة + ماء	8:00	الجمعة
عشاء	سكينة	12:00	
فطور	سكينة	9:30	
غداء	سكينة + سلاطة + ماء	1:00	
عصير	قهوة + سويان + ساق + عصير	5:00	السبت
عصير	سكينة	10:00	
فطور	قهوة + كيلة	9:00	
غداء	مكرونة أميرة سلاطة	1:30	
عصير	قهوة + كيلة + سلاطة	4:30	
عشاء	عصير + ساق	8:30	

طلب رفض خطة علاج

اقراءنا اللهوا طنه و [REDACTED] أن ارسله خلع ما تبقى من أخصائي
العلوية زهدراً الأني أرفض علاج حشو العصب أو الحشو الوقائي
وأرغب باستبدال الهند بطاقتهم علوي متحرك زهدراً بما تخرجت له
من مشاكل من فترة بعيدة من حشوه عصب اسنان الذي بسبب
لبي مشاكل عديدة لذلك تم رفقة وأتحمّل المسؤولية الكاملة
وما يتربّط عليه من تكاليف مادية ومشاكل مستقبلية في مستوى
الدخلم للفك العلوي فيما يخص الحالة الشاملة للطالب
المد محمد مصطفى حامد محمد الدينالي .

مقدمة الطالب :-

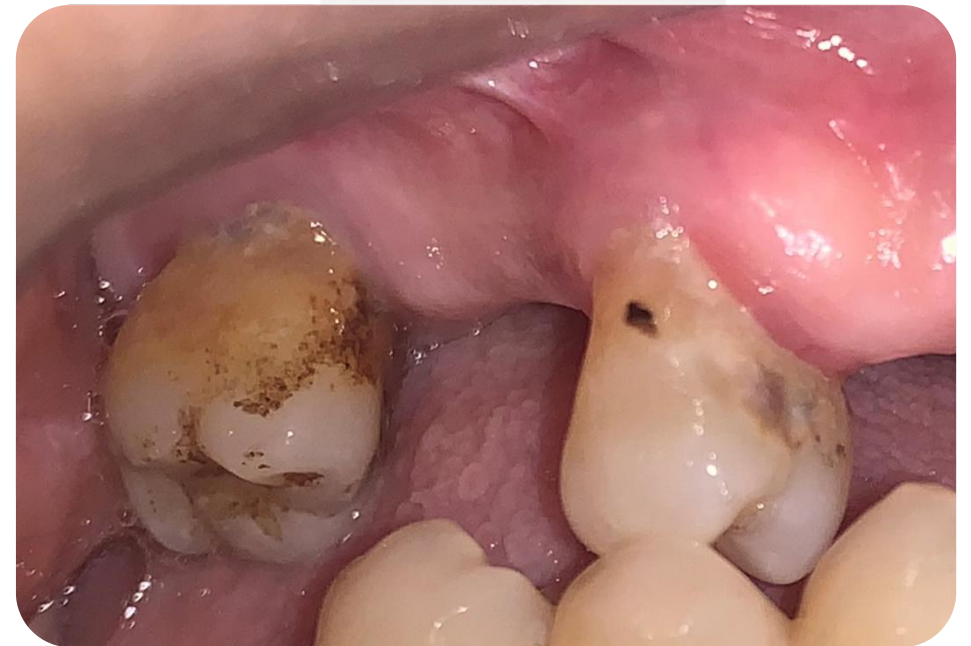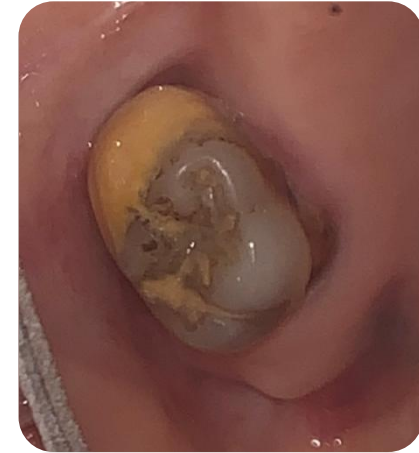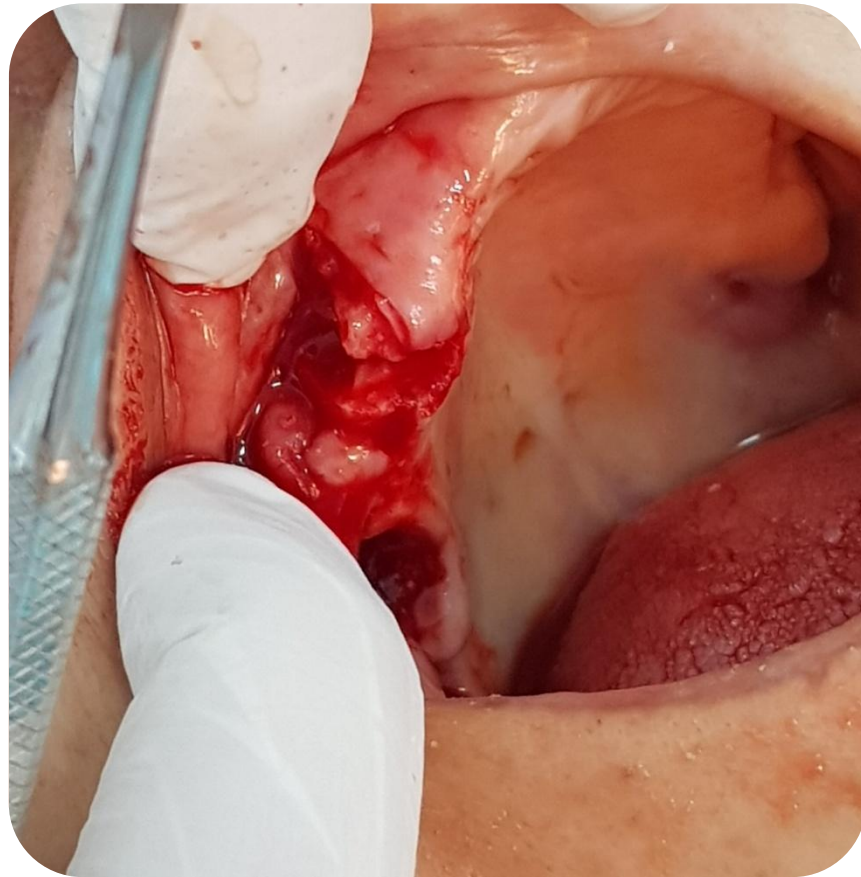
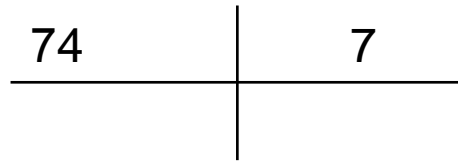
[REDACTED]

60 عا

السكن المسائل الجاهزة

2019/10/15

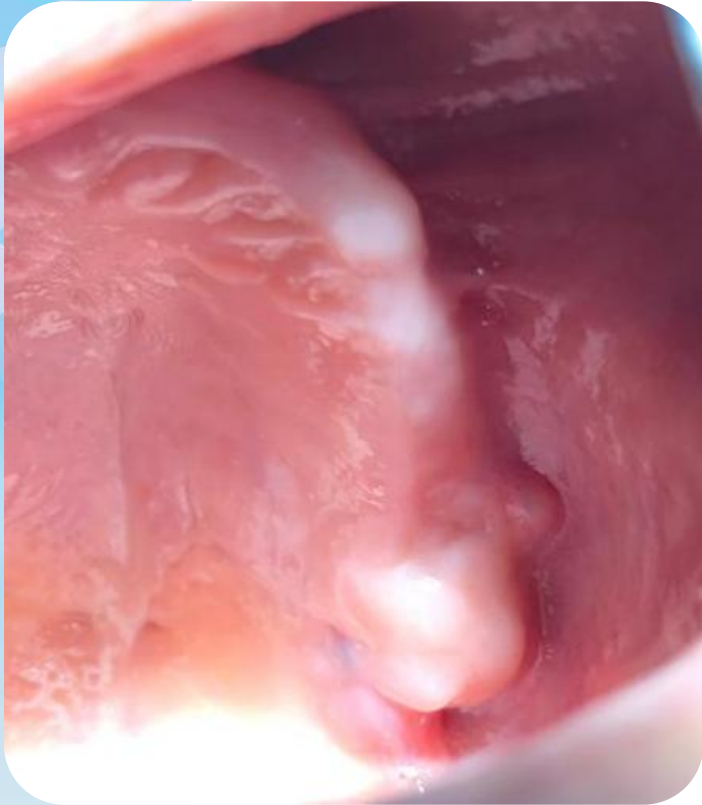
Phase II



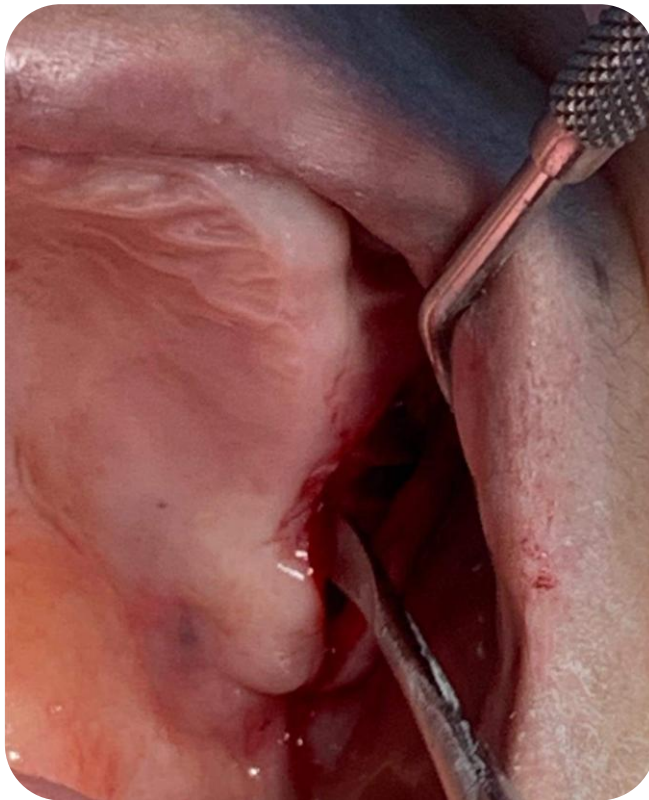
Phase II

Alveoplasty of upper left alveolar ridge.

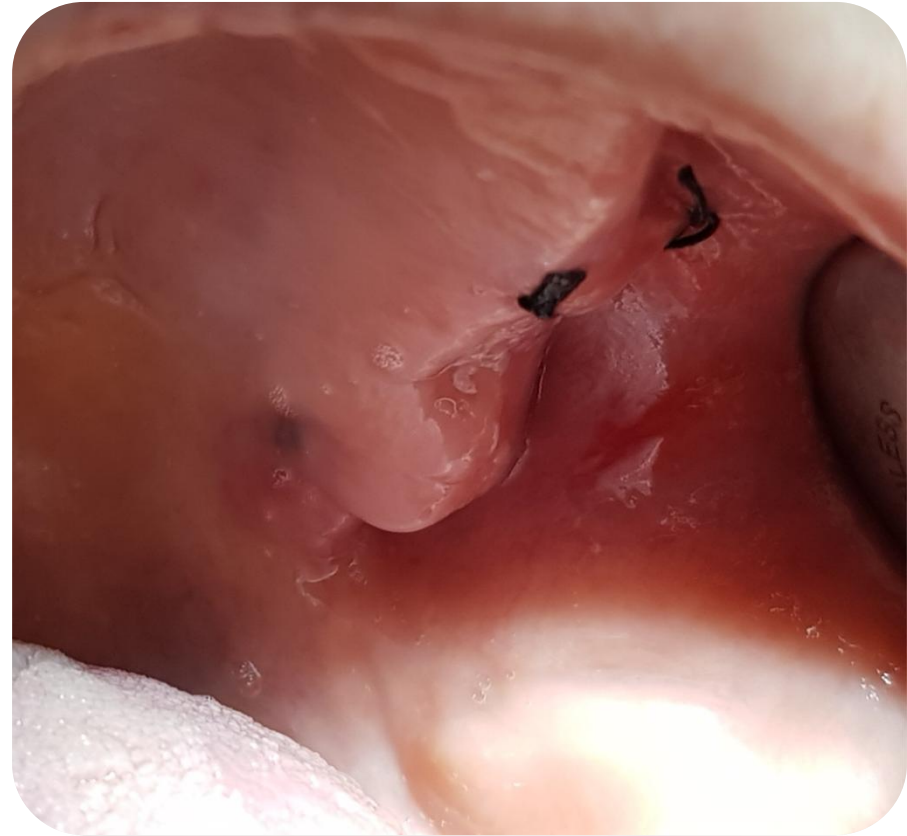Before



During



After



Phase III

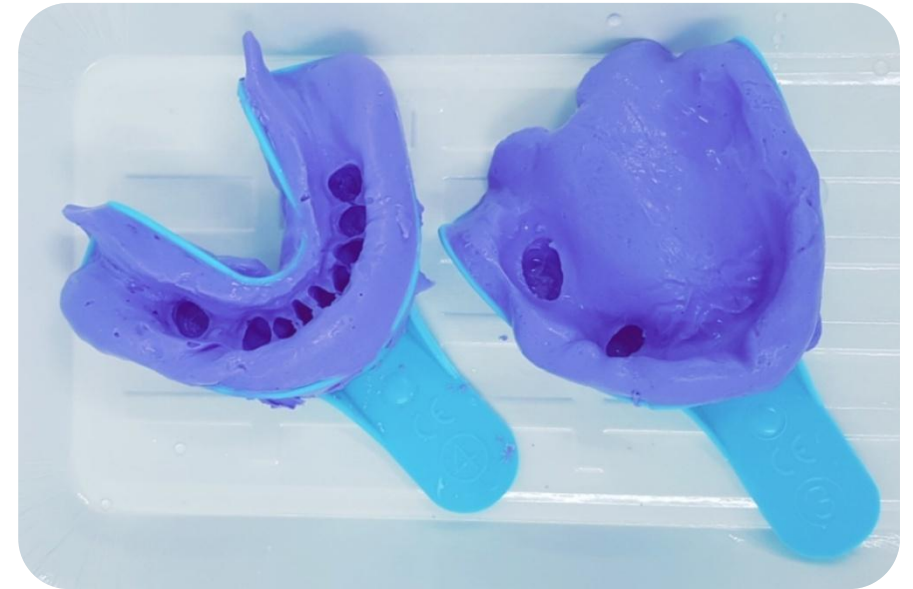Replacement missing teeth (Options):

- Replacement with implant prostheses.
- Cobalt chromium RPD.
- Acrylic RPD.

Phase III

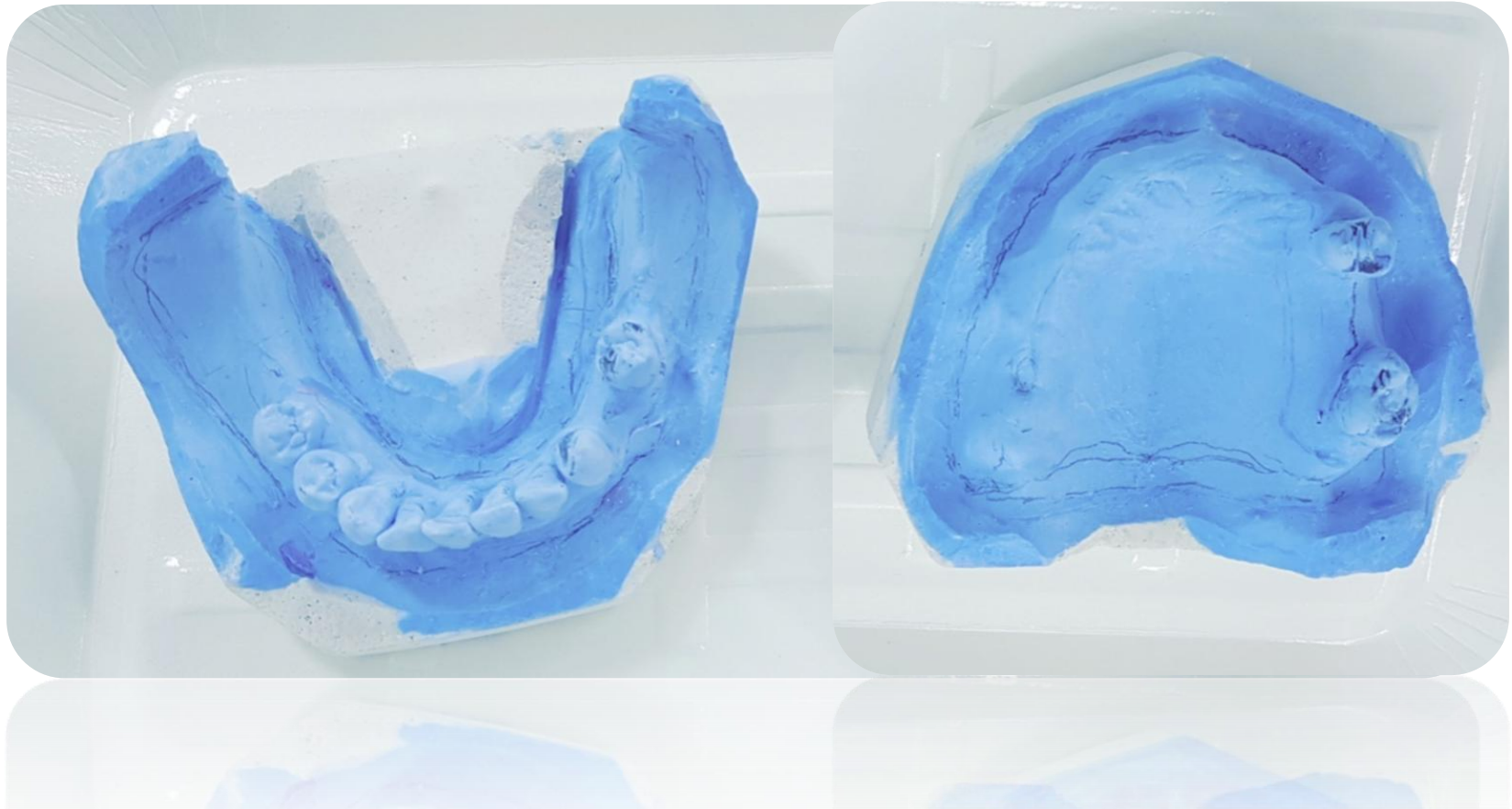
Replacement of missing teeth with cast metal

Cobalt chromium RPD



Phase III

Replacement missing teeth with
Cobalt chromium RPD



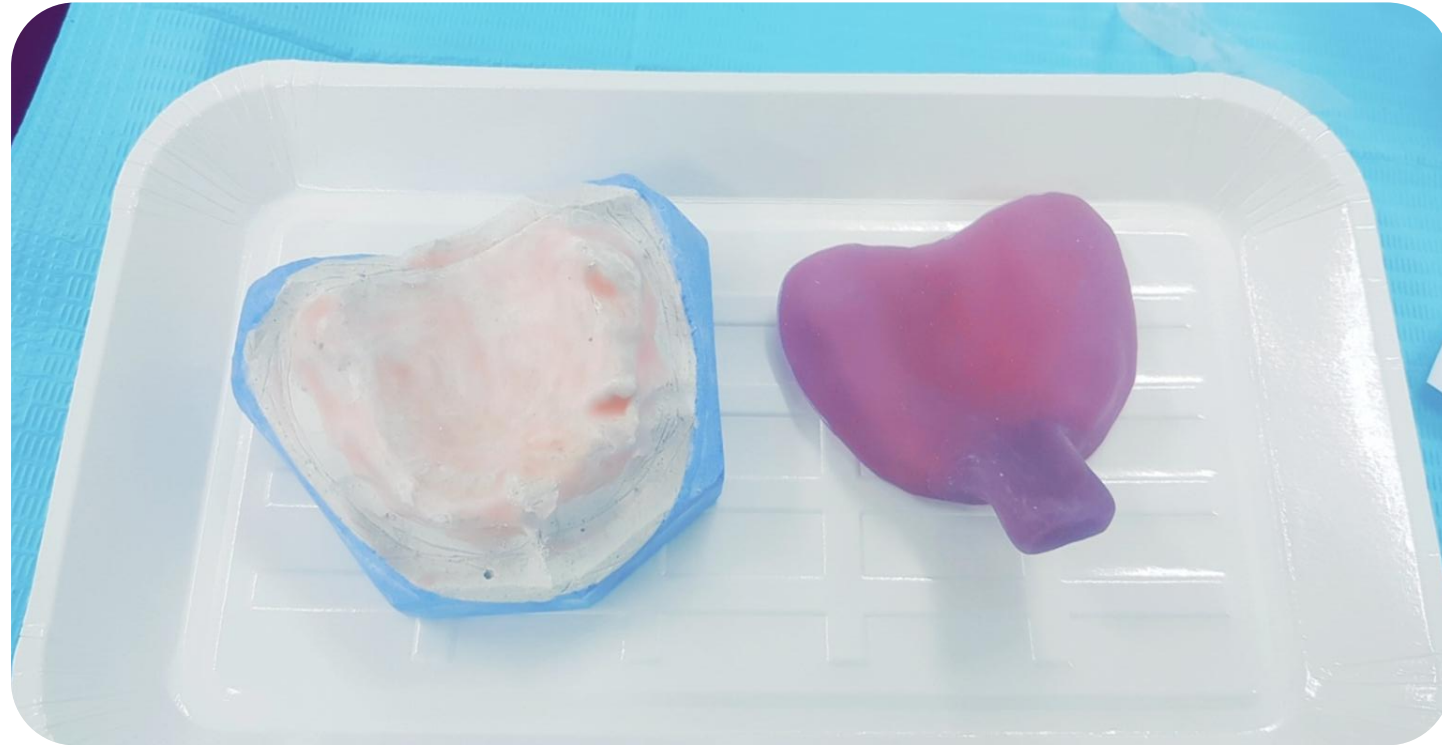Phase III

Replacement missing teeth with
Cobalt chromium RPD



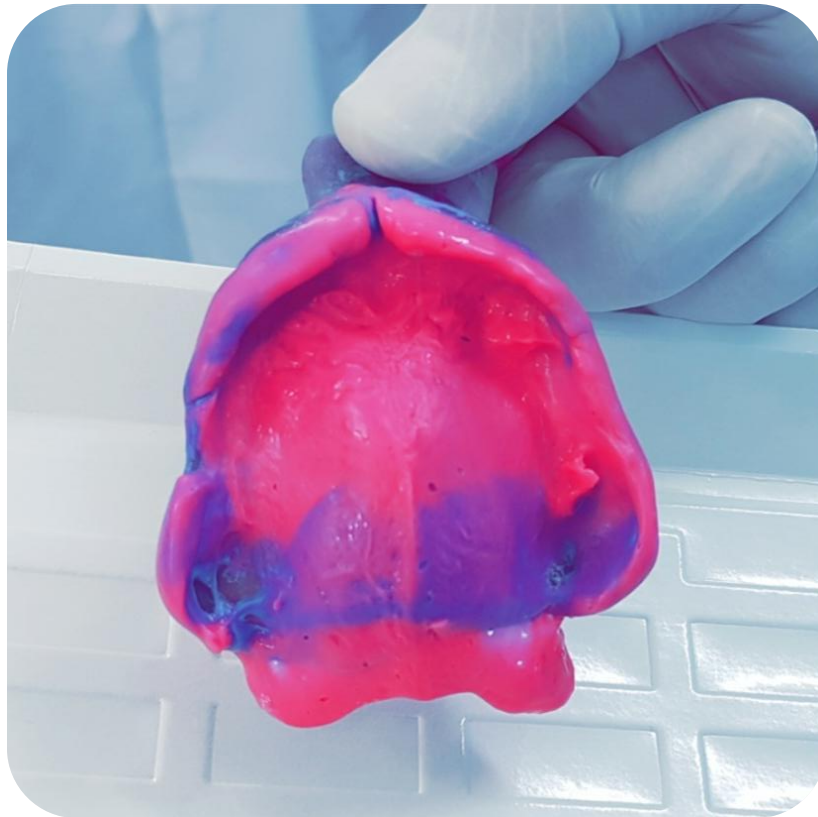Phase III

Replacement missing teeth with
Cobalt chromium RPD

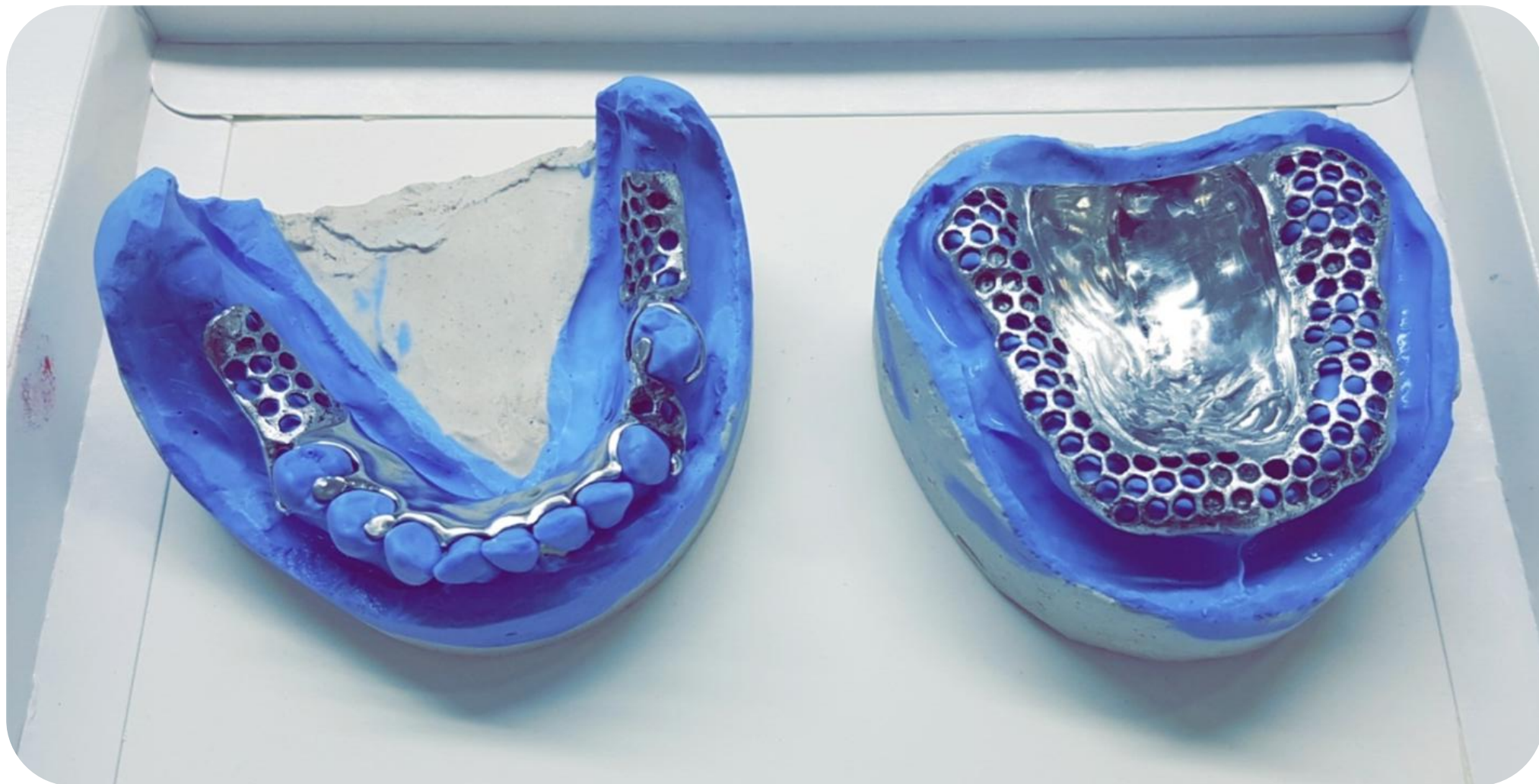

Phase III

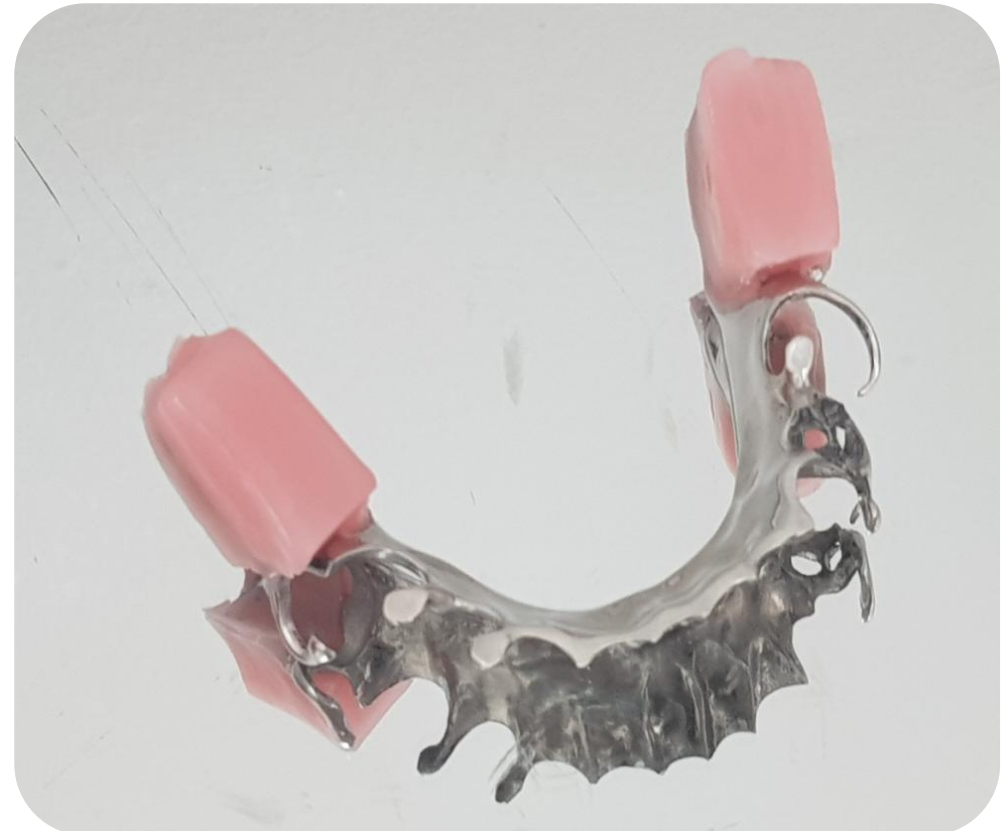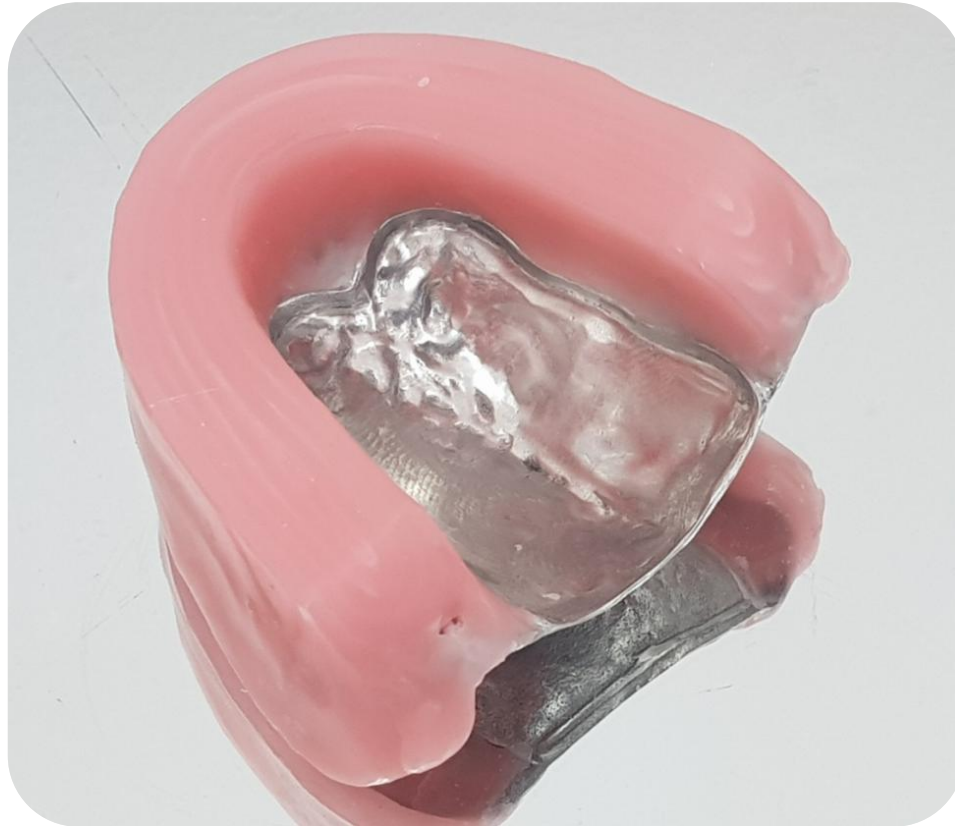Replacement missing upper teeth with
Cobalt chromium C.D



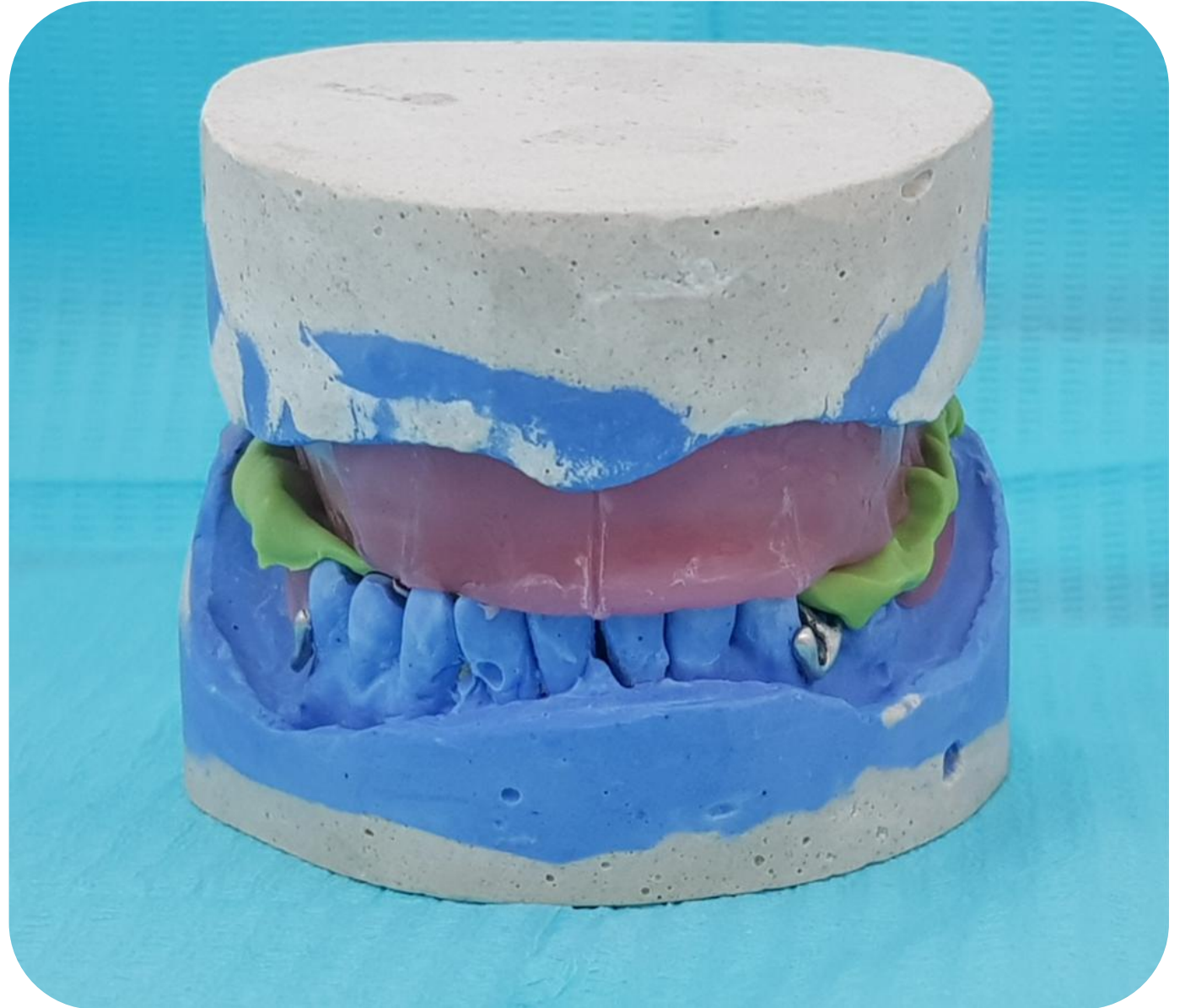Phase III



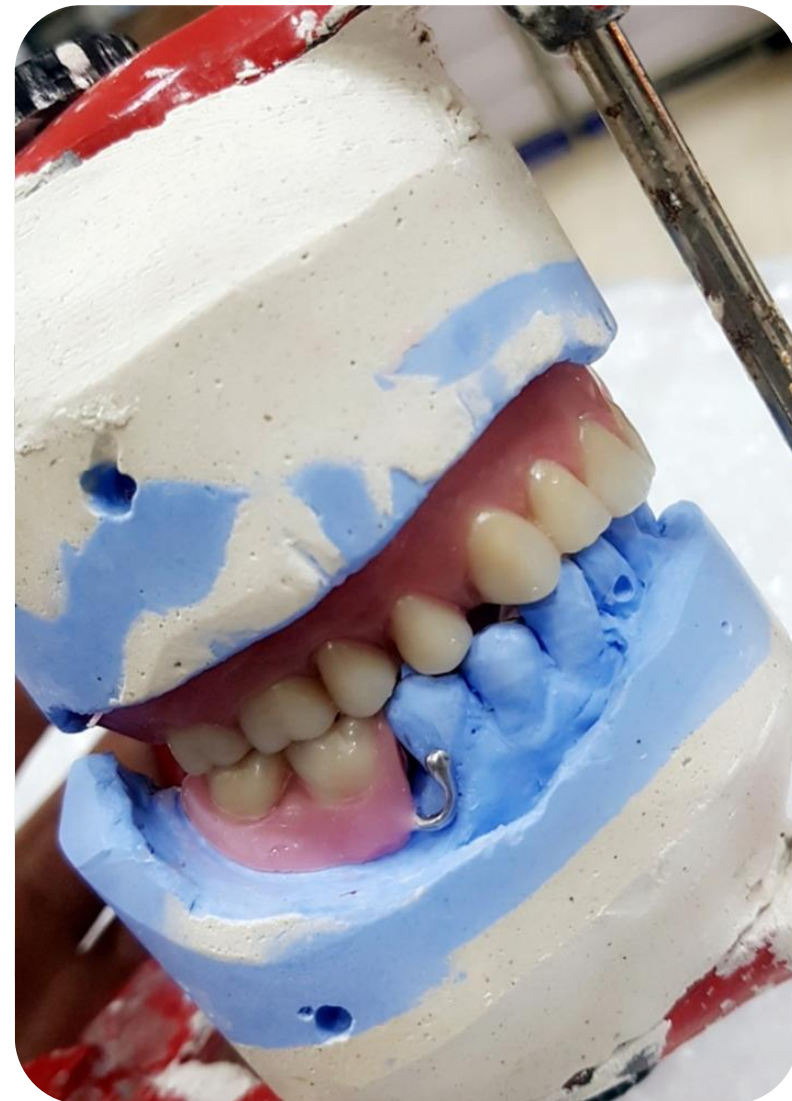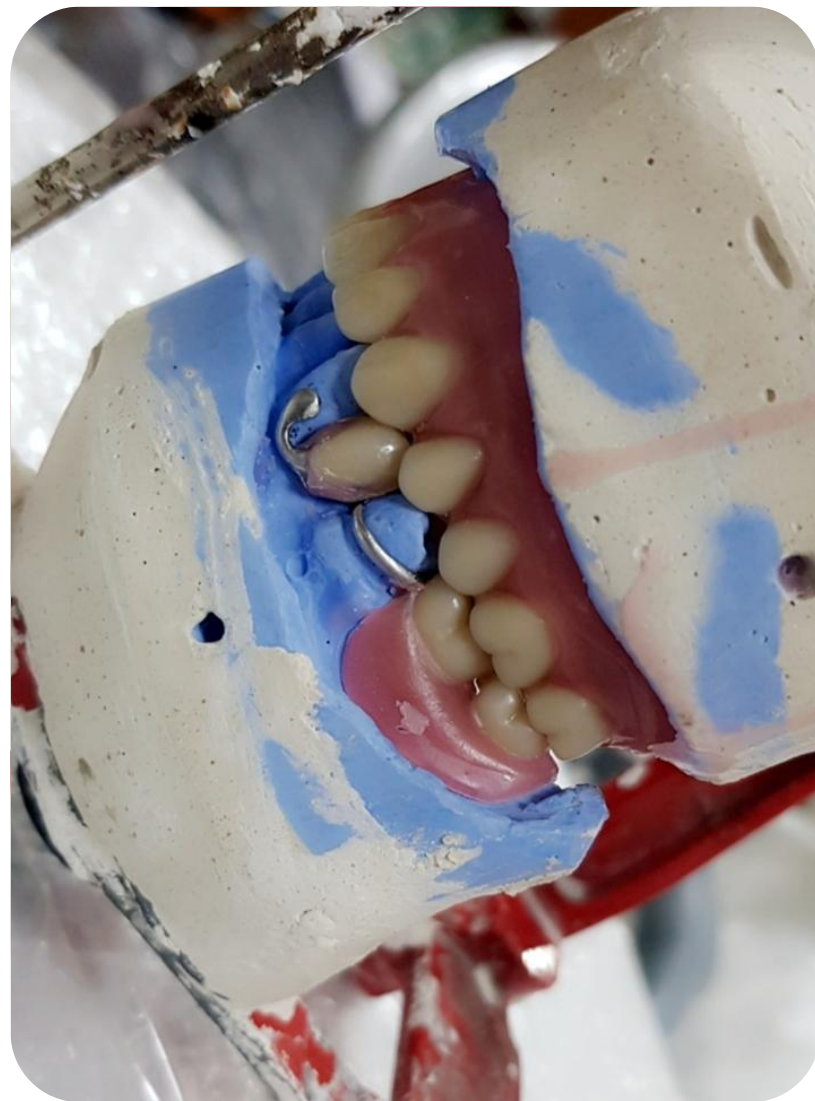
Phase III



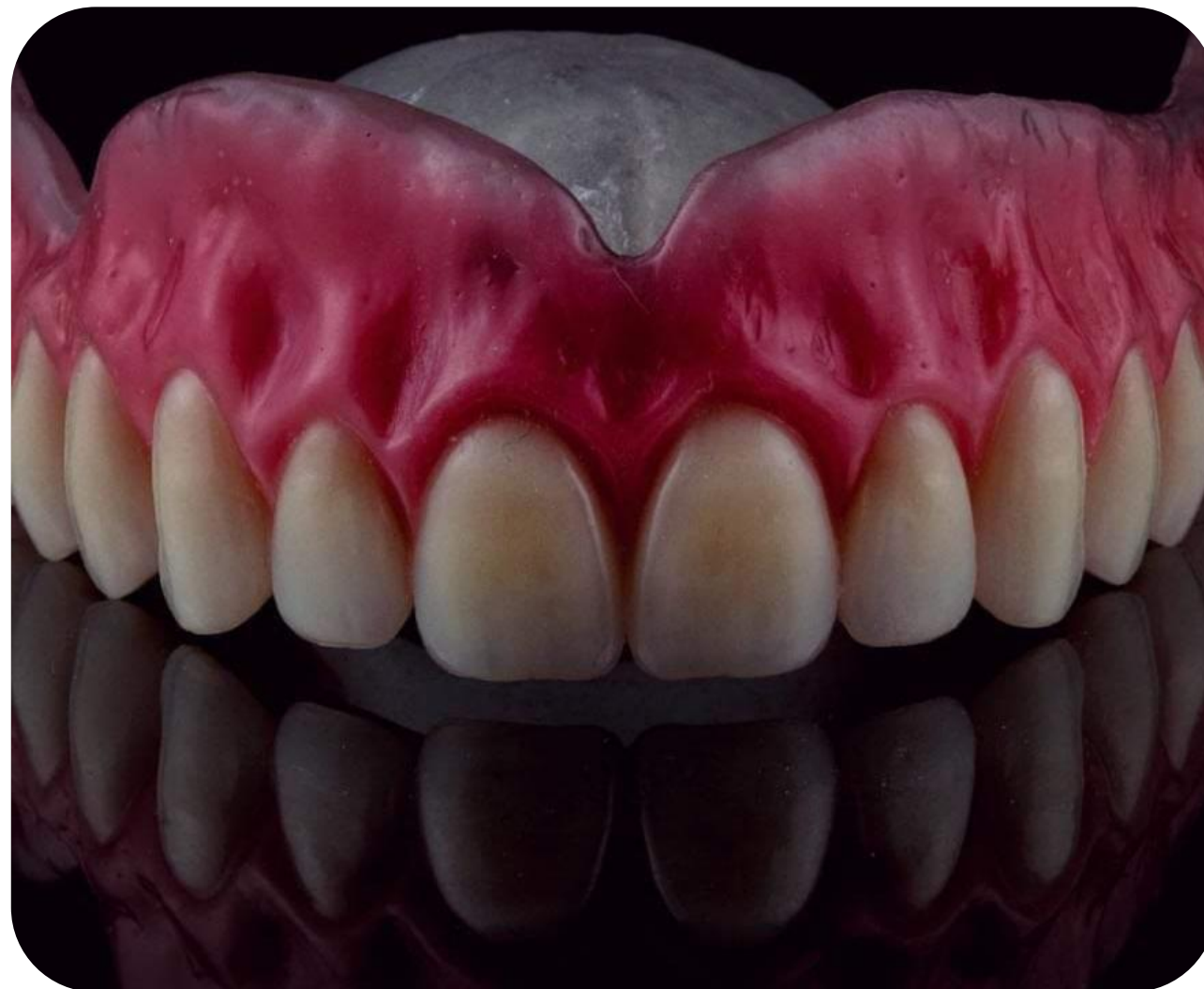Phase III



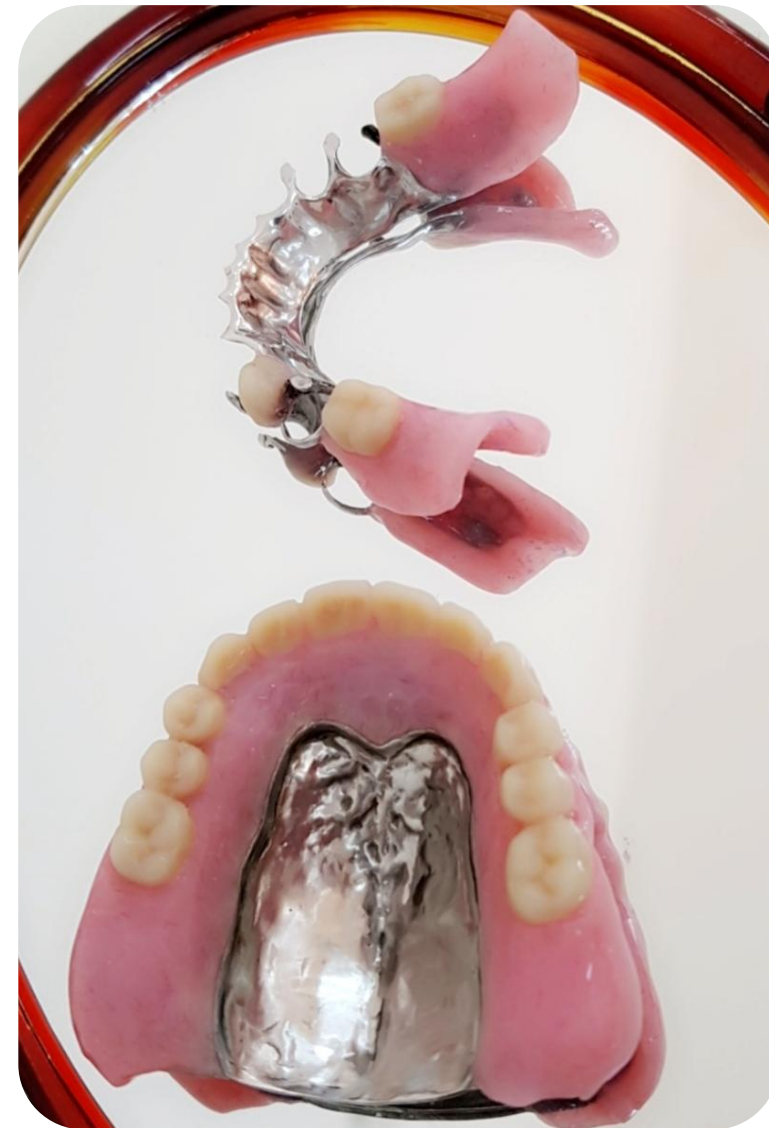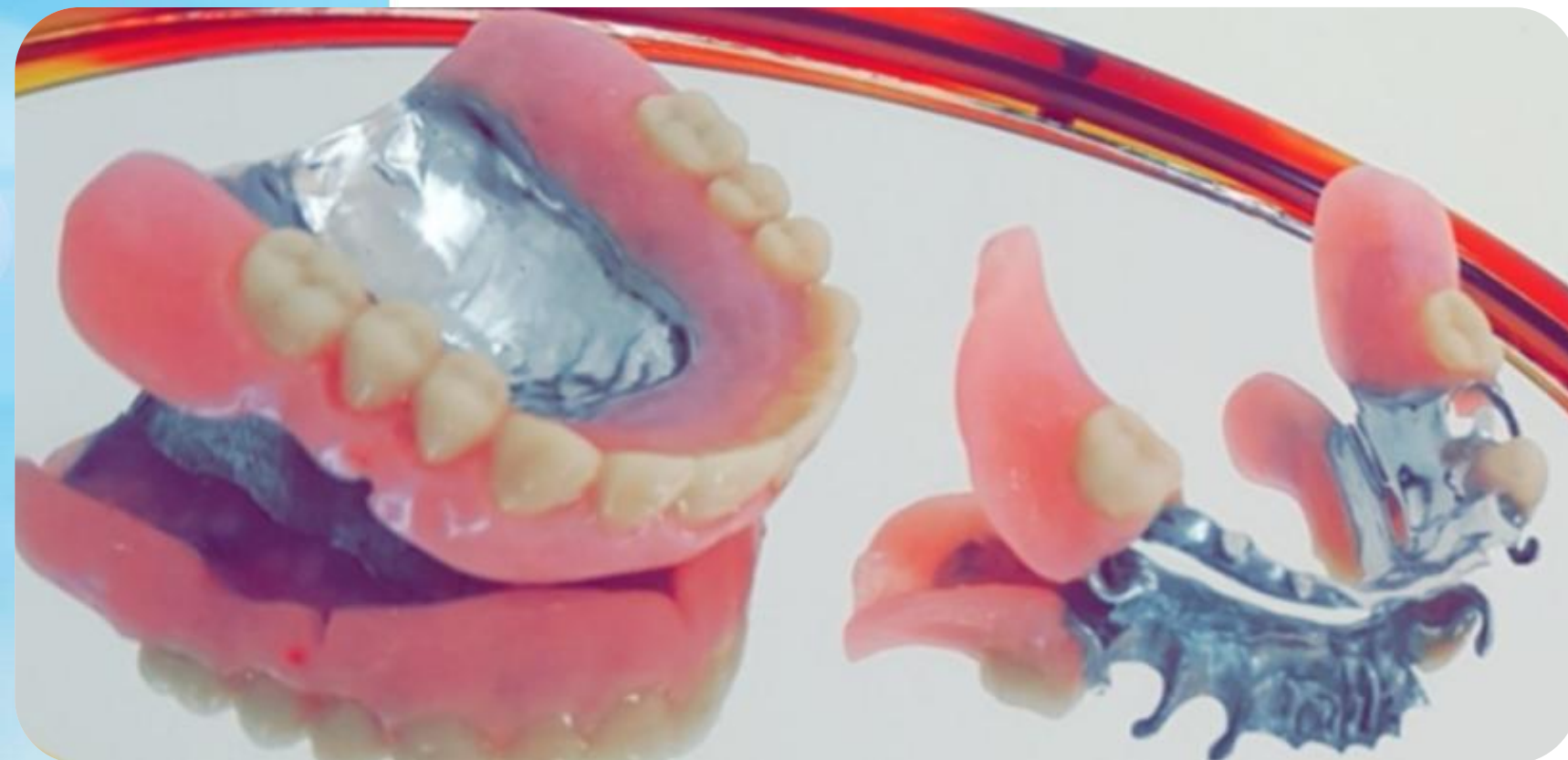Phase III



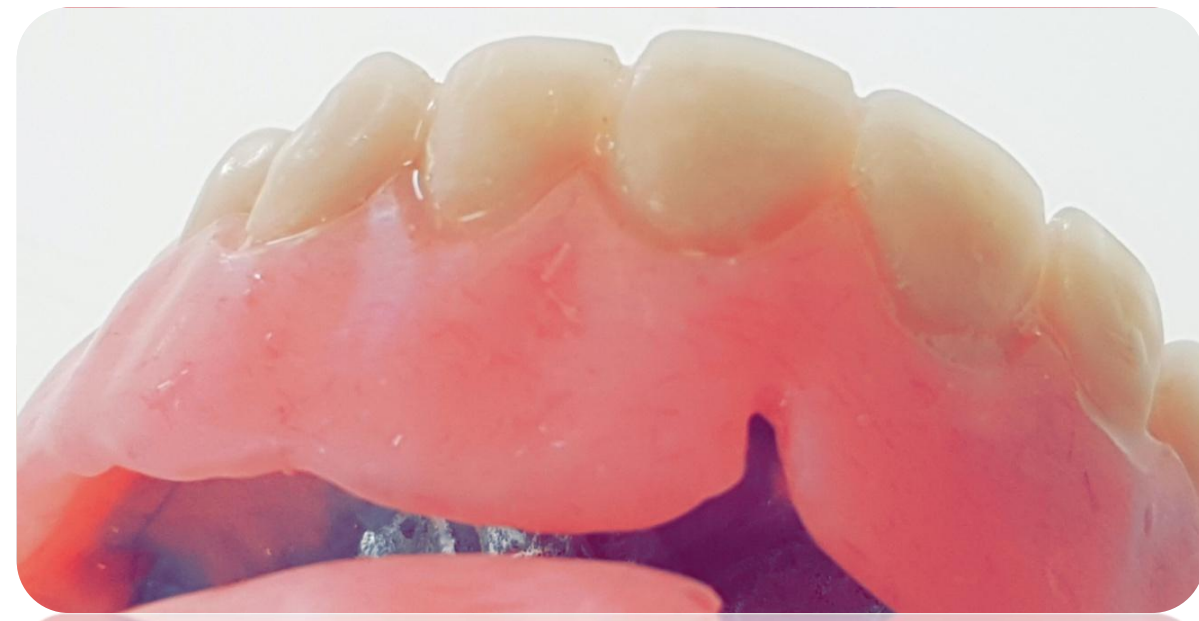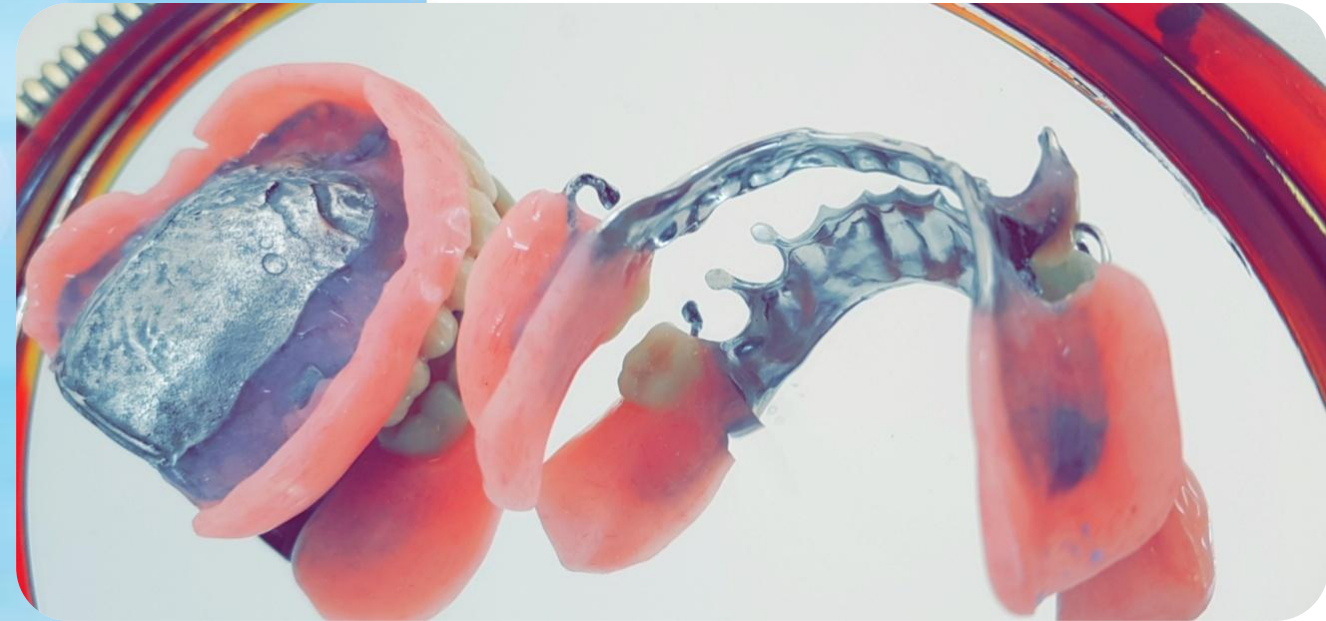Phase III



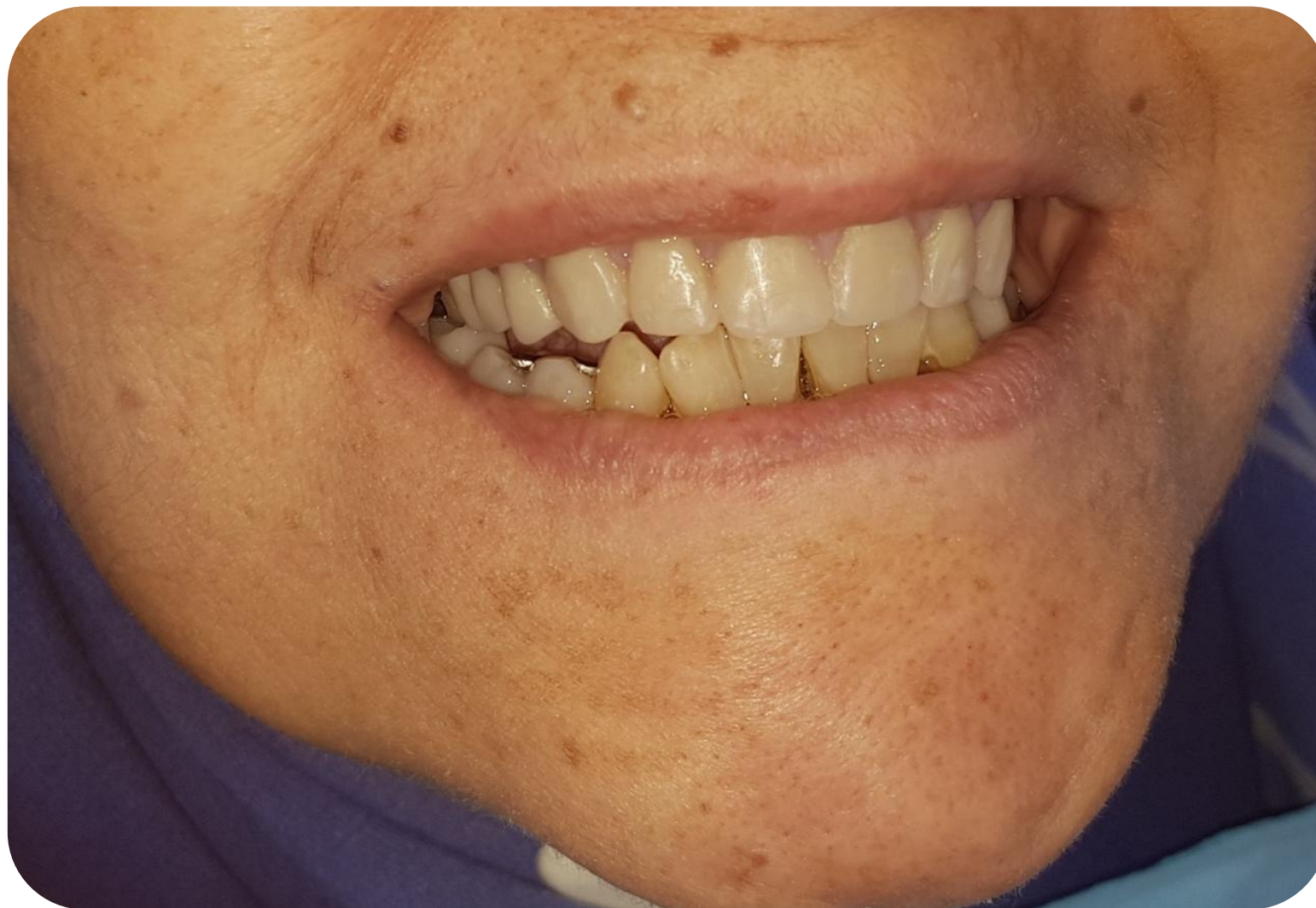Phase III



Phase III



Phase III



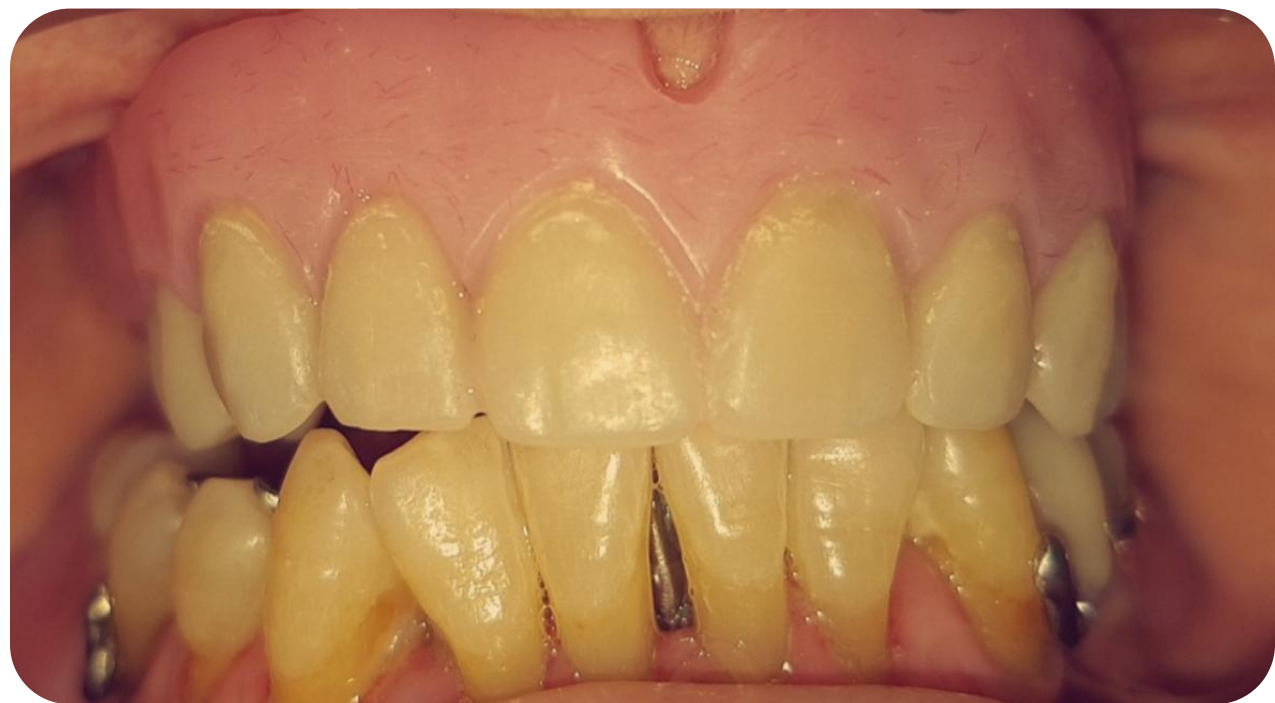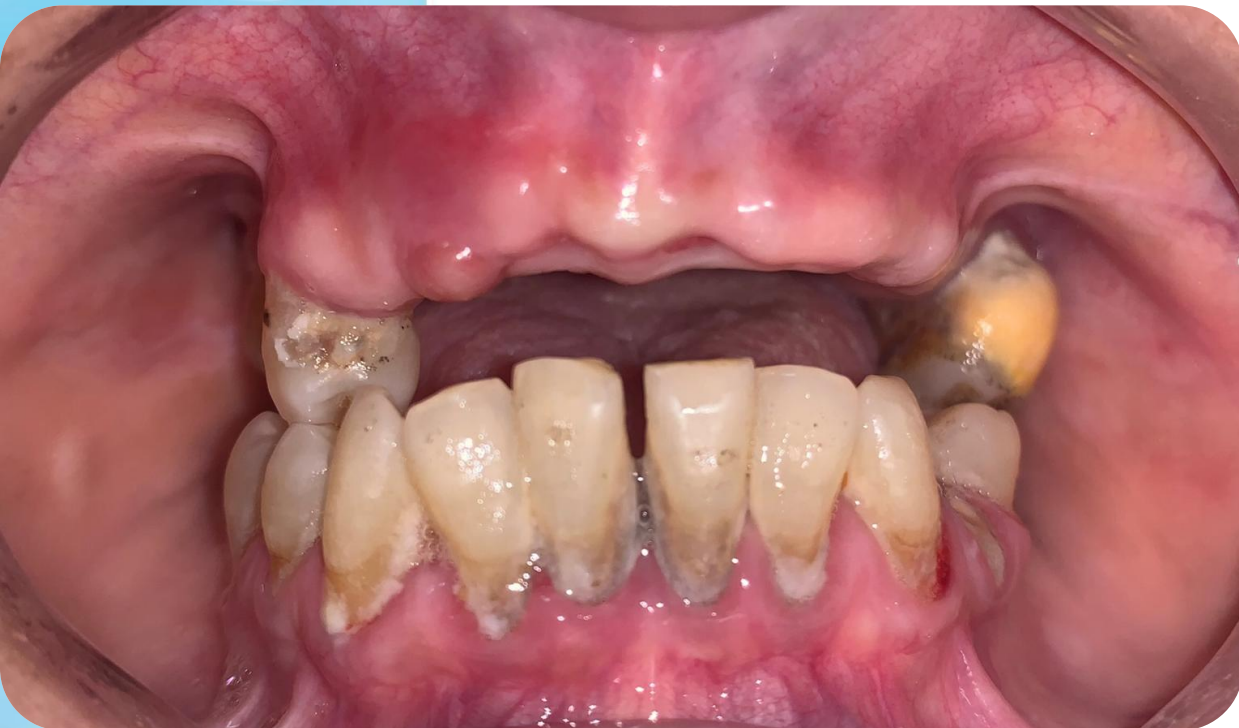Phase IV

Recall after 3 months:

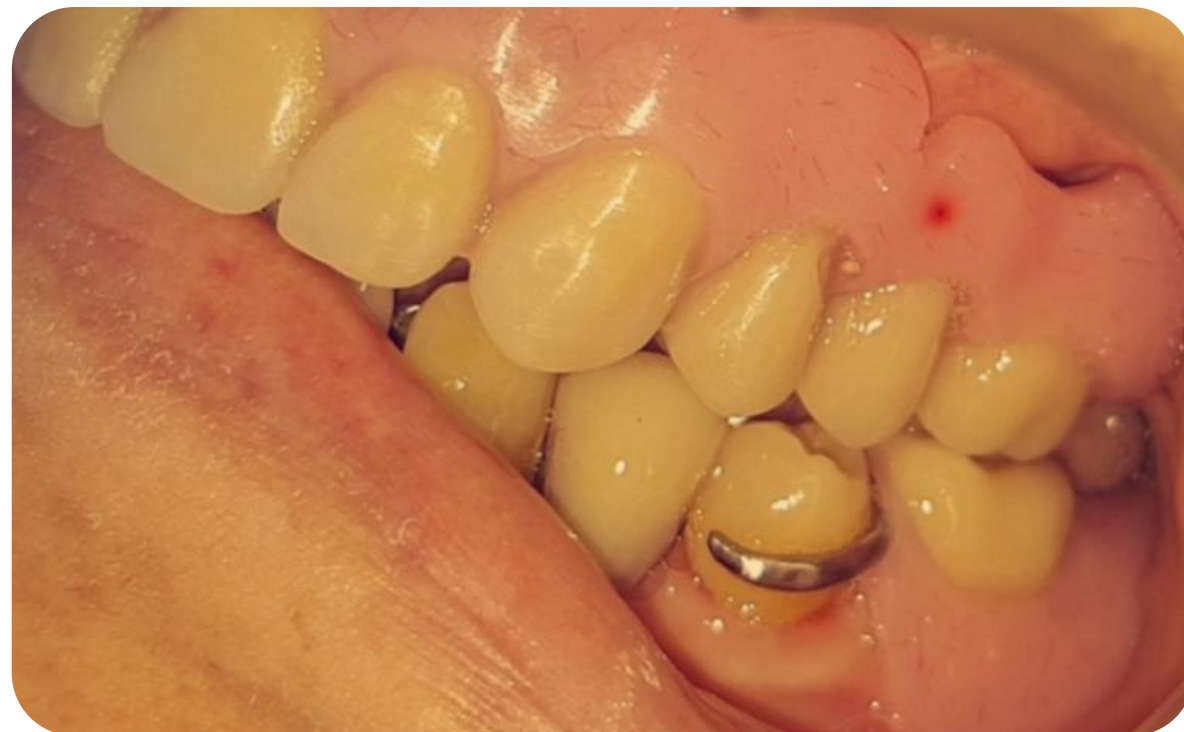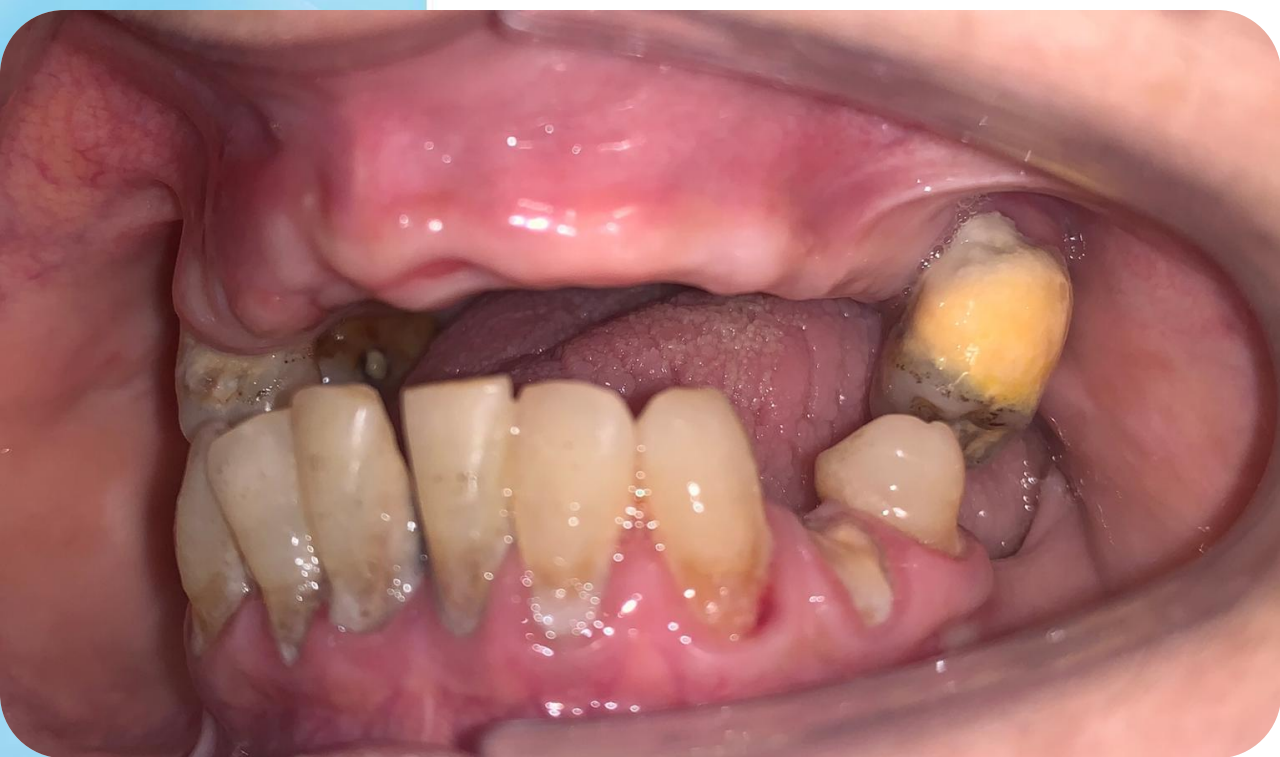- To evaluate oral hygiene & periodontal health.
- To evaluate the restorations & the prosthesis.

Recall for 6 months for regular dental check ups.

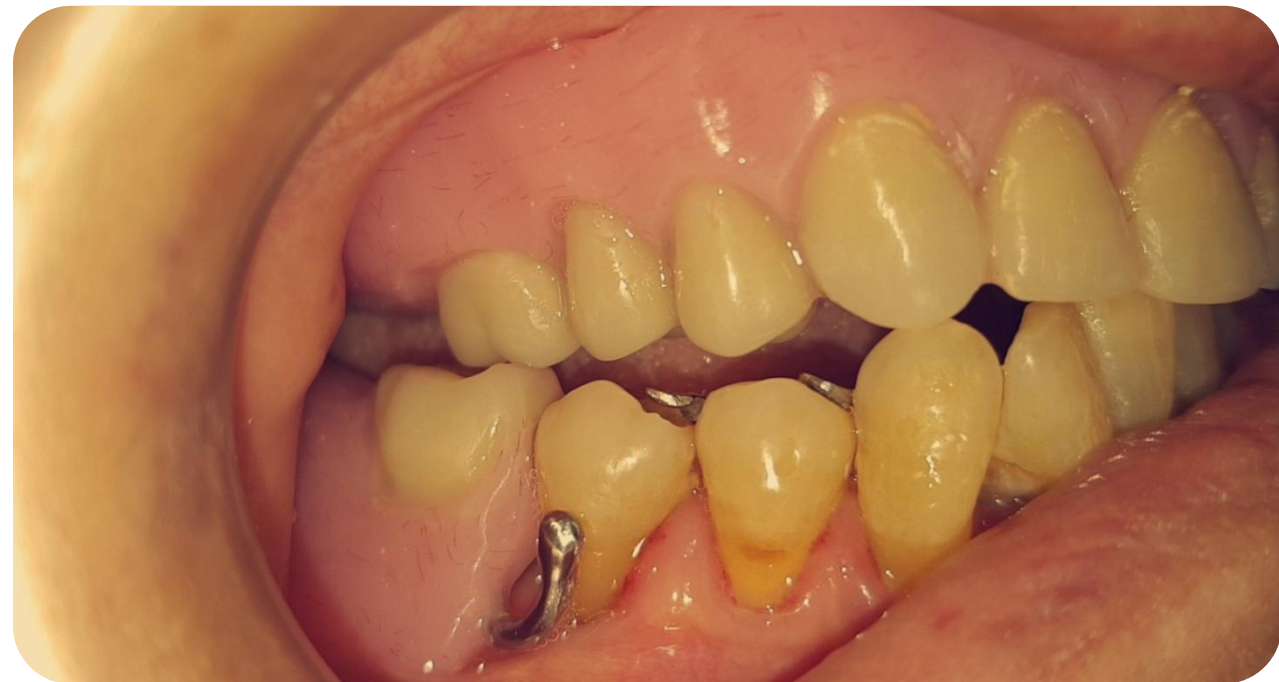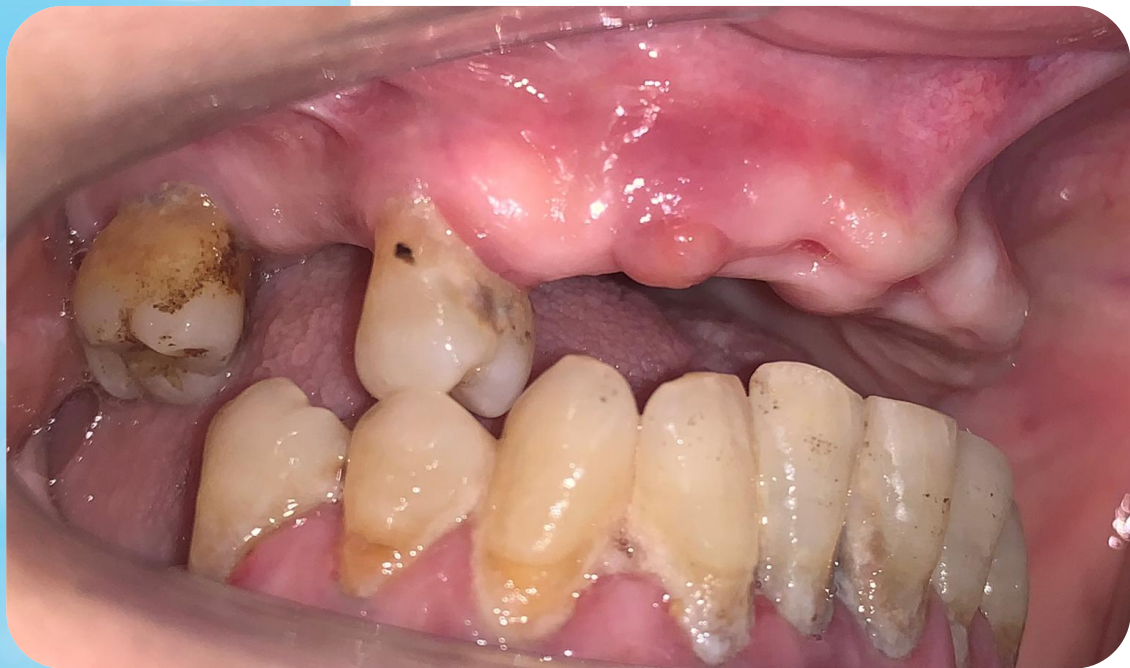Before & After



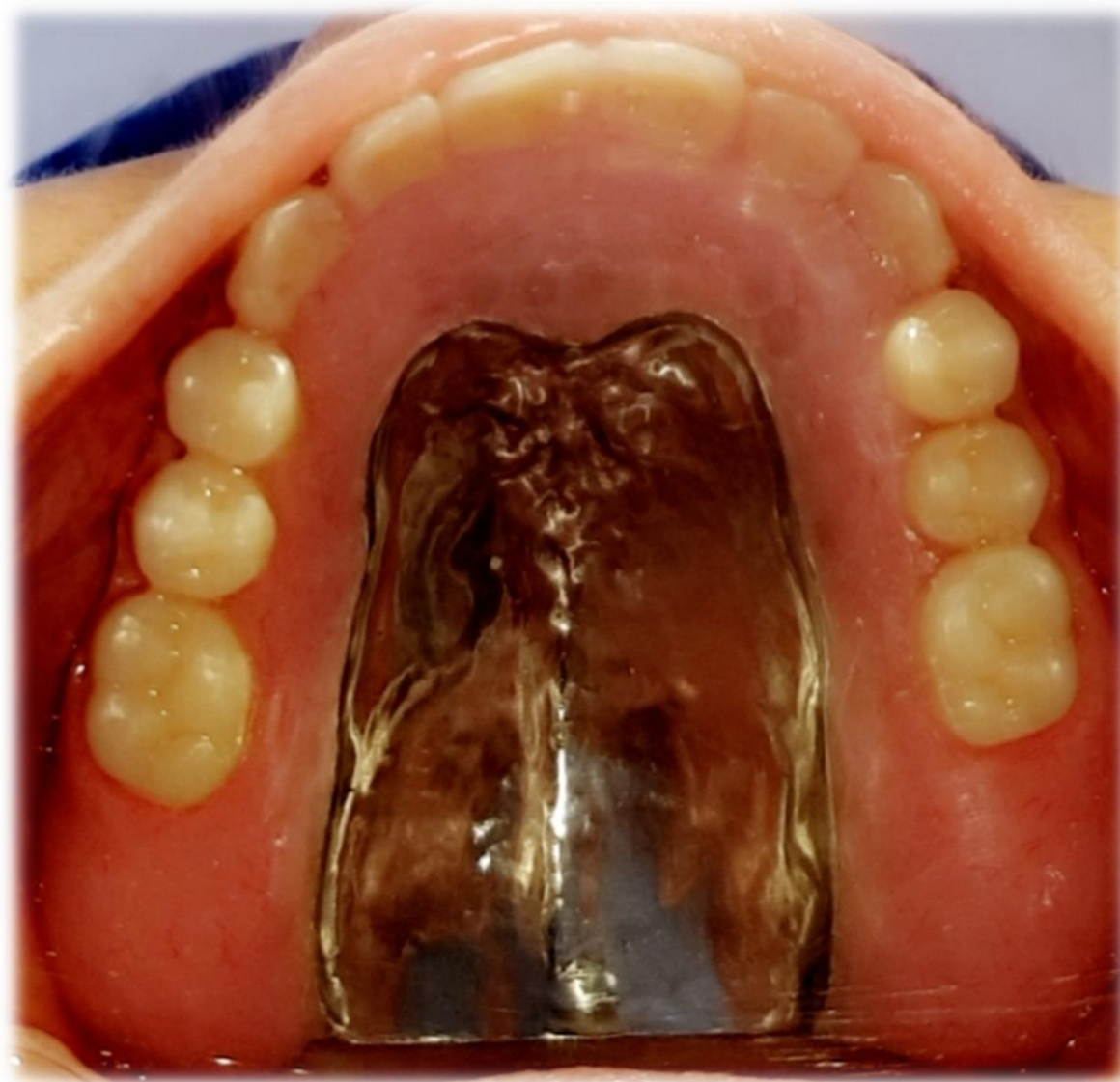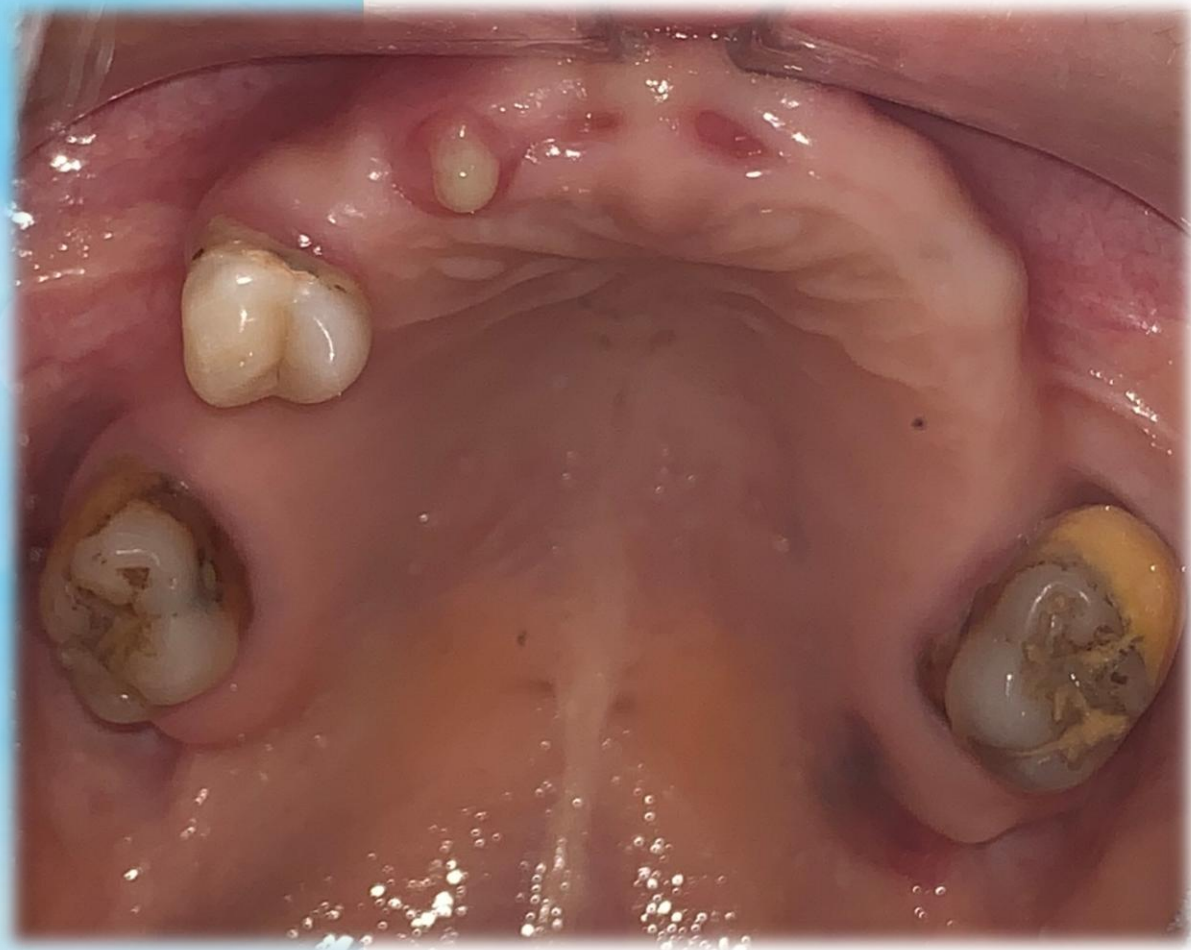Before & After



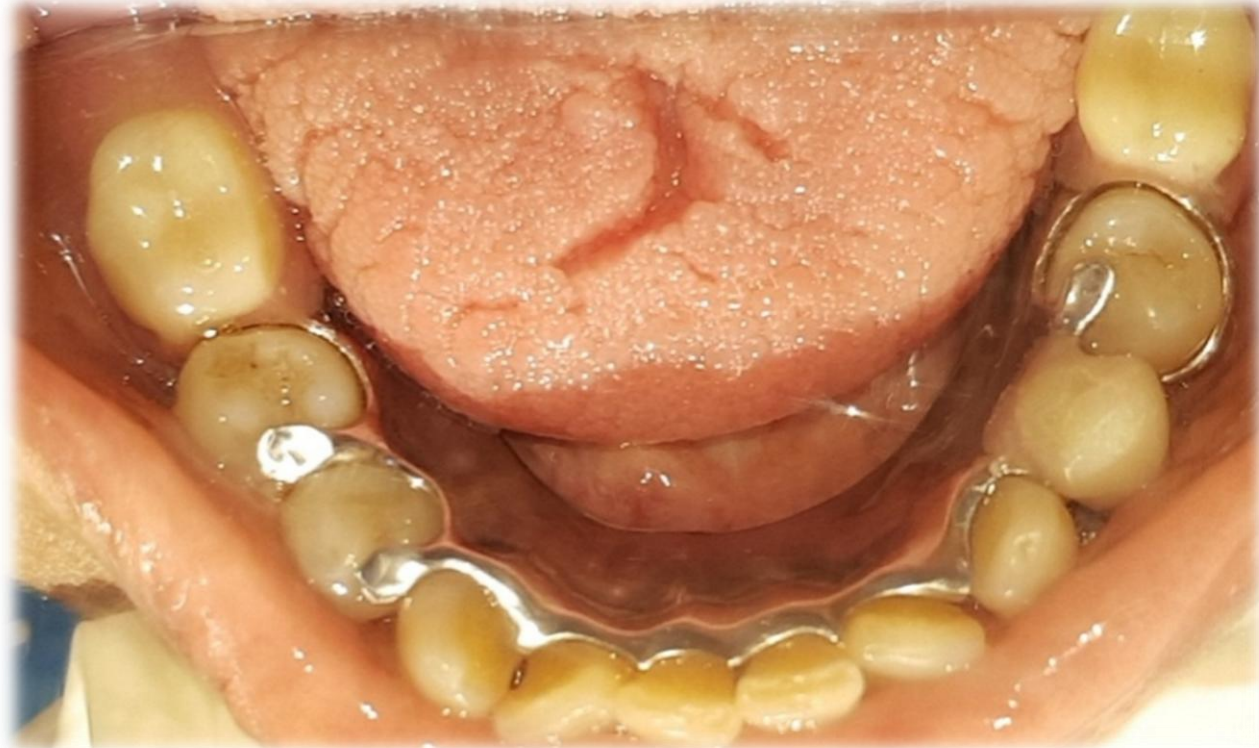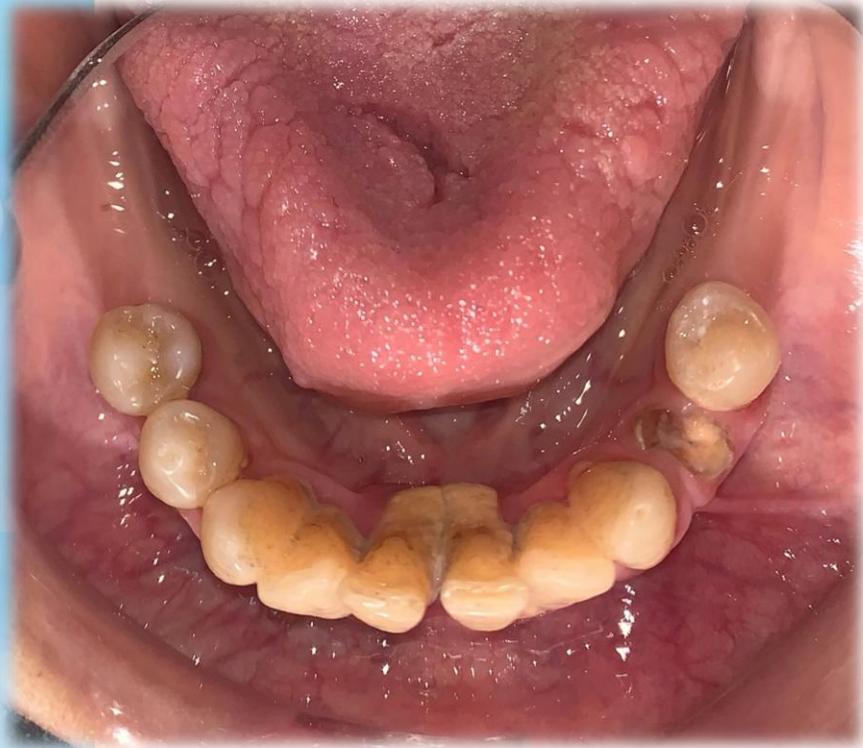
Before & After



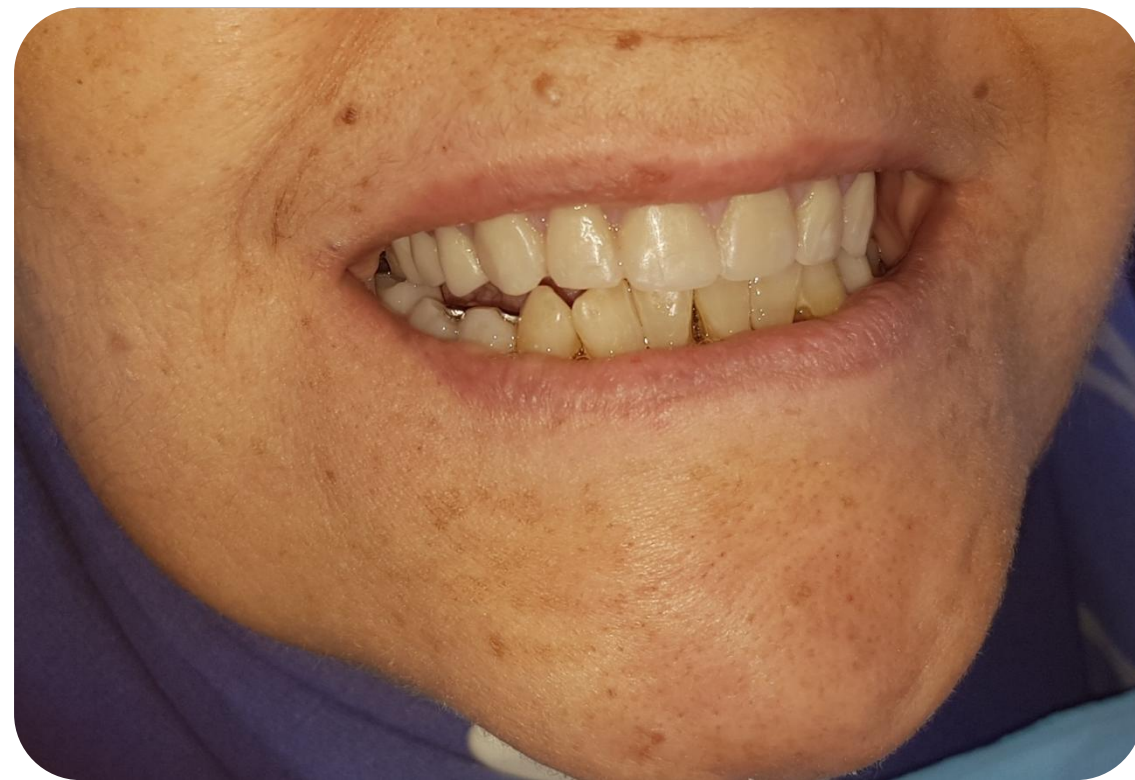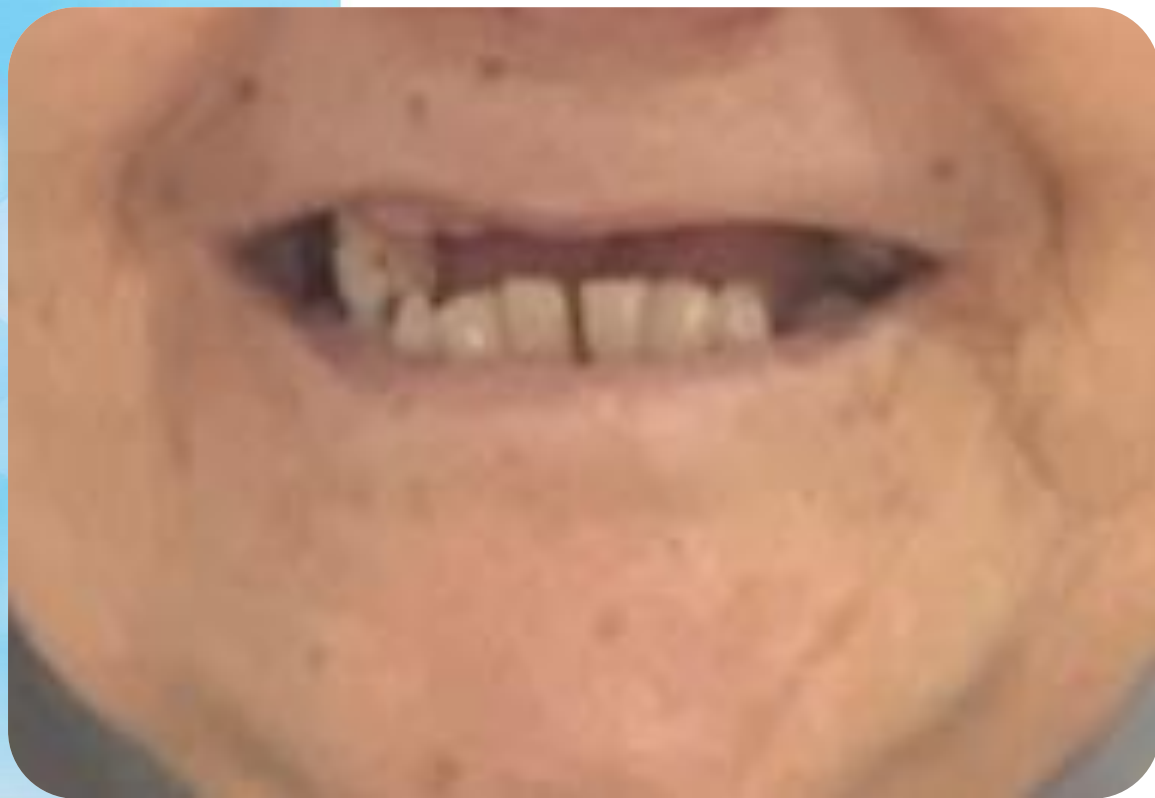
Before & After



Before & After



Before & After



Thank you

