



الجامعة الليبية الدولية للعلوم الطبية
Libyan International Medical University



Comprehensive Case Presentation

Ali Attia Ali _ 1035



The work was achieved under the supervision of dental teaching staff at **LIMU**:

- Prof. Sanosi T Mohammed.
- Dr. Rafik Alkowafi.
- Dr. Abdelmonem Abdelnabi
- Dr. Masoud Alojaly.
- Dr. Ali Bosnayna.
- Dr. Omer Alhuni.
- Dr. Rabea Alhuni.
- Dr. Abdelsalam Alhadad.
- Dr. Nuha Alkadeki.
- Dr. Amal Alawami.
- Dr. Nada Kashbor .
- Dr. Khadiga Alfallah .

Introduction:

Full mouth rehabilitation is defined as the restoration of the form and function of the masticatory apparatus to as nearly a normal condition as possible.

Personal Information:

Name: N.M.S.

Gender: Female.

Nationality: Libyan.

Date of birth: 1975 / 10 / 25

Occupation: House wife.

Address: Hay Al Dollar– Benghazi.

History :

Chief complain:

Patient came to our clinic complaining of bad appearance of her upper and lower front teeth , since more than one year .

History of chief complain:

The patient recognized this problem by herself , She mentioned that since more than one year , she was diagnosed with dental caries and she neglected the problems and did not follow any treatment in some of the affected teeth , with no associated symptoms .

History :

Past & recurrent medical history:

- Medical history : Fit and well
- History of hospitalization: Never.
- Medication : N.O.S .

Past dental history:

- She is symptomatic patient, last visit was 3 months ago.
- Filling , RCT , Extraction , Crown .
- No complications .

History :

Allergy:

No history of allergy.

Social history:

- Married with 1son & 1daughter
- Not smoker & not alcohol drinker.
- Mixed and varied diet .

Family history:

Hypertensive Mother .

History :

Oral hygiene practice:

- **Brushing:** Irregular tooth brushing , with horizontal motion by hard tooth brush .
- **Brushing method:** Horizontal & vertical.
- **Kind of dentifrice used:** Nothing specific.

Clinical Examination:

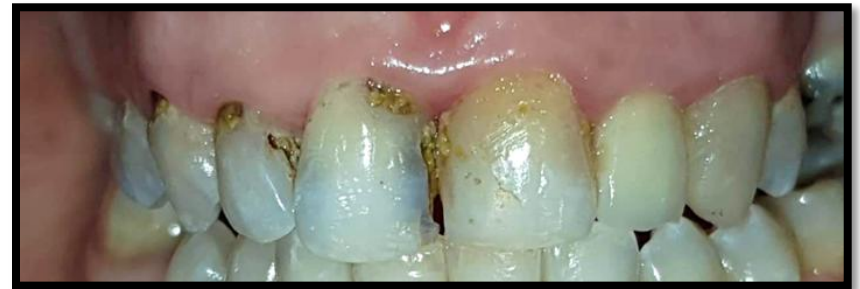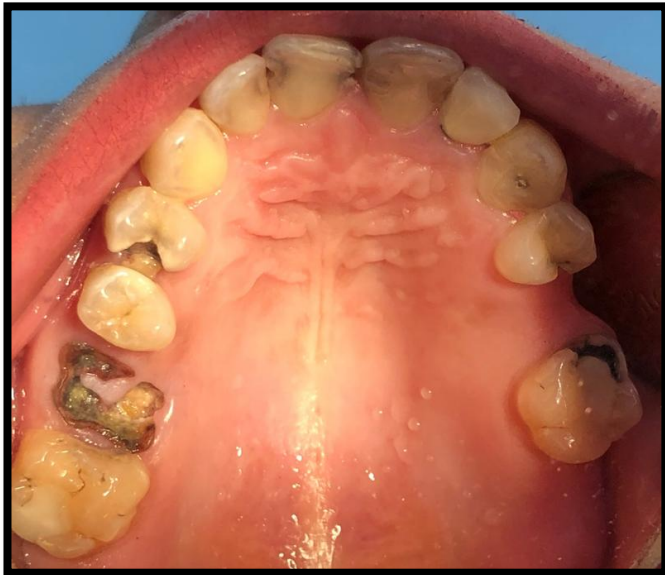Extra oral examination:

- **Facial symmetry:** Symmetrical.
- **Lips:** competent.
- **Face form:** Ovoid.
- **Profile:** Straight.
- **Skin:** No swelling , sinus , or scar .
- **TMJ:** No clicking, not tender, no deviation, no dislocation.
- **Lymph node:** Not palpable, not tender.

Intraoral Examination

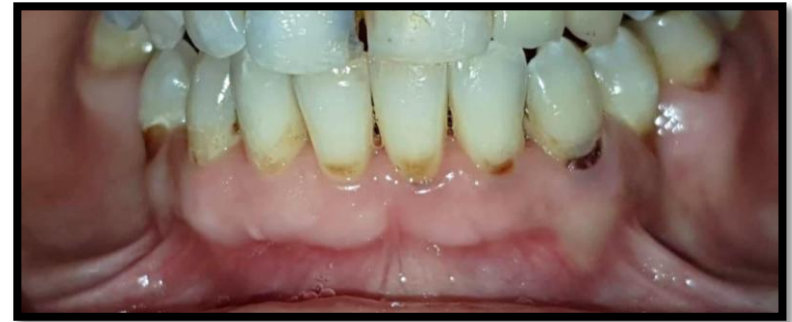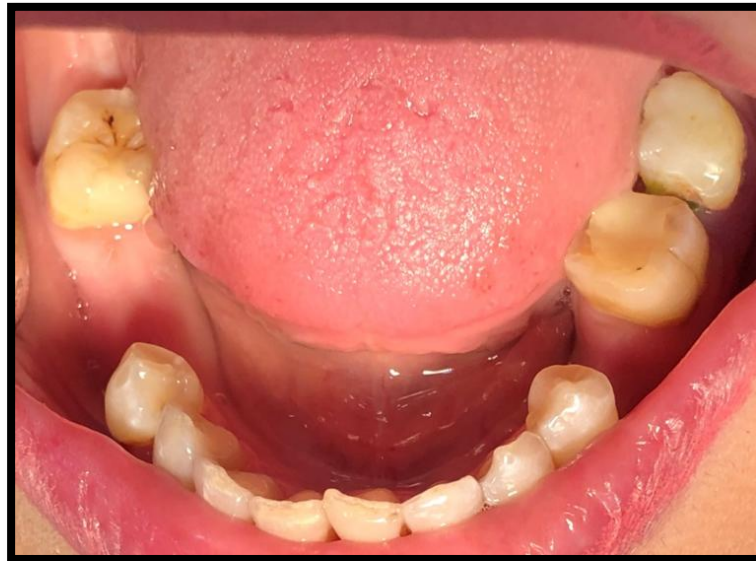Maxillary arch

| | | | | | | | | | | | | | | | |
|---|---|----|---|---|---|---|---|---|----|---|---|---|---|---|---|
| 8 | 7 | 6 | 5 | 4 | 3 | 2 | 1 | 1 | 2 | 3 | 4 | 5 | 6 | 7 | 8 |
| M | D | RR | D | D | D | D | D | F | CR | F | D | M | D | M | M |



Mandibular arch

| | | | | | | | | | | | | | | | |
|---|---|---|---|---|---|---|---|---|---|---|---|---|---|---|---|
| 8 | 7 | 6 | 5 | 4 | 3 | 2 | 1 | 1 | 2 | 3 | 4 | 5 | 6 | 7 | 8 |
| M | D | M | M | D | D | D | D | D | D | D | D | M | D | D | M |



Gingival Status:

| | Max. Right Posterior | Max. Anterior | Max. Left Posterior |
|---------------------|----------------------------|----------------------------|----------------------------|
| Color | Pink | Pink | Pink |
| Contour | Round edge with blunt IDP. | Round edge with blunt IDP. | Round edge with blunt IDP. |
| Size | Normal | Normal | Normal |
| Consistency | Firm and resilient | Firm and resilient | Firm and resilient |
| Stippling | Absent | Absent | Absent |
| Position | Cornal to CEJ | Cornal to CEJ | Cornal to CEJ |
| Bleeding on probing | Present | Present | Present |
| Exudation | Absent | Absent | Absent |

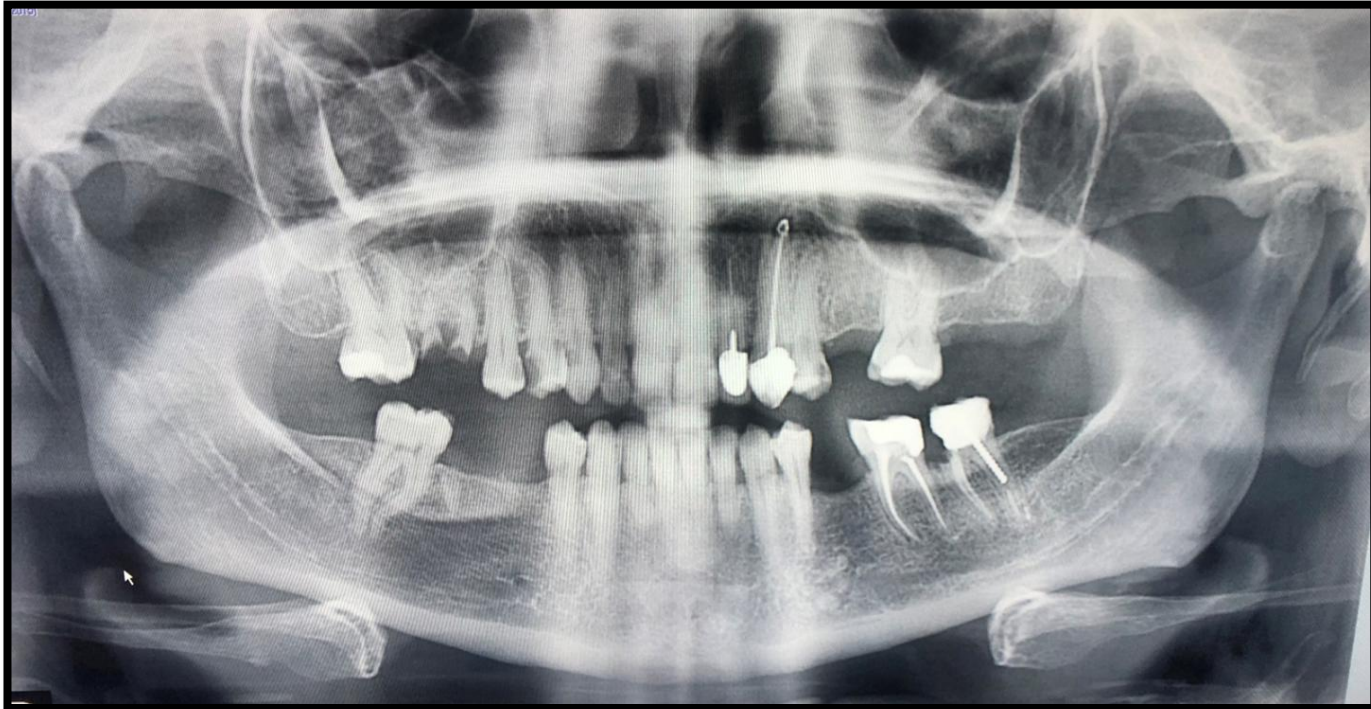
Gingival Status:

| | Man. Right Posterior | Man. Anterior | Man. Left Posterior |
|---------------------|----------------------------|----------------------------|----------------------------|
| Color | Pink | Pink | Pink |
| Contour | Round edge with blunt IDP. | Round edge with blunt IDP. | Round edge with blunt IDP. |
| Size | Normal | Normal | Normal |
| Consistency | Firm and resilient | Firm and resilient | Firm and resilient |
| Stippling | Absent | Absent | Absent |
| Position | Apical to CEJ | At CEJ | Apical to CEJ |
| Bleeding on probing | Present | Present | Present |
| Exudation | Absent | Absent | Absent |

Periodontal Status :

- Generalized **CAL** “ 1-2 mm “ .
- Adequate attached gingiva .
- No furcation involvement .
- No mobility .
- No traumatic occlusion .

Orthopantomogram (OPG)



Final Diagnosis :

- **Regarding to chief complain:** multiple caries lesions .

$$\begin{array}{r|l} 7 & 5 & 4 & 3 & 2 & 1 & 4 & 6 \\ \hline 7 & 4 & 3 & 2 & 1 & 1 & 2 & 3 & 4 & 6 & 7 \end{array}$$

- Generalized mild chronic periodontitis.

- Failed restorations. $\underline{1 \ 2 \ 3}$

- Remaining roots. $\frac{6}{6}$

- Edentulous area:

- **Upper Arch :** Class III Mod1
- **Lower Arch :** Class III Mod 1

Treatment plan :

Emergency phase: No need.

Phase I:

- OHI + scaling .
- Diet control
- Fluoride application.
- Caries control :

| | | |
|-------------|--|-----------|
| 7 5 4 3 2 1 | | 1 4 6 |
| <hr/> | | |
| 7 4 3 2 1 | | 1 2 3 4 6 |

Re-evaluation of phase I.

Phase II:

Extraction .

| | | |
|-------|--|---|
| 6 | | |
| <hr/> | | |
| | | 7 |

 Surgical extraction

| | | |
|-------|--|---|
| | | |
| <hr/> | | |
| | | 6 |

Treatment plan :

Phase III:

RCT : 5 4 2 1 | 4

Re-treatment: . 2

Permenant restoration: 7 3 | 1 6
6 4 3 2 1 | 1 2 3 4

Post ,core and crown 5 4 2 1 | 2 3
6

Replecment teeth :

Bridge : 6 | 5

RPD : class III modifiction3 6 5 | 5

Treatment plan :

Phase IV:

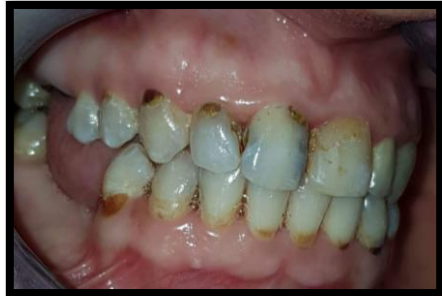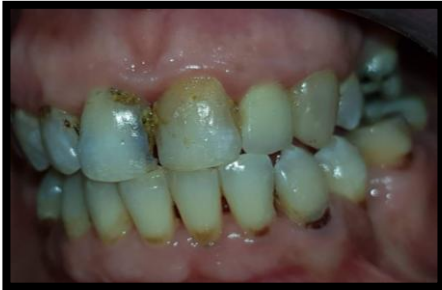Maintenance & recall.



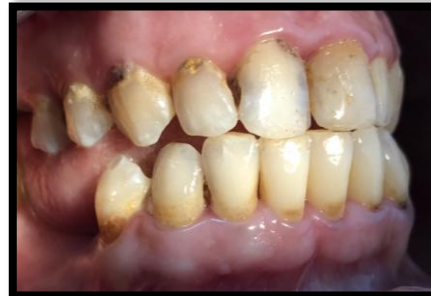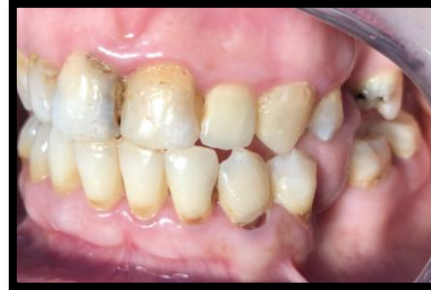Phase I :

scaling

Pre – operative



Post -operative



Phase I :

Diet Counseling

| نوع الوجبة | الأكولات والمشروبات | الساعة | اليوم |
|------------|--|---------------|--------|
| فطور | سجوليا ^x | 7:00 | الخميس |
| فطور | قهوة ^x + كيلة ^x | 9:00 | |
| غداء | هشخو ^x | 11:30 | |
| غداء | طاجونة | 1:30 | |
| عشاء | زيتونة ^x + صلح ^x + فزوة ^x + ماس ^x سلو لاطة ^x | 8:00 12:00 | |
| فطور | سجوليا [✓] | 9:30 | الجمعة |
| غداء | سجوليا [✓] + سلو لاطة [✓] + ماس [✓] | 1:00 | |
| عصير | قهوة ^x + سبويات ^x + ماس ^x سلو لاطة ^x | 5:00 10:00 | |
| فطور | قهوة ^x + كيلة ^x | 9:00 | السبت |
| غداء | مكرونة [✓] أمبروزة [✓] سلو لاطة [✓] ميه [✓] | 1:30 | |
| عصير | قهوة ^x + كيلة ^x + سلو لاطة ^x | 4:30 | |
| عشاء | فاصوليا ^x + ميه ^x | 8:30 | |

Phase I :

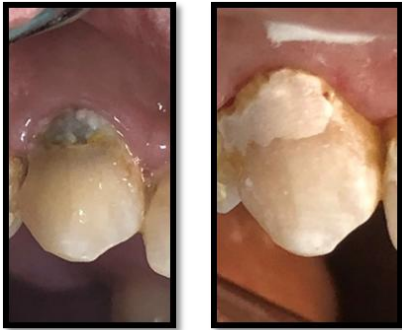
Fluoride application



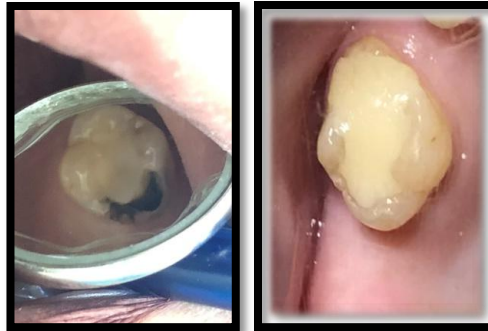
Phase I :

Caries control

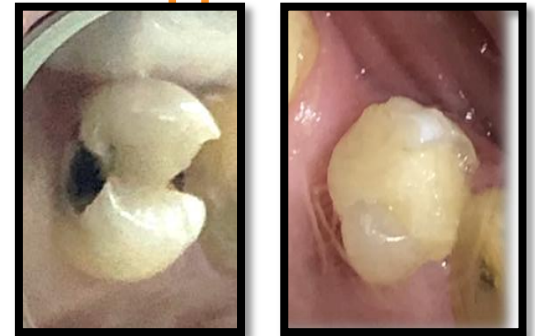
Upper right 3



Upper left 6



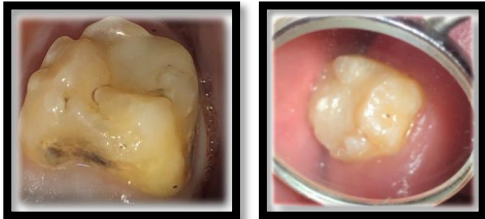
Upper left 4



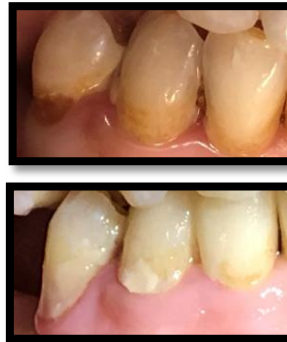Phase I :

Caries control

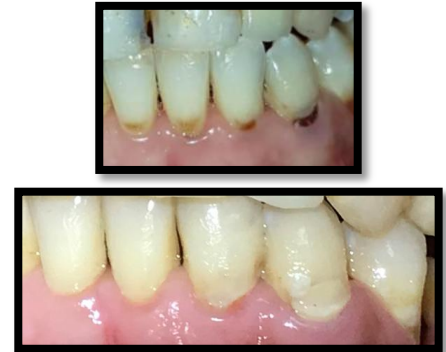Upper right 7



Lower right 2,3,4



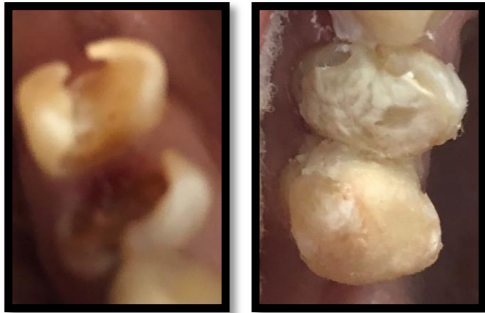
Lower right 1 , left 1,2,3, 4



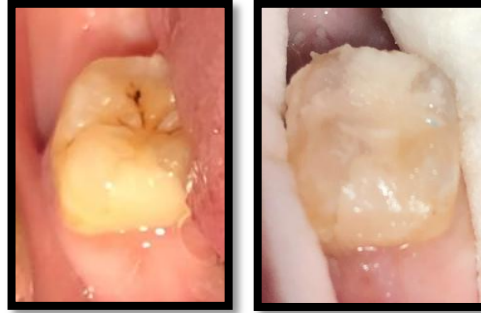Phase I :

Caries control

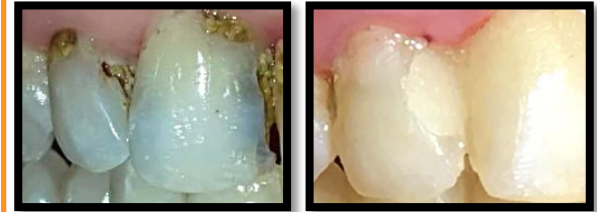
Upper right 4,5



Lower right 7



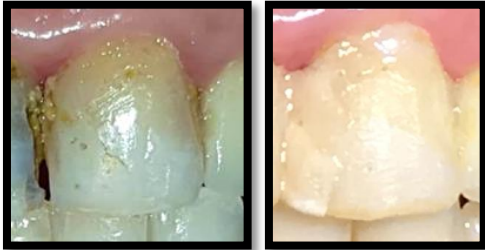
Upper right 1, 2



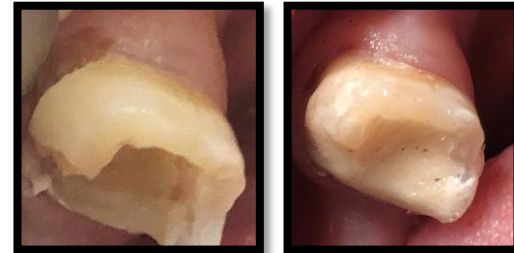Phase I :

Caries control

Upper left 1



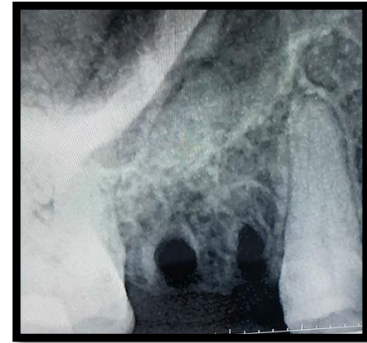
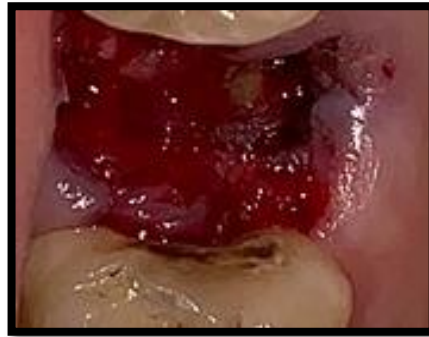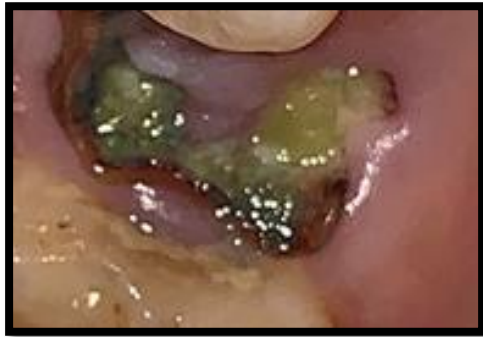Lower left 6



Phase II :

Surgical phase

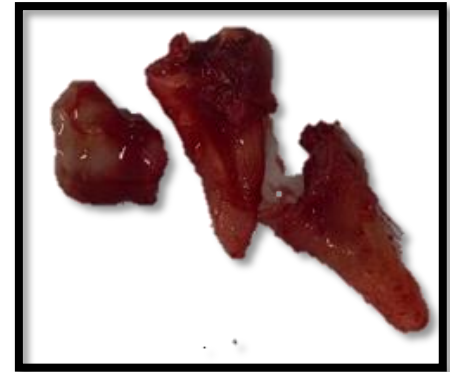
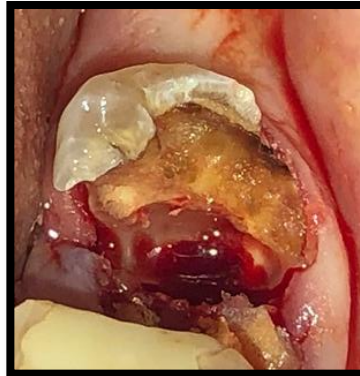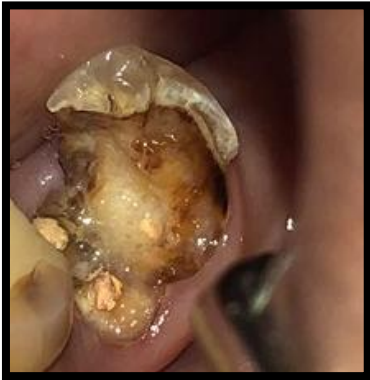Upper right 6



Phase II :

Surgical phase

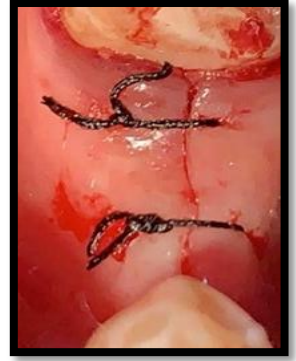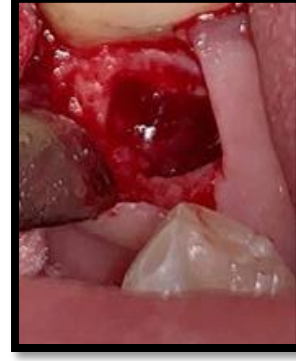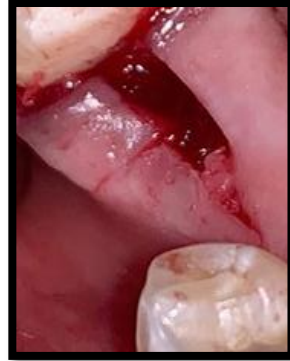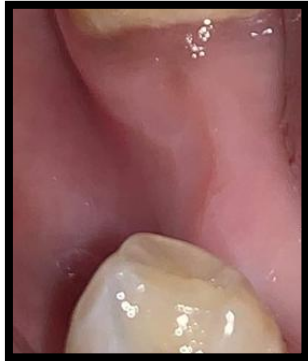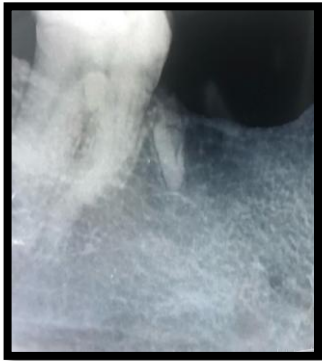Lower left 7



Phase II :

Surgical phase

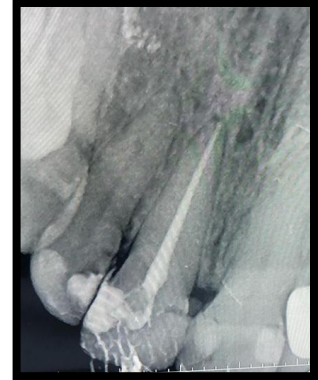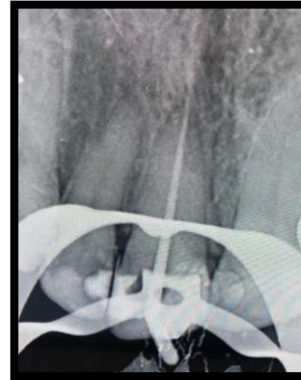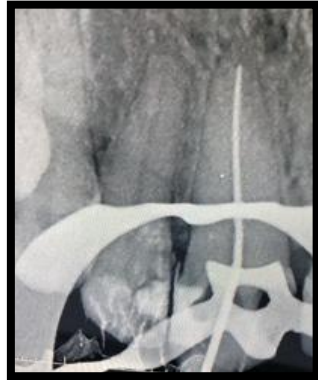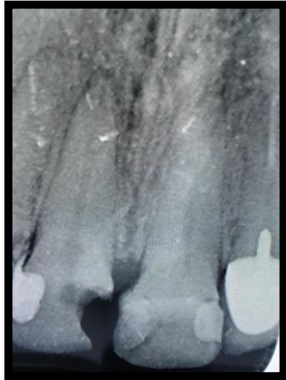Lower right 6



Phase III :

RCT

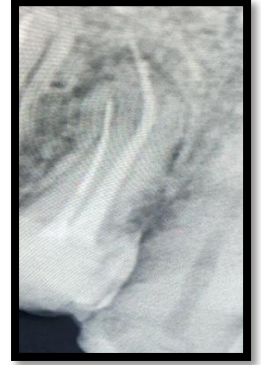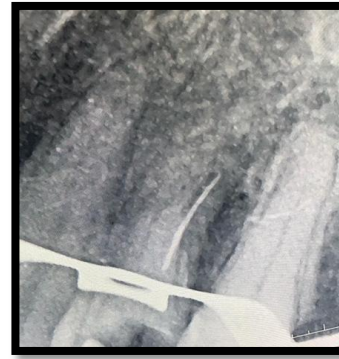
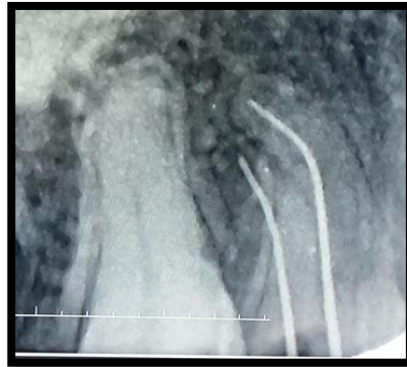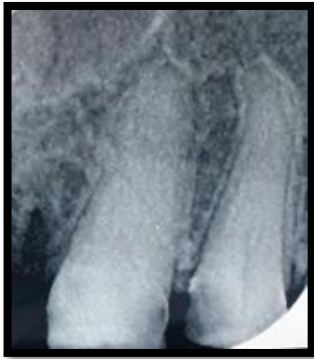Upper right 1



Phase III :

RCT

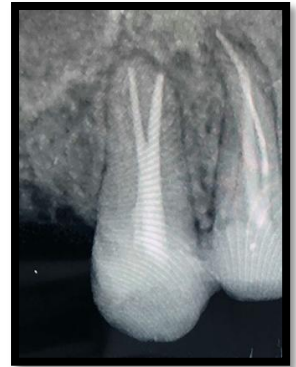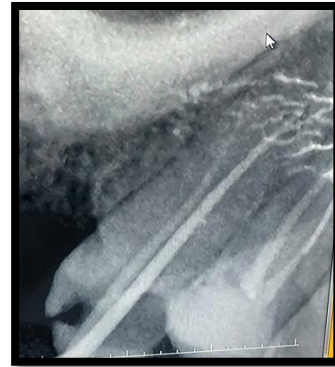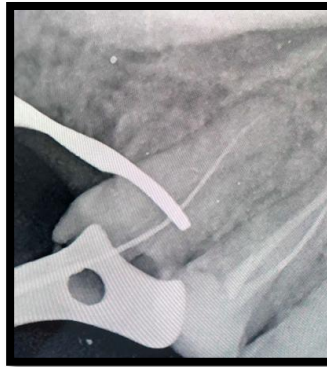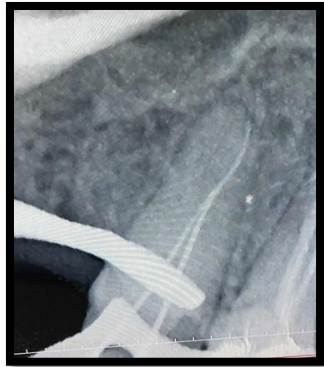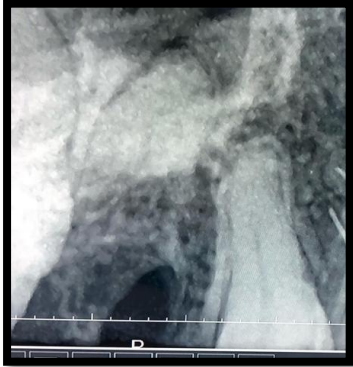
Upper right 4



Phase III :

RCT

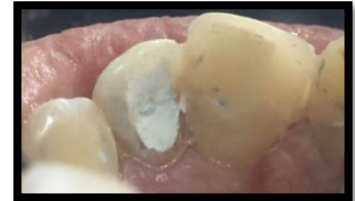
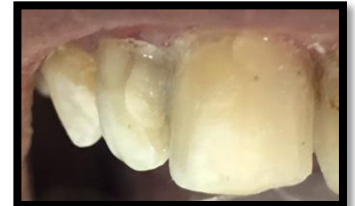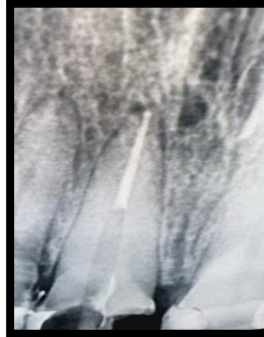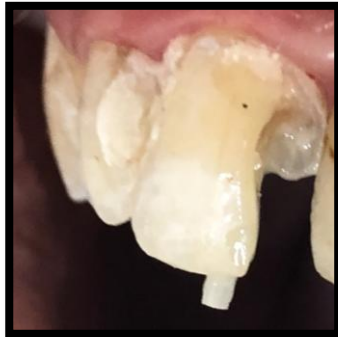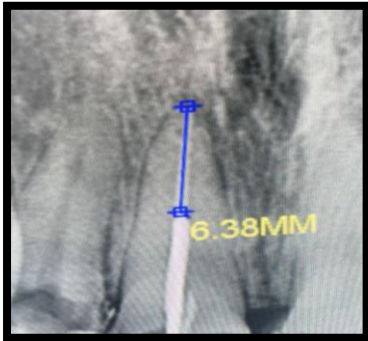Upper right 5



Phase III :

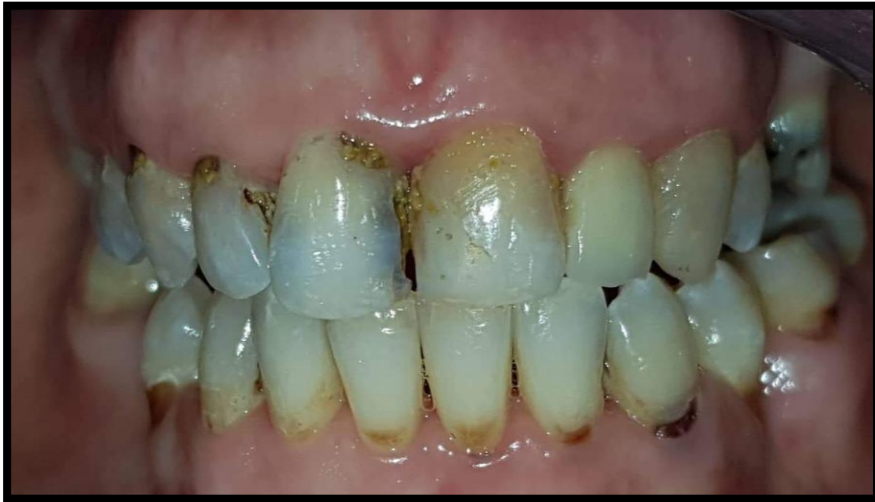Post and core buildup

Upper right 1

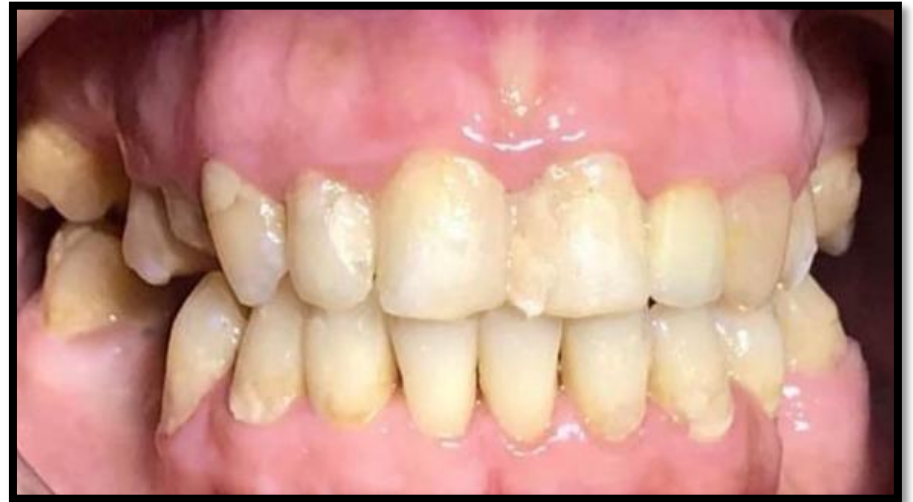



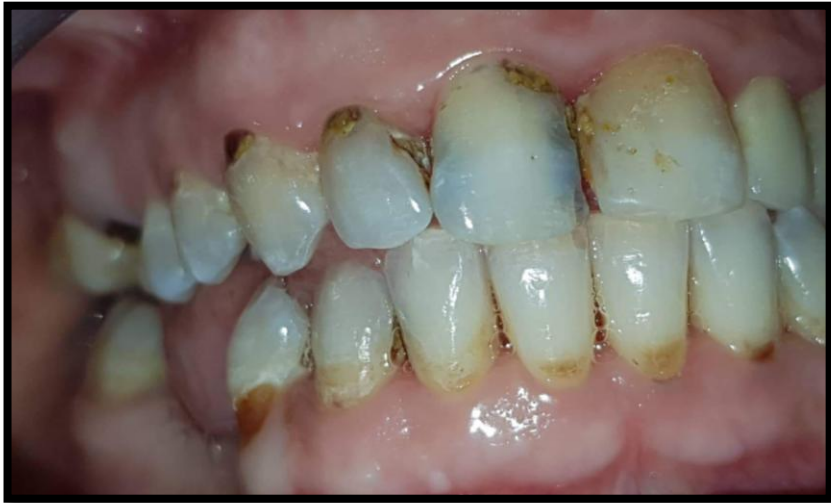Before



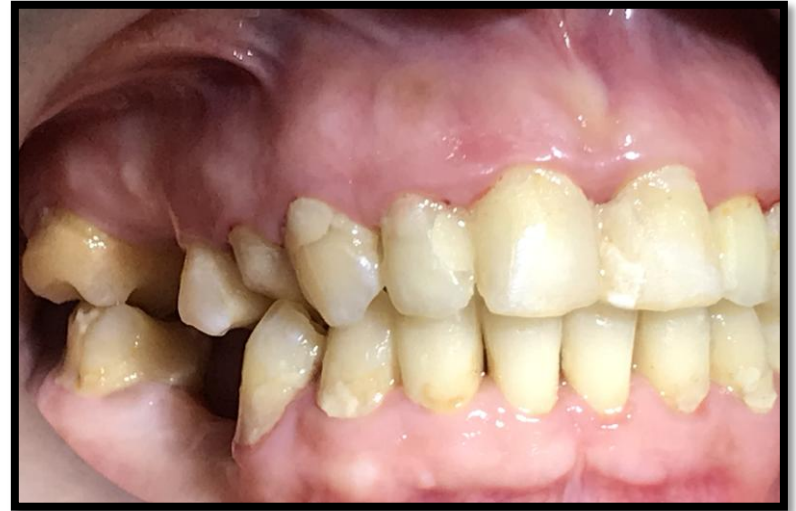After



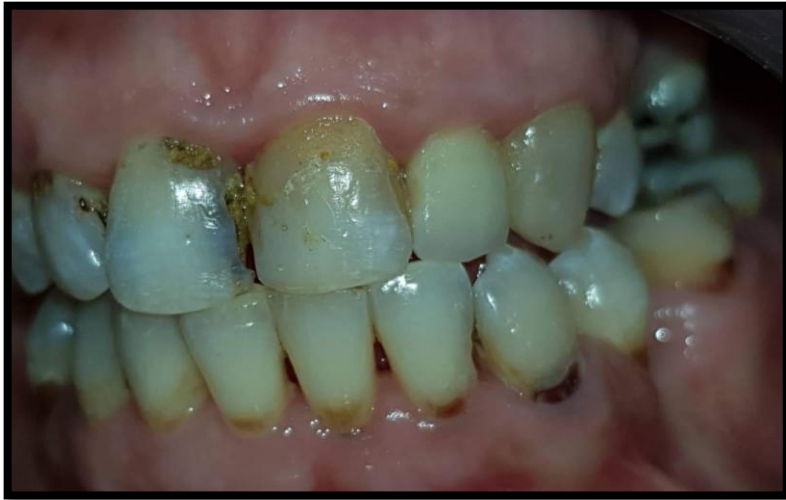Before



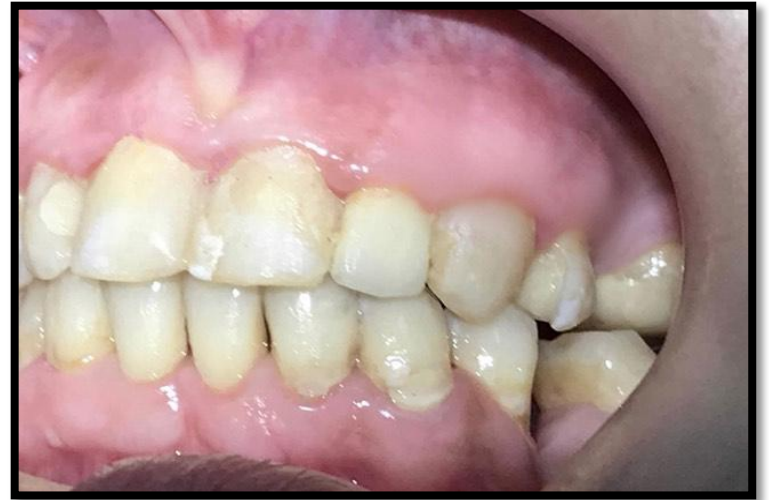After



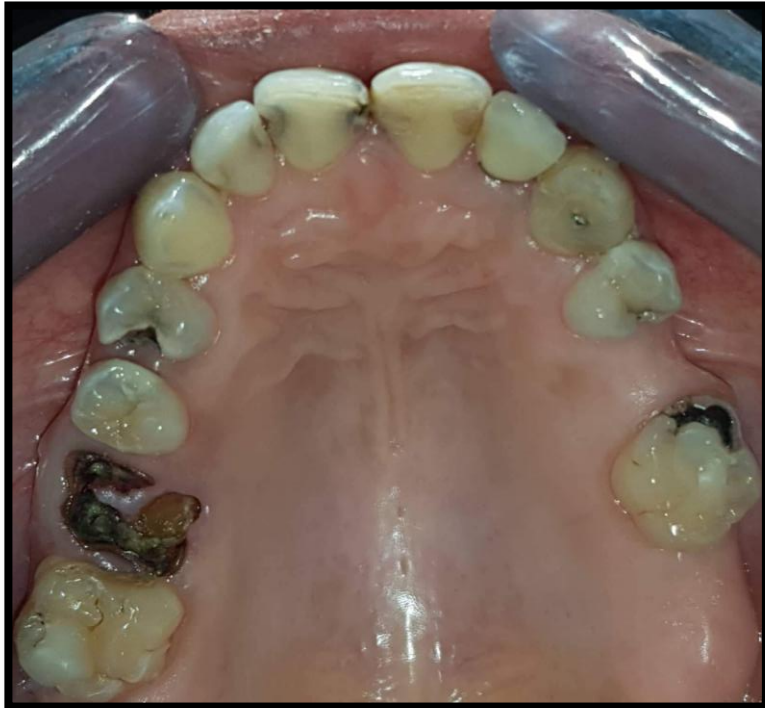Before



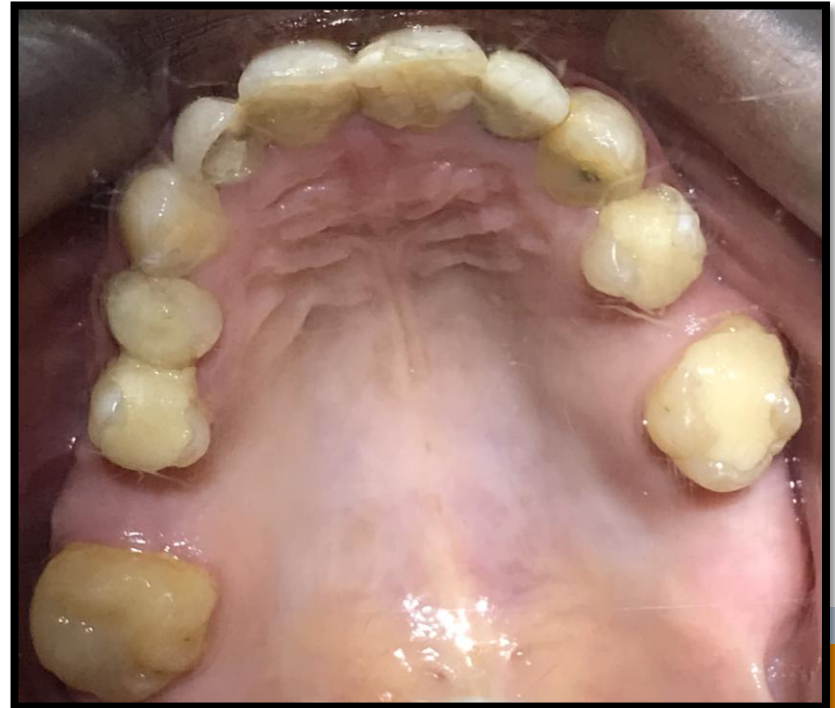
After



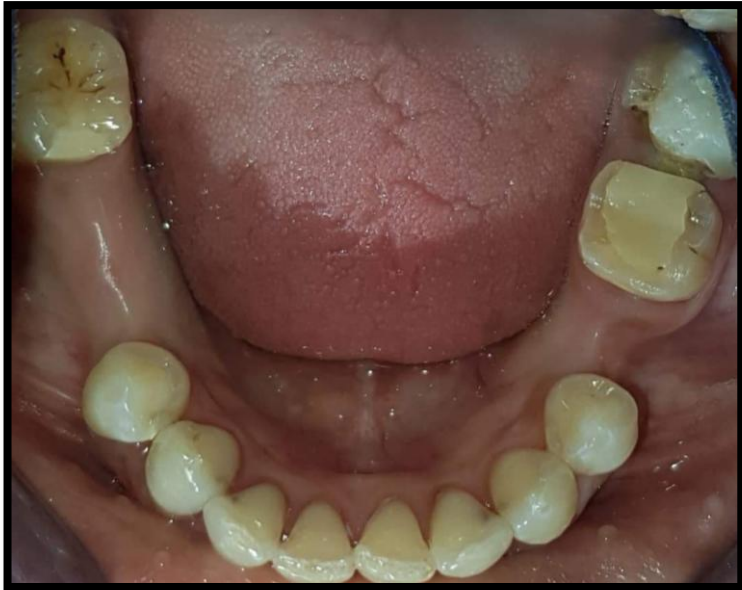Before



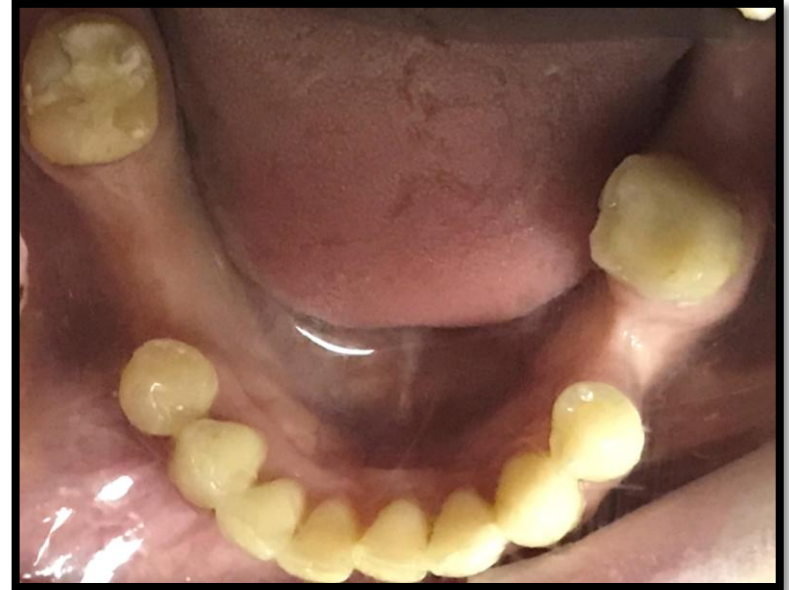After



Before



After



“

*Thank You
For Your Attention*