

Appendicitis.

Group A1 surgery.
1118

1) what differential diagnosis:-

- 1- perforated peptic ulcer.
- 2- acute cholecystitis.
- 3- ulcerative colitis.
- 4- enterocolitis.
- 5- pyelonephritis.
- 6- mesenteric adenitis.
- 7 - pancreatitis.

2) work up: Investigations:

- ① pregnancy test.
- ② CBC → WBC $> 10 \times 10^9$ (leukocytosis).
but may normal Do not excluded.
- ③ USS → mass or abscess and to exclude other D/O.
- ④ Labroscopy → diagnostic & therapeutic (labroscopic Appendectomy)
- ⑤ other Investigations to exclude causes.
 - * urine. RFT → pyelonephritis.
 - * amylase - lipase → pancreatitis.
 - * electrolyte.
- ⑥ XRay Abd.

3) what Diagnosis & treatment:

- Murphy traid → pain - fever - vomiting.
- C/F: Pain ^{lower} ~~upper~~ Quadrant - vomiting - constipation - fever.
blumberg sign - rousing sign - psoas sign.
- Rousing sign: palpation lower ~~Rt~~ quadrant & in Rt.
- psoas sign → extended the hip & Abduct with patient in left side.
↓
pain.
- obturator sign. Flex & Internl rotation hip.
- Rebound tenderness.
- Rigid in ^{Rt} ilia fossa.

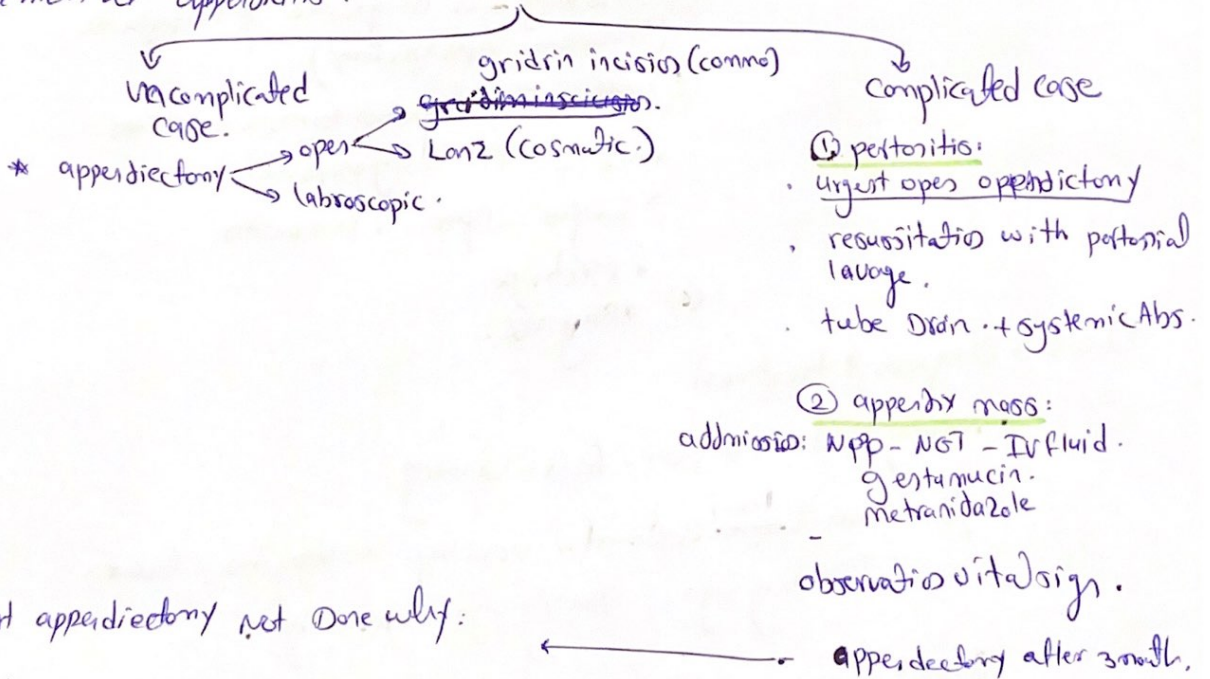
* Alvarado score:

	RLQ pain.	1
	anorexia	1
	N/V	1
signs:	tenderness	2
	Rebound tender	1
	Fever.	1
labs.	↑WBC	2
	Shift to left neutrophil	1
	<u>total.</u>	<u>10</u>

Interpretation:-

- Score < 4 → strongly DX appendicitis
- Score 5-6 → possible acute appendicitis
- Score > 7 → probable acute appendicitis.

* treatment of appendicitis:



urgent appendectomy not done why:

- ① the mass represent body stores to isolated danger.
- ② Difficult appendectomy & morbidity.
- ③ Risk for intestinal injury.

③ appendix abscess.

Incision & Drain by open surgery - oraisguiding.
↓
appendectomy later 3-6 months.

* Surgical approach:

- Transverse incision to meibumy point is indicated when the Dx. is clear. p grid iron. incision.
- lower midline incision → Better Diagnosis not clear.
- large incision → cosmetic.
- Rt lower paramedial.
- flower weir incision.
- Rutherford morrison incision.